

Complications of VEPTR instrumentation for progressive spine deformities in young children without rib fusion. A review of 30 cases

N. Ventura Phd, A.Ey M.D, I.Vilalta M.D.

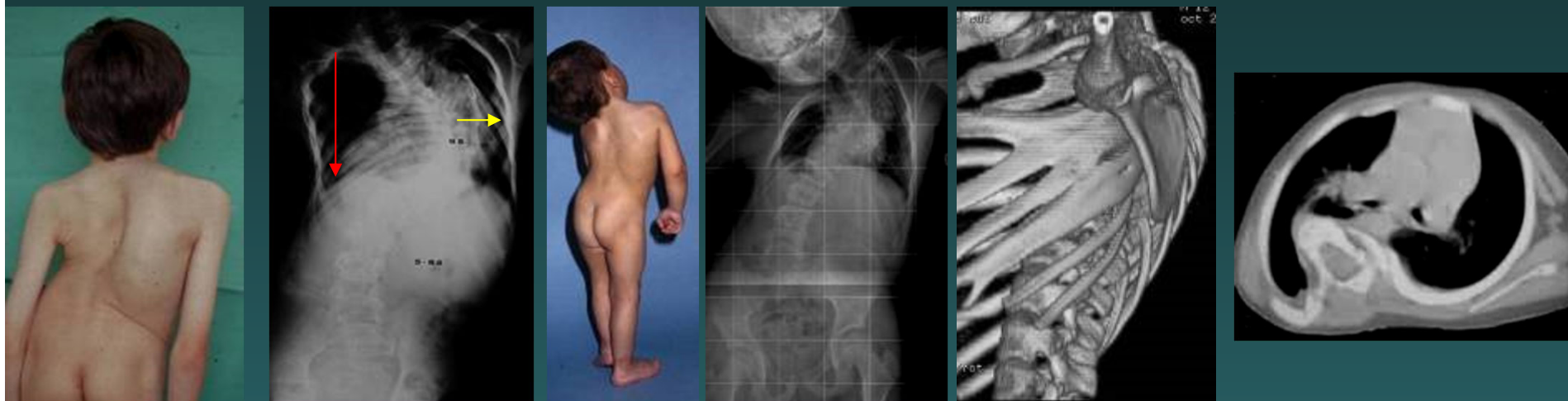
Hospital Sant Joan de Déu (Barcelona)
Spine surgery departement



INTRODUCTION

ICEOS 2011

Lung growth cannot proceed normally in a constrictive chest



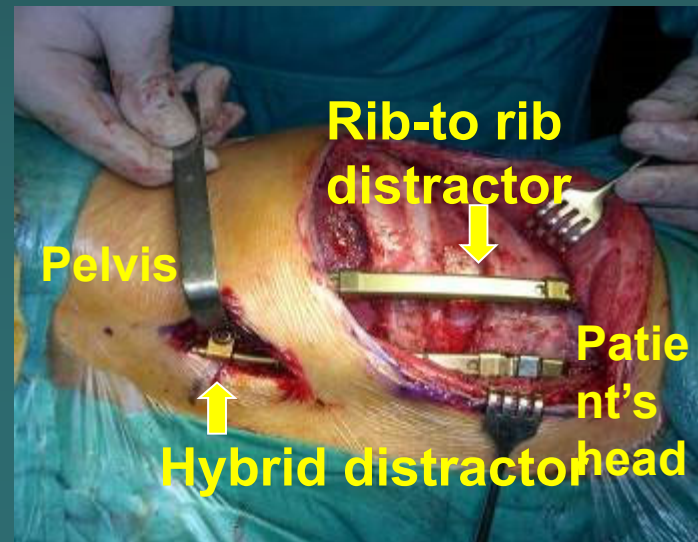
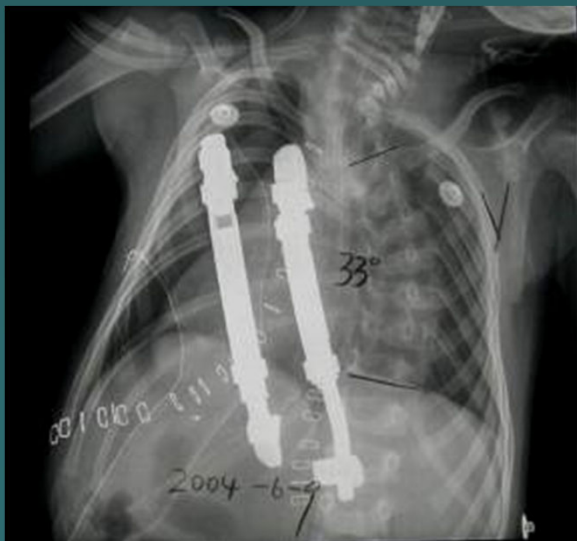
These patients may develop “thoracic insufficiency syndrome”

Fusion performed at an early age will result in a short spine

A short spine could lead a restrictive pulmonary capacity and shortened life span

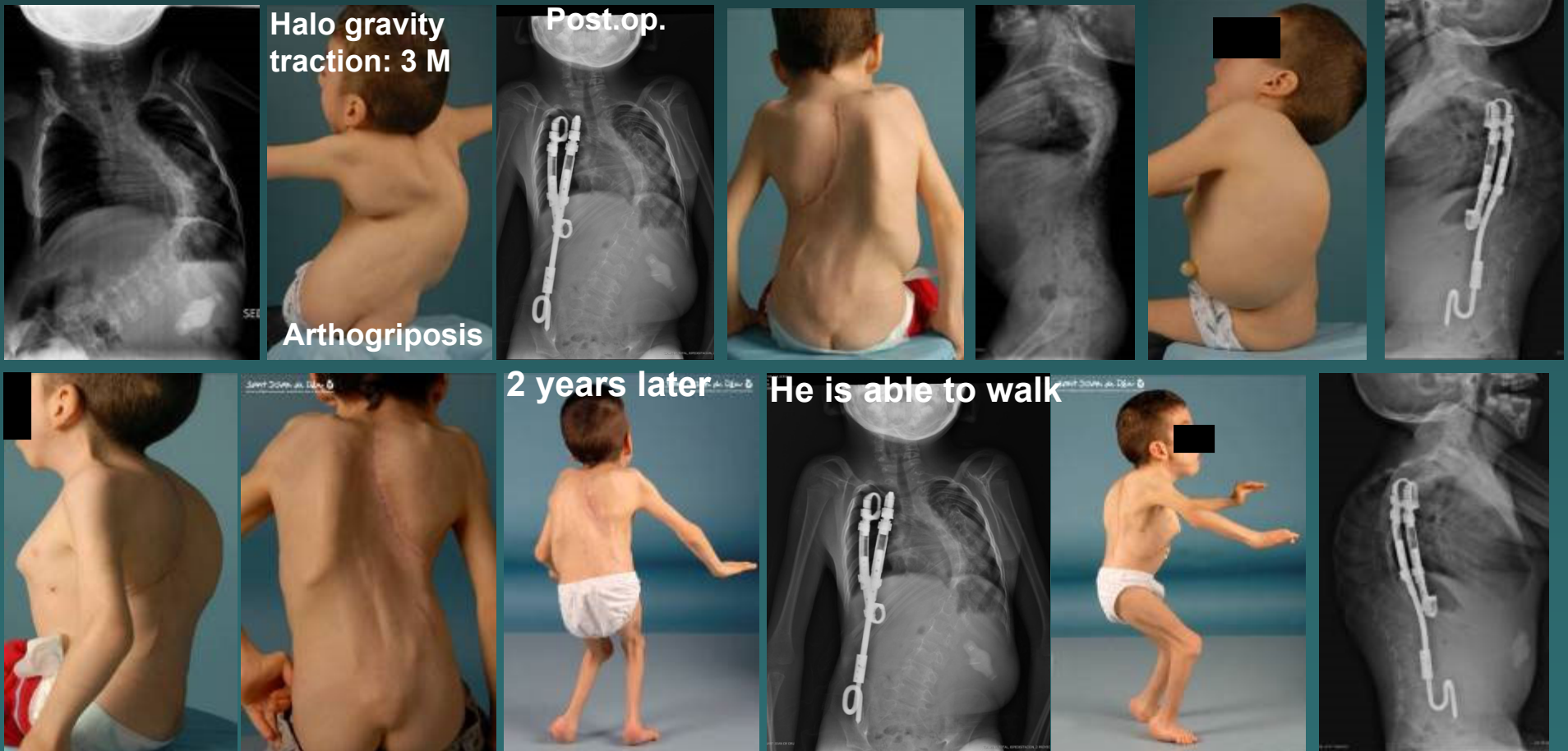
INTRODUCTION

- The goals of surgery in young children : correct the deformity, obtain optimal thoracic volume and **respect the growth of the spine**
- **VEPTR:Expansion thoracoplast:** lengthening the constricted hemithorax through an opening wedge thoracostomy



Material and Methods

Retrospective clinical and radiographic study of 30 patients affected of E.O.S. without rib fusion treated with VEPTR between June 2004 and April 2009

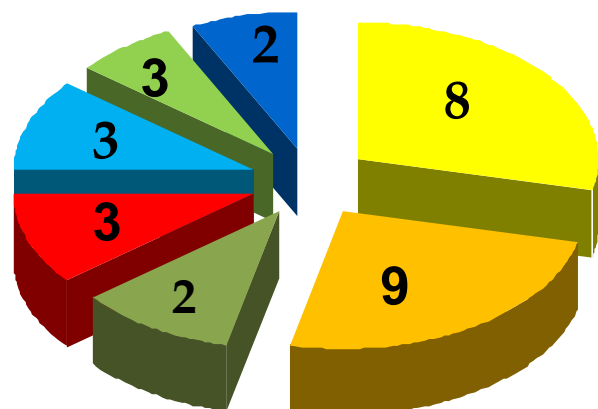


RESULTS

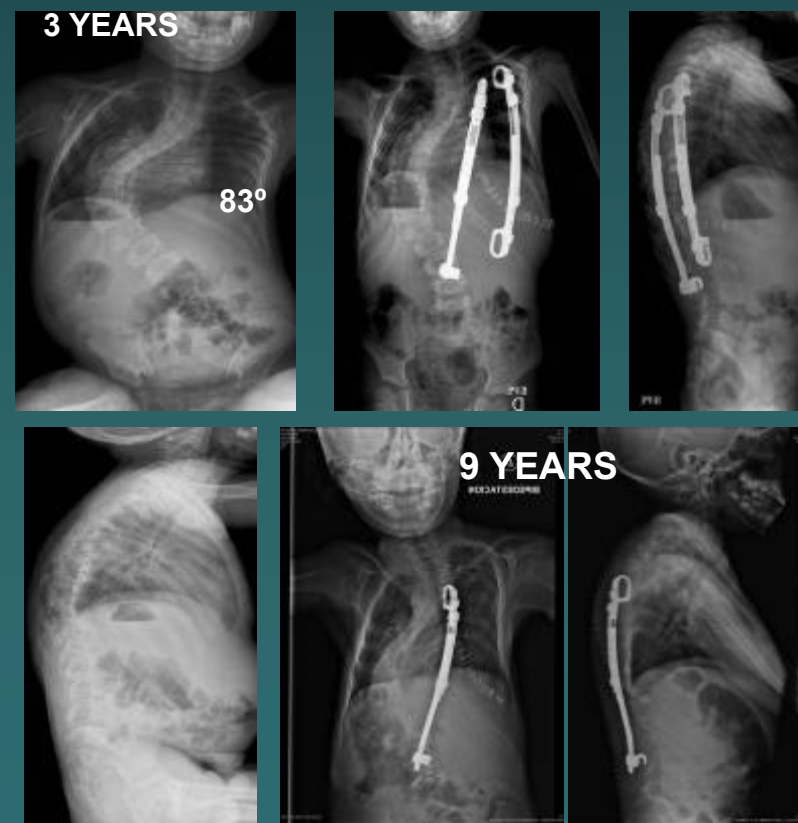Etiology :

9 cases neuromuscular, 8 cases congenital, 3 cases I.I.S., 3 cases arthrogriphosis, 3 cases osteogenesis imperfecta, 2 cases cord tumors, 2 cases syndromic scoliosis

Osteogenesis imperfecta

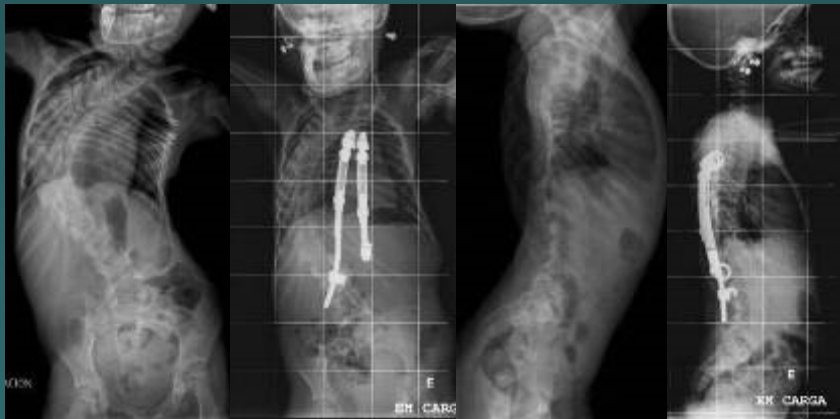

- congenital malformation
- infantile idiopathic scoliosis
- arthrogriphosis
- syndromic
- neuromuscular
- o. imperfecta
- cord tumors

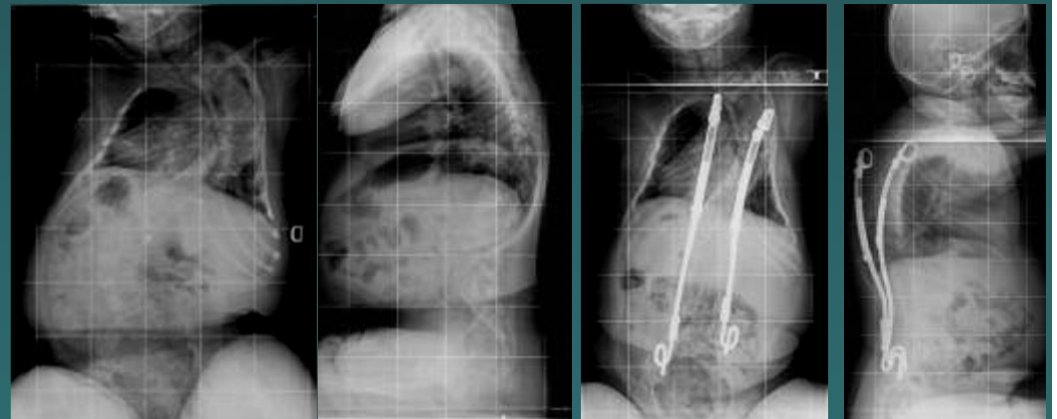


RESULTS

- 30 patients ♂ 13 ♀ 17
- Follow up from 2 years to 6 years
- Age at surgery 2.8 -12 years (6.7 years)
- Five cases halo/ chair before operation
- Preoperative curve degree 50°/114° (78°)
- Postoperative curve degree 37°-79° (55°)



**Congenital scoliosis
without fuse ribs**

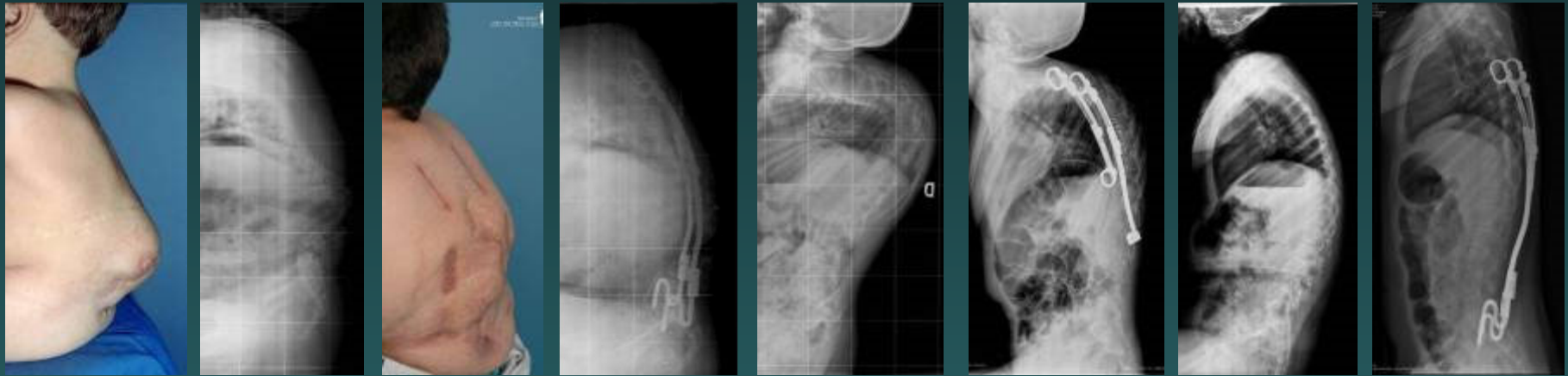


**S.M.A. type II. VEPTR from
pelvis to upper ribs**

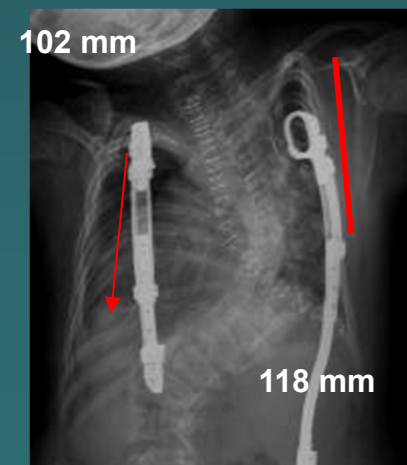
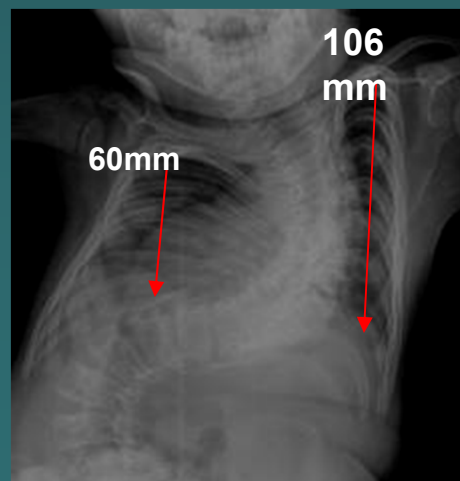
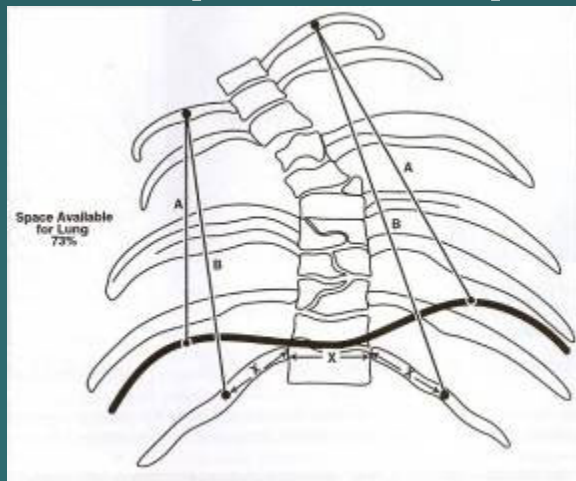
RESULTS

ICEOS 2011

- 9 patients had a preoperative kyphosis 70° - 100° (66°)
Postoperative kyphosis 31° - 73° (42°)



- Preoperative space available for the lung 57% - 97% (54%)
Postoperative space available for the lung 0% - 63% (22%)

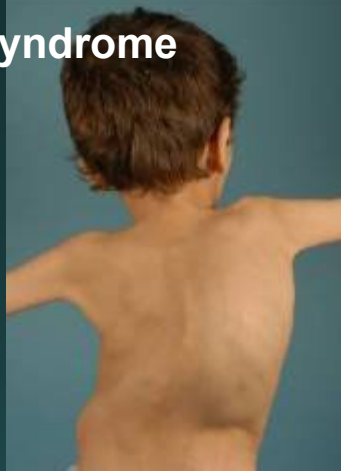
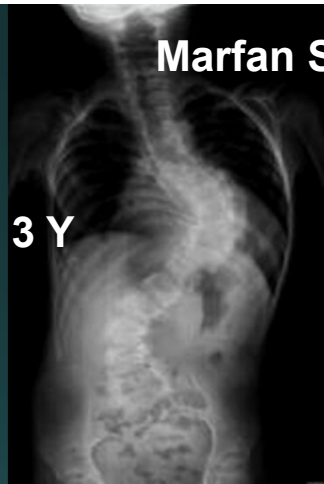
COMPLICATIONS

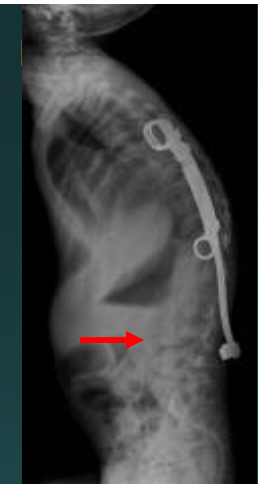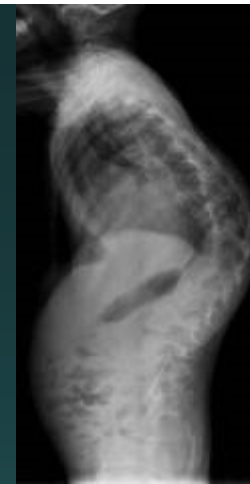
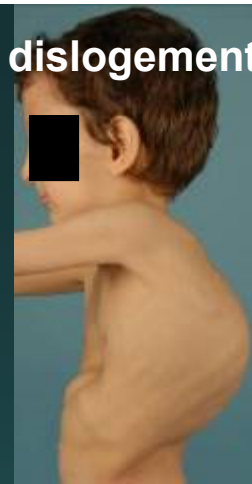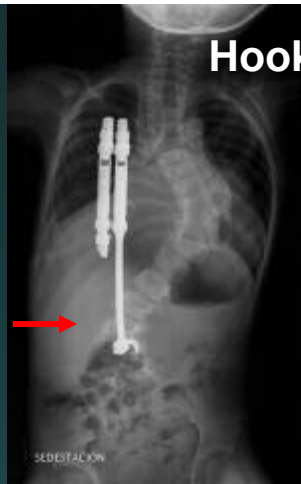
- **Major complications:** 5 patients (16.66%)
 - 1 Patient died six months after surgery (cardio-respiratory arrest)
 - 4 Cases developed skin sloughs, all required implant removal (two of these cases were treated with growing rods six months later)
- **Minor complications:** 5 patients (16.66 %)
 - 1 Acute infection distal anchorage requiring debridement + ATB
 - 1 Distal junctional kyphosis (requiring distal pedicle screws)
 - 2 Rod breakages
 - 1 Distal hook dislodgement (revision surgery)
 - 1 Iliac hook pelvic migration without clinical consequences

Marfan Syndrome

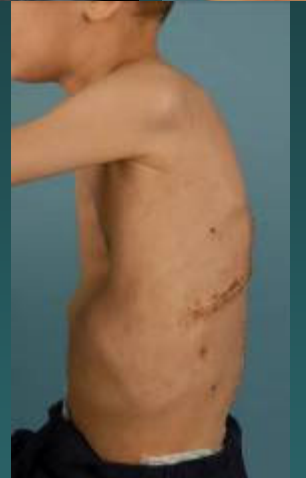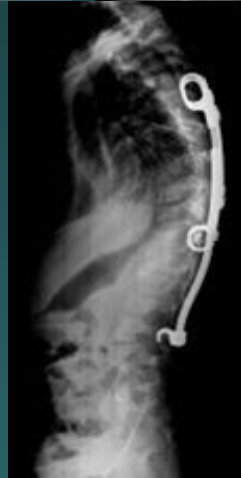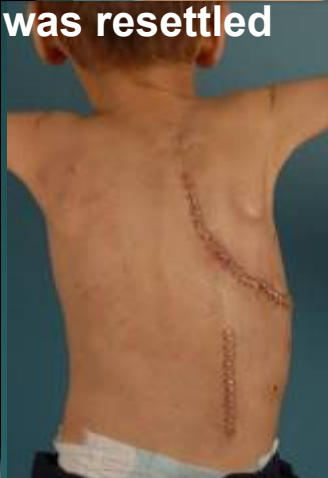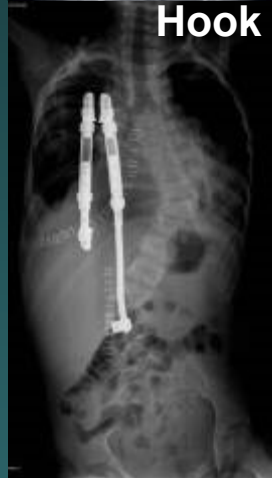3 Y



Hook dislodgement

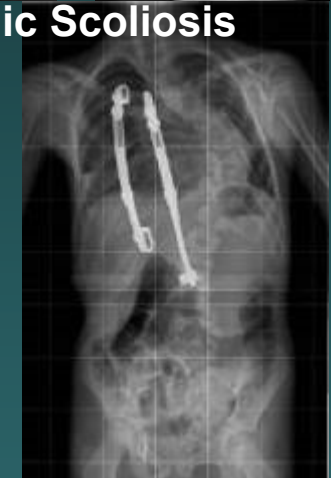
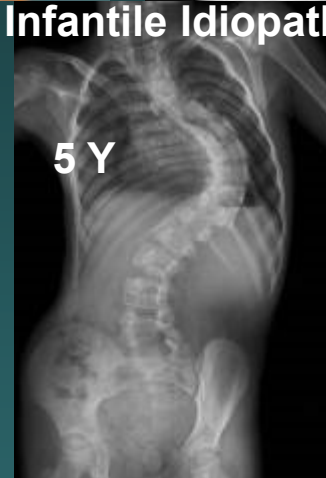
Hook was resettled

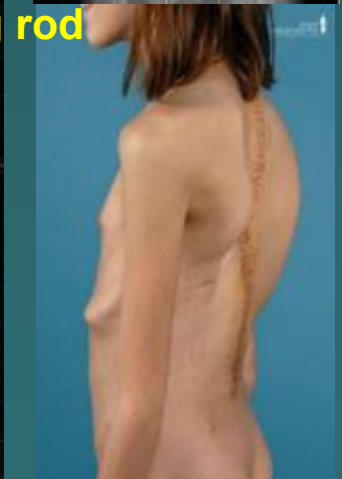
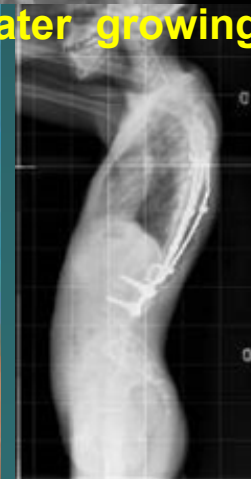
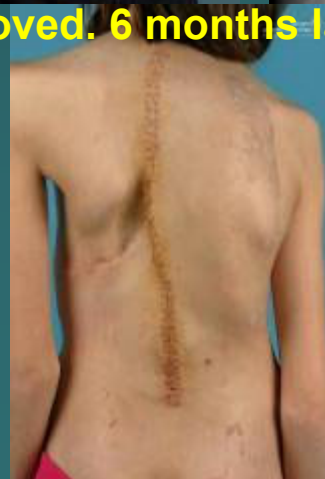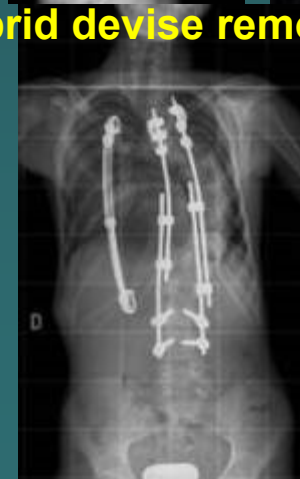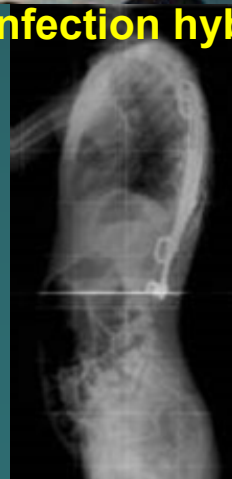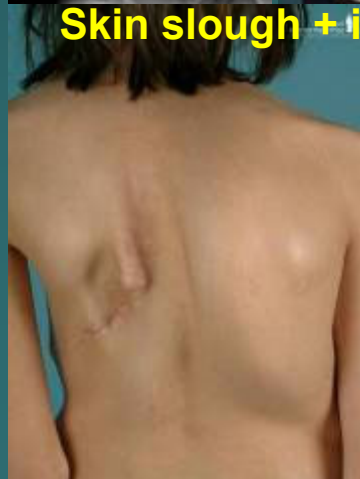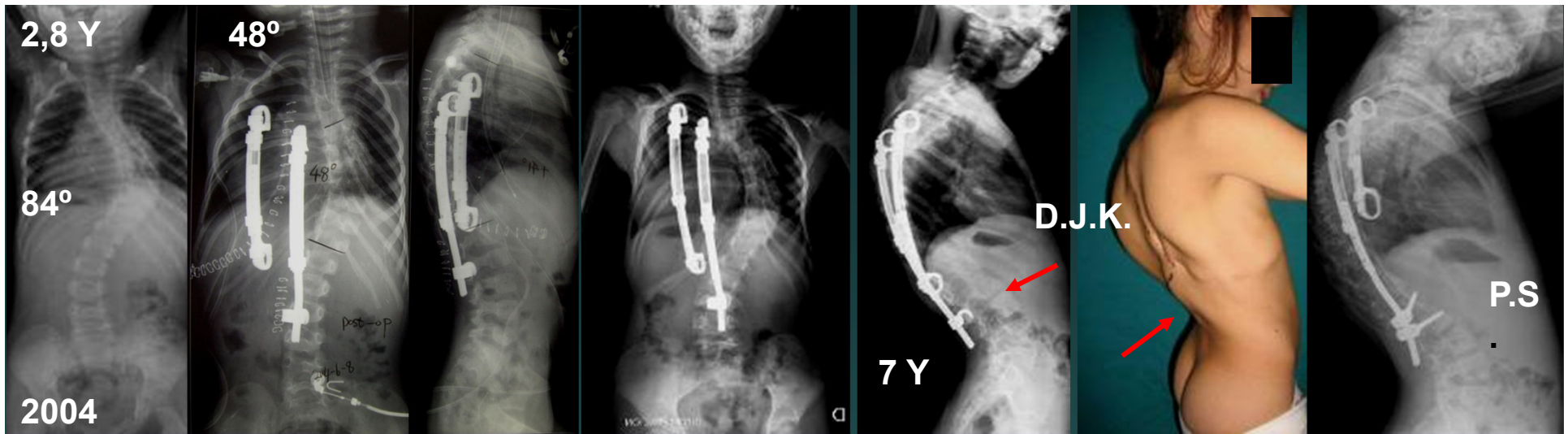
Infantile Idiopathic Scoliosis

5 Y

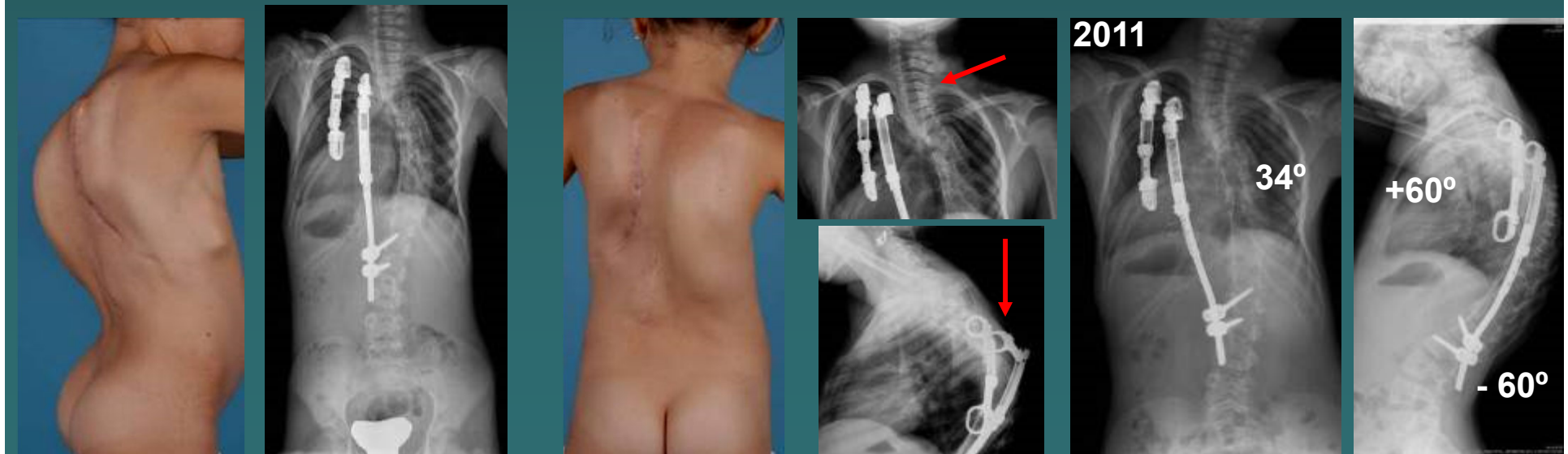

Skin slough + infection hybrid device removed. 6 months later growing rod



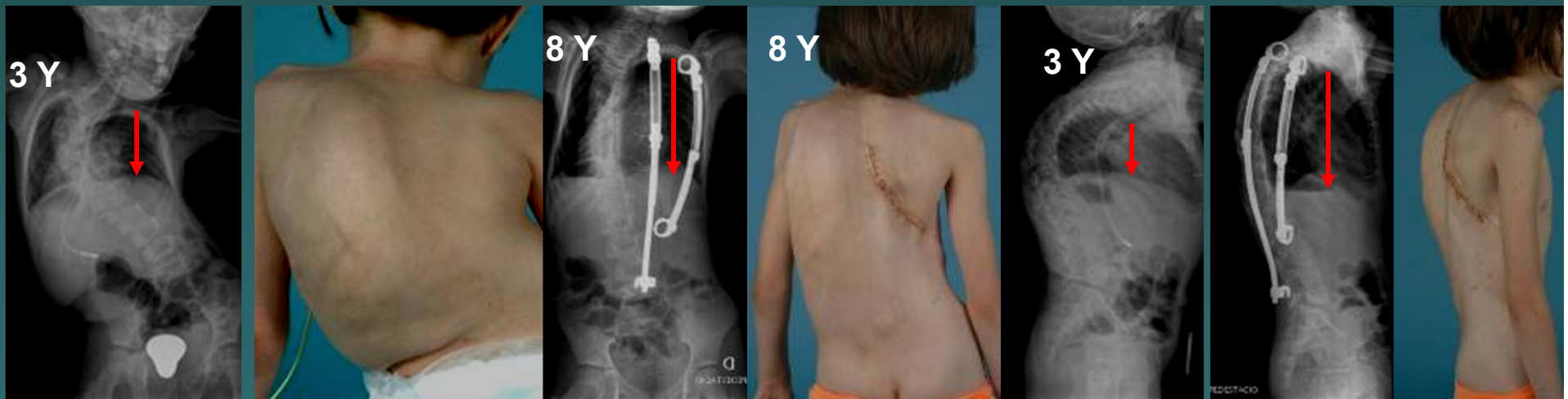

COMPLICATIONS. Infant. Idiop. Scol. 2,8 years old, 84°. 4 years later distal junctional kyphosis. VEPTR was changed with 2 distal P.S. to correct. One year later “broken cradle rod”. The hybrid devise is changed.



CONCLUSIONS

- Even the complication rate was high (17 % of major and 17% of minor complications), when chest deformity is severe and in very young children, VEPTR represent an alternative to growing rods for early onset scoliosis



Infantile Idiopathic Scoliosis + cardiopathy. VEPTR