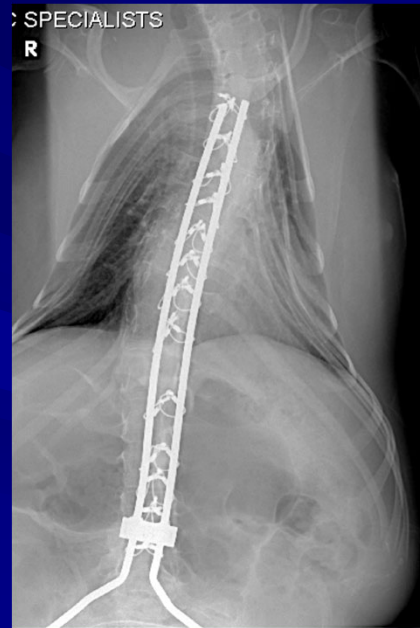

Growing Segmental Spinal Instrumentation Without Fusion in Spinal Muscular Atrophy

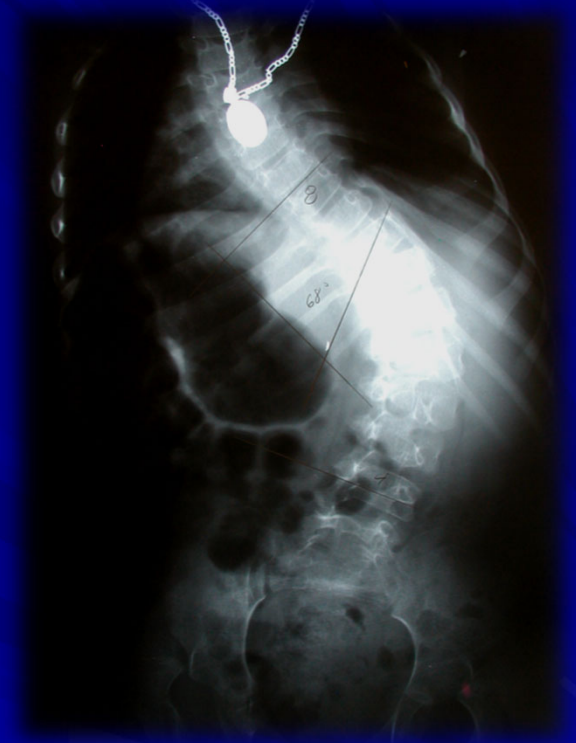

Samuel R. Rosenfeld, MD
CHOC Childrens Hospital

ICEOS
November 15-16, 2012

Background

- ❖ Spinal deformity is commonly associated with SMA.
 - neuromuscular type in which the pelvic obliquity is proportional to the severity of the curve
 - early onset
 - progresses rapidly prior to the onset of puberty
- ❖ Respiratory impairment is common in SMA.
 - restrictive lung disease advances simultaneously with the progression of the spinal curvature.



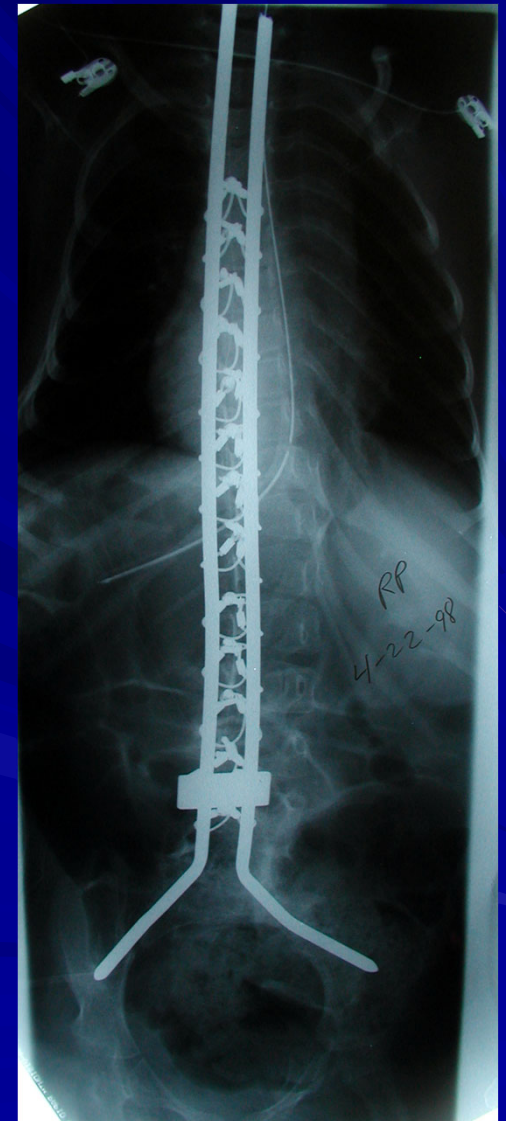
Purpose

To report the long term follow up of a series of patients with spinal muscular atrophy whose neuromuscular scoliosis was treated surgically by growing posterior segmental spinal instrumentation without fusion with only ONE surgical intervention

- ❖ Nine patients with Spinal Muscular Atrophy underwent segmental spinal instrumentation without fusion. There were three boys and six girls. Three patients had SMA-1 and six patients had SMA-2. The average age at surgery was 6 years, 11 months. On average, 15 spinal segments were instrumented and fixation was carried out to the pelvis. No post-operative spinal orthosis was utilized. Radiographs were evaluated for correction of deformity, spinal growth, and evidence of hardware failure.

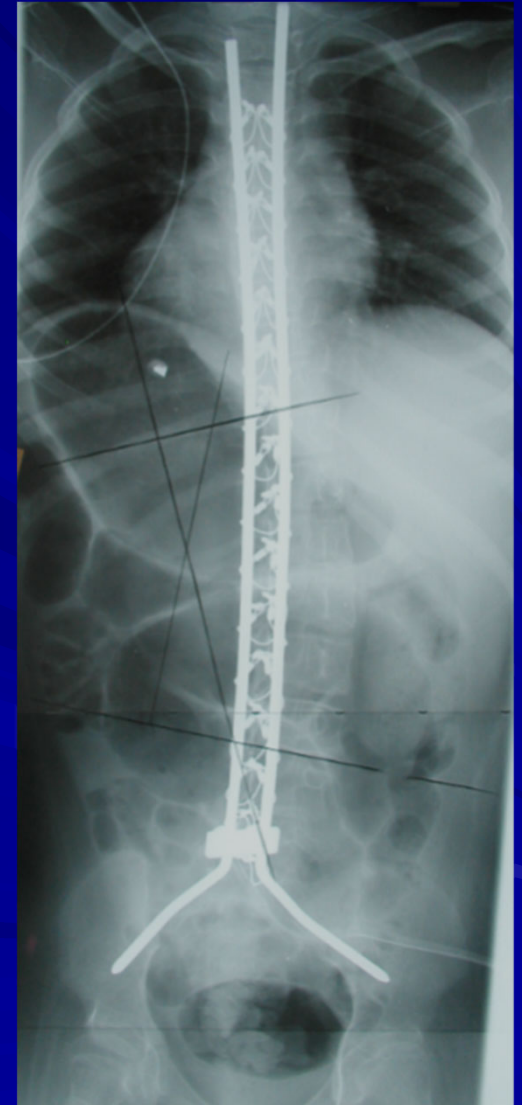Surgical Technique

- ❖ A standard posterior approach
- ❖ Subperiosteal dissection of the lamina was carried laterally to the facet joints which were preserved.
- ❖ Sublaminar cables were passed at each level
- ❖ Two paired stainless steel unit rods were cut and contoured for maximal curve correction, normal sagittal alignment, and secured in the ilium



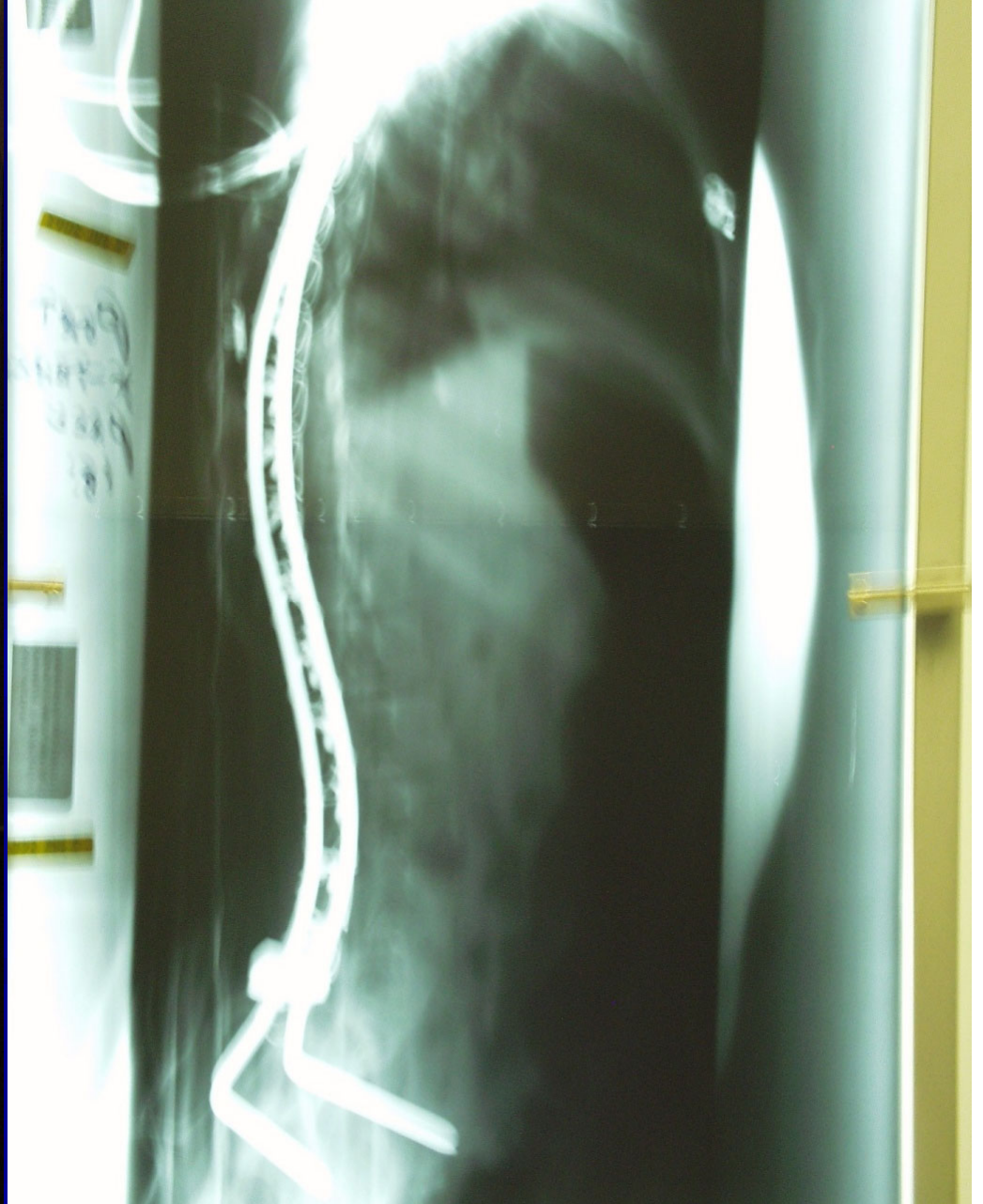
Surgical Technique

- ❖ A crosslink was placed at the caudal end of the construct
- ❖ The cephalad rod ends were left long
 - To Allow spinal growth along the construct, and
 - Obviate the need for further lengthening surgeries
- ❖ Postoperative bracing was not utilized

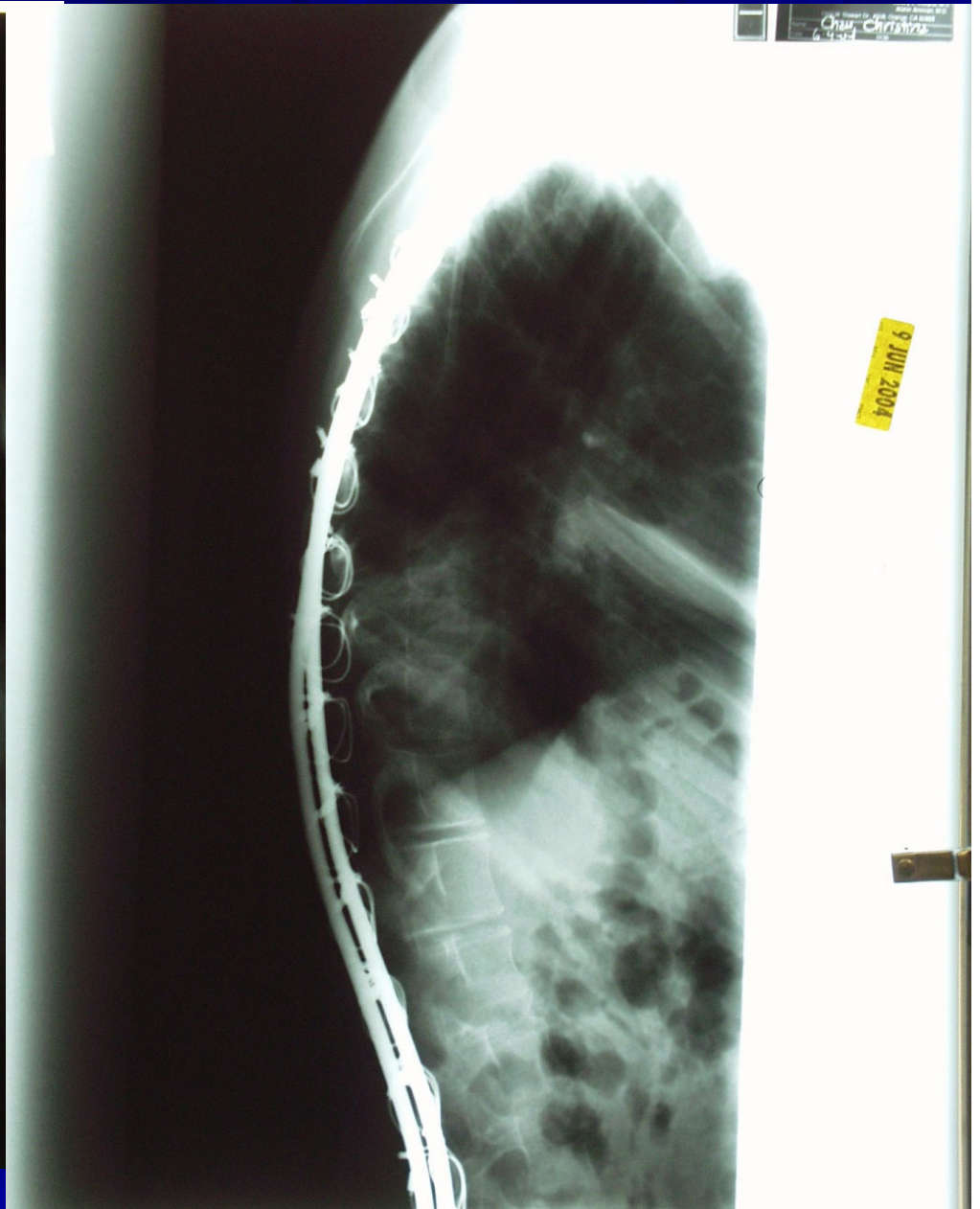
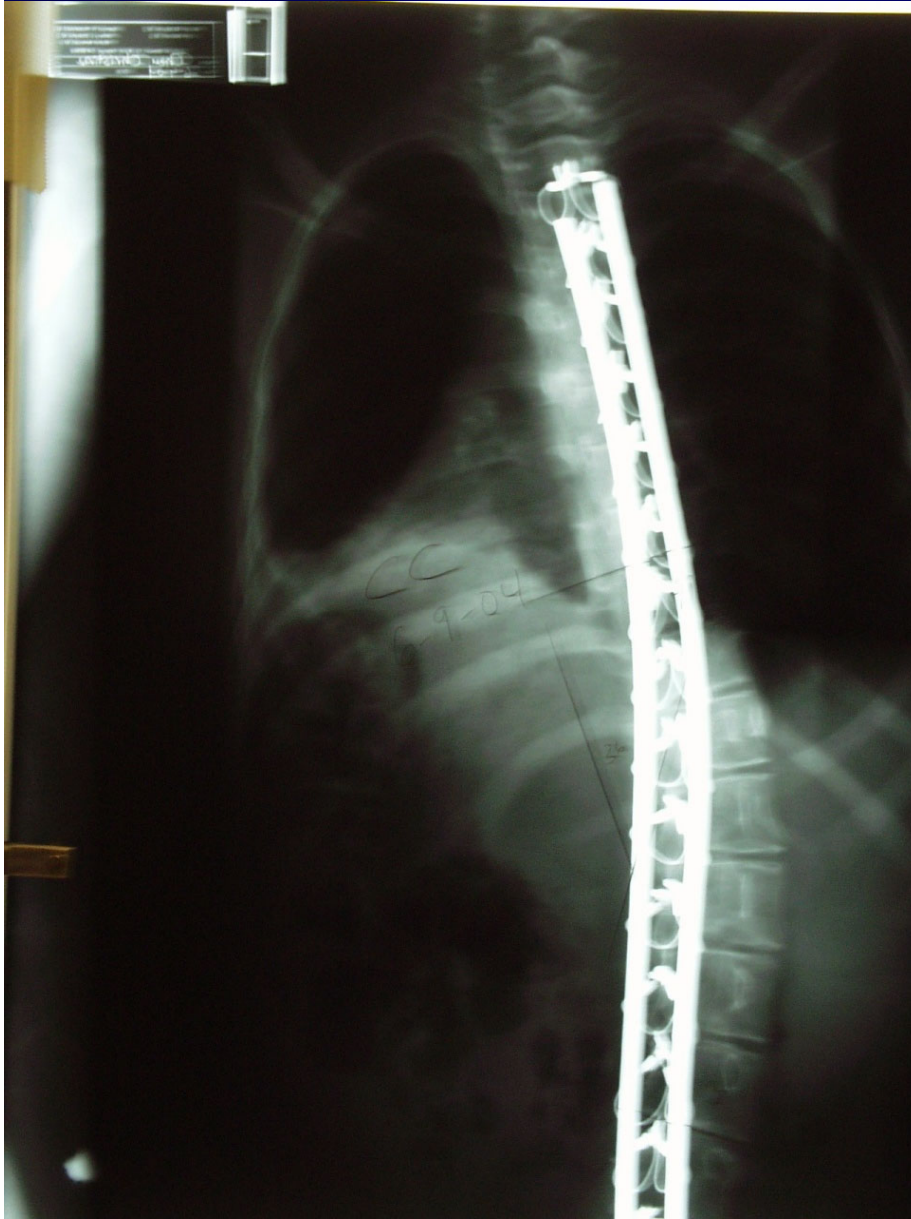


❖ Results: Follow-up averaged 75 months. The mean preoperative scoliosis measured 57 degrees and the mean postoperative scoliosis measured 32 degrees. At the final follow-up, the scoliosis measured 32.4 degrees. Normal sagittal alignment was maintained in all patients. On average, 15 segments were instrumented. Spinal growth from T1 to S1 averaged 3.6 cm. over the study period. There were 2 surgical infections responding to debridement and antibiotics that did not interfere with continued spinal growth. One patient required revision of the pelvic fixation.

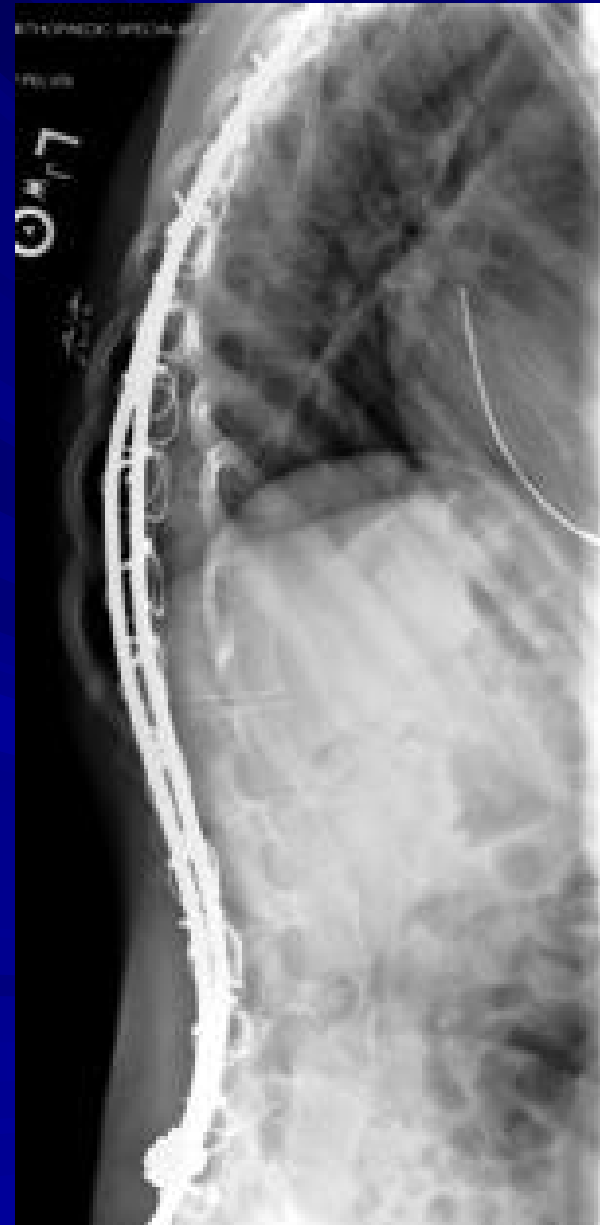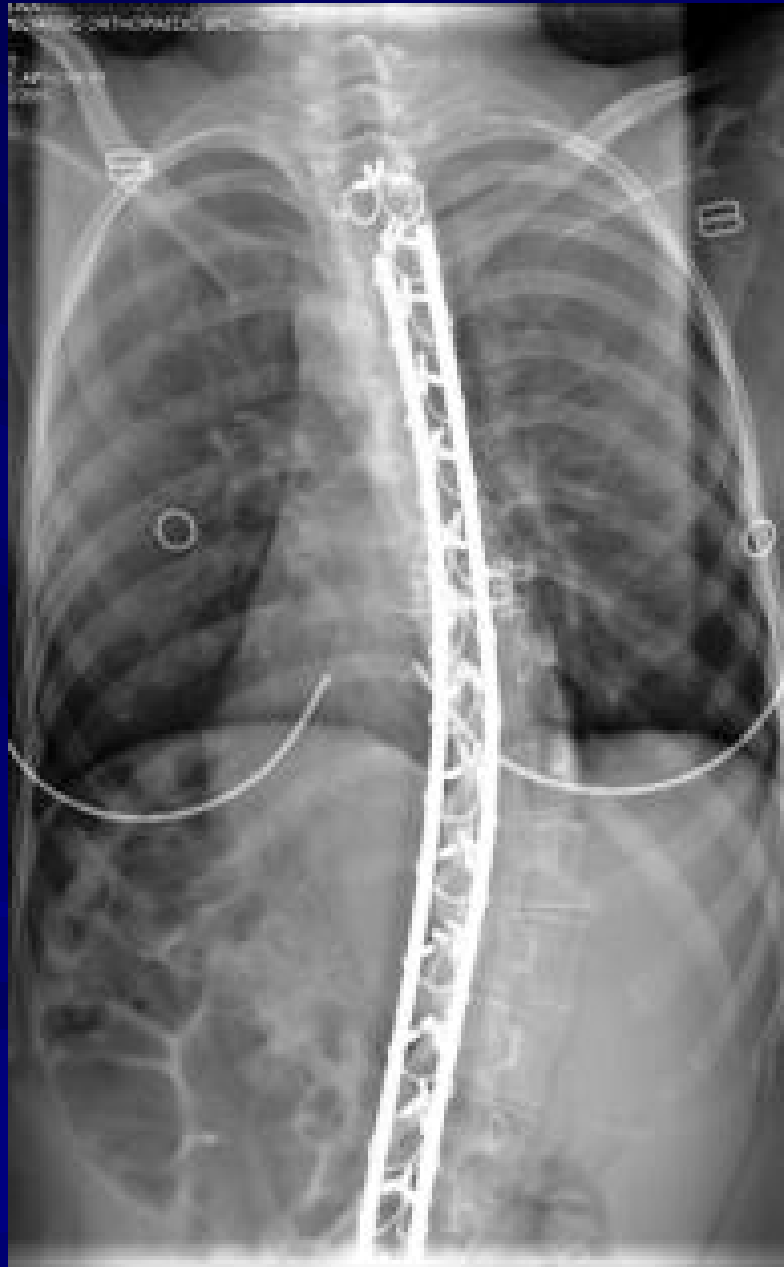Demographics	Age at surgery (months)	Follow-up (months)	Cobb angle pre-op	Cobb angle post-op	PJK	Growth (cm./ yr.)	complications
<input type="checkbox"/> SMA 2	127	124	48°	38°	16°	1.4	none
<input type="checkbox"/> SMA 2	59	175	44°	30°	12°	2.2	none
<input type="checkbox"/> SMA 2	80	123	68°	55°	45°	1.3	none
<input type="checkbox"/> SMA 1	82	116	50°	42°	2°	1.2	Revision pelvic fixation
<input type="checkbox"/> SMA 1	85	92	76°	35°	17°	2.0	none
<input type="checkbox"/> SMA 2	81	12	47°	8°	9°	1.6	none
<input type="checkbox"/> SMA 2	99	8	25°	6°	8°	0.7*	none
<input type="checkbox"/> SMA 2	72	16	33 °	6°	10°	1.4	Deep infection
<input type="checkbox"/> SMA 2	63	19	31°	8°	10°	1.3	Superficial infection



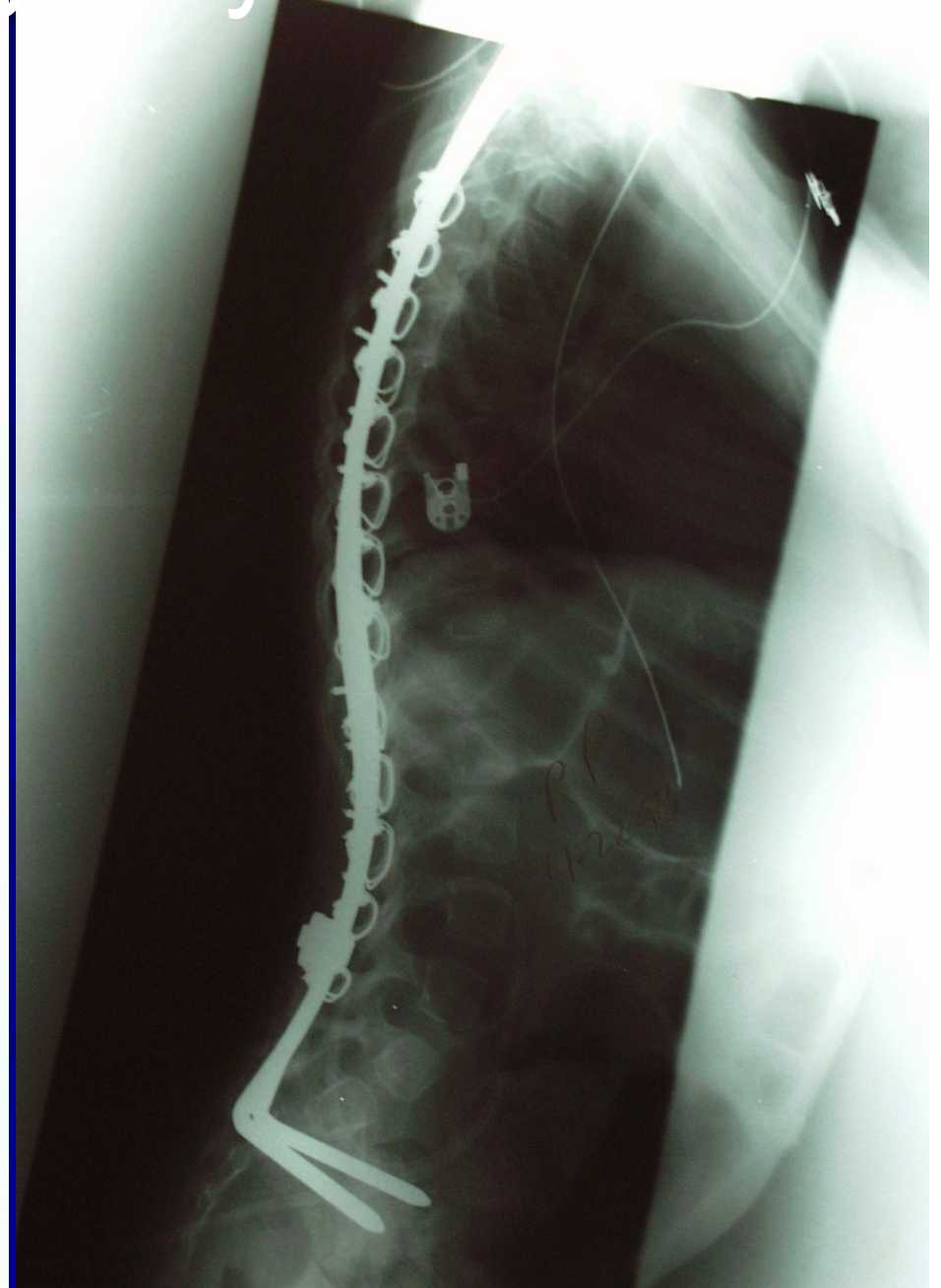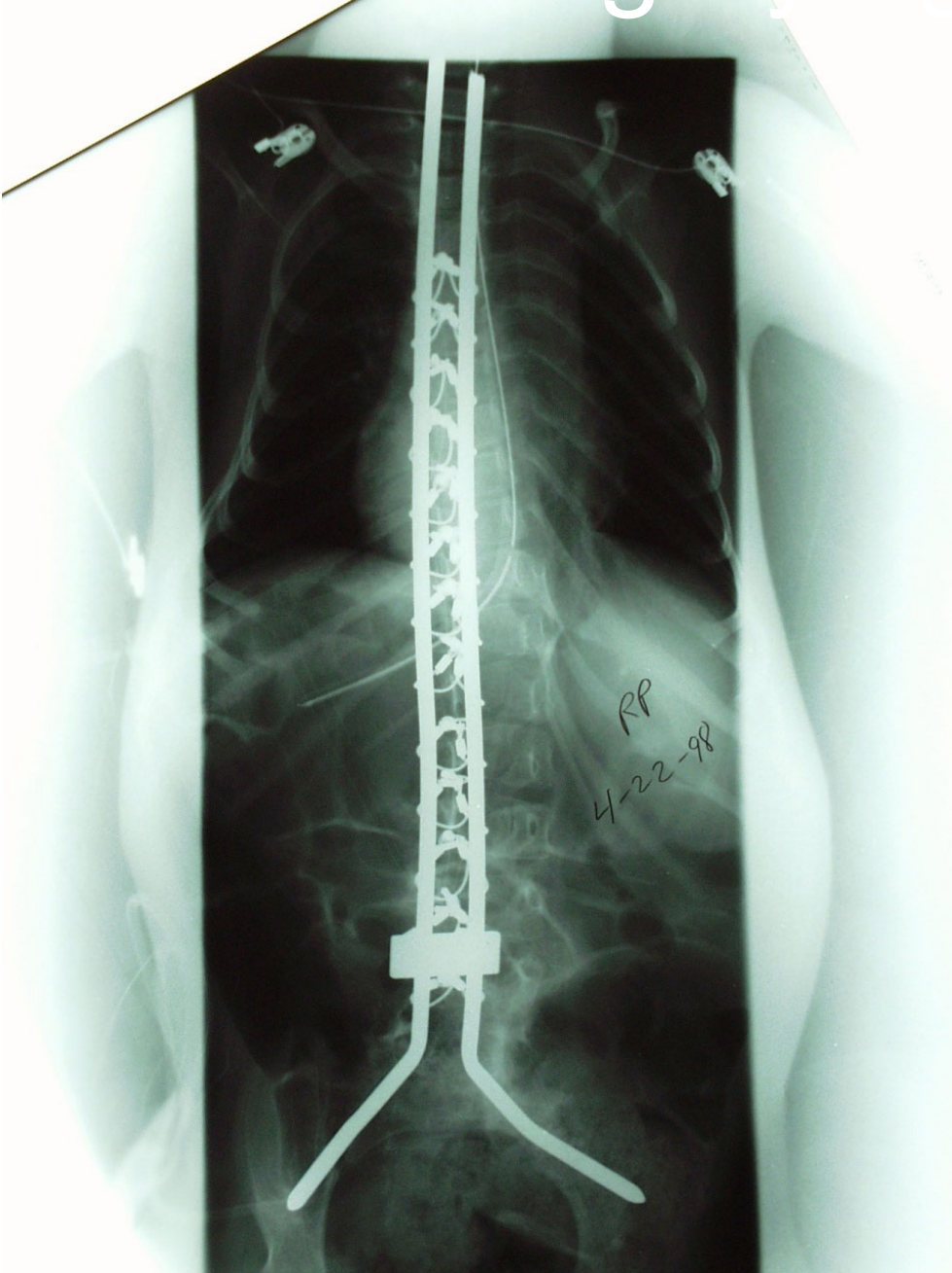
2 years post op



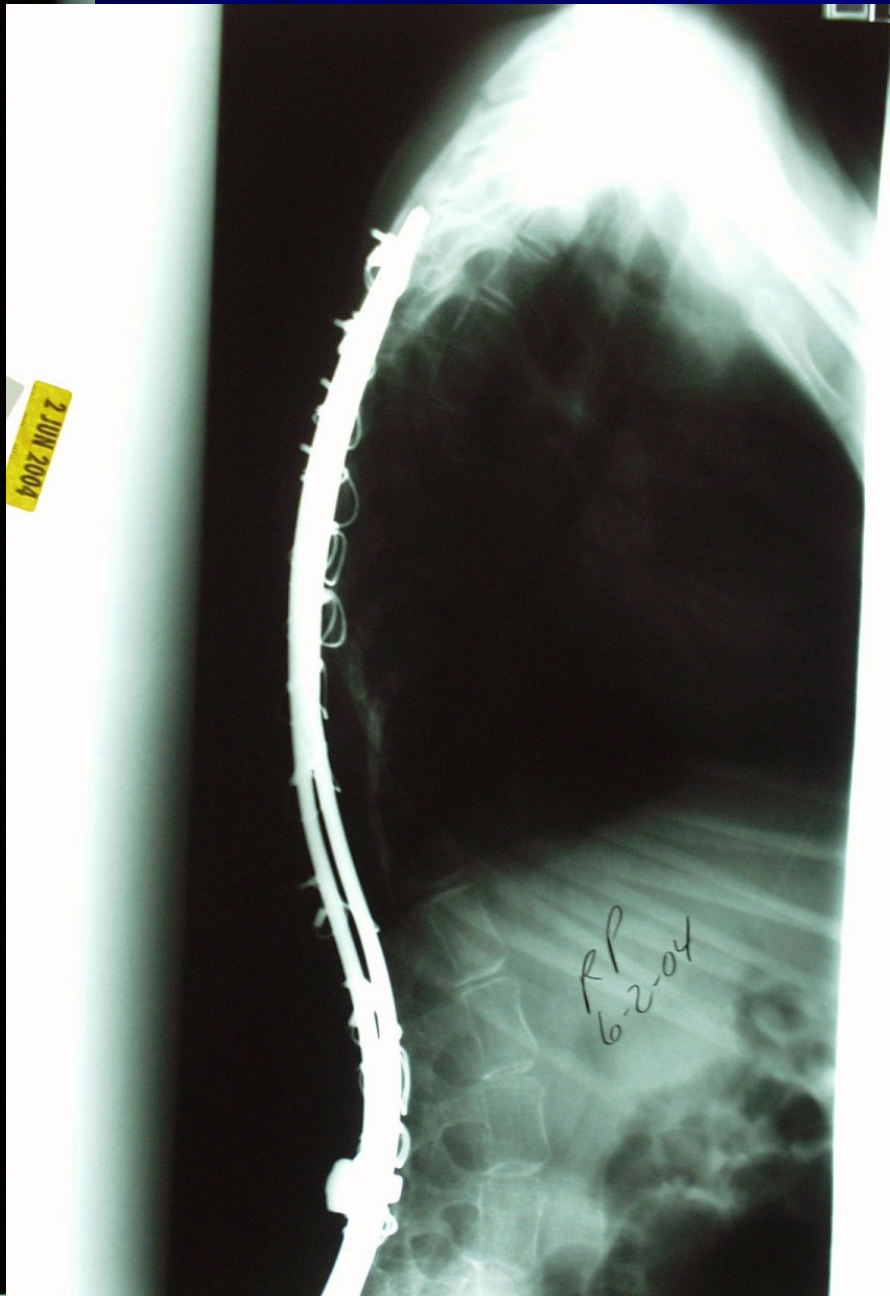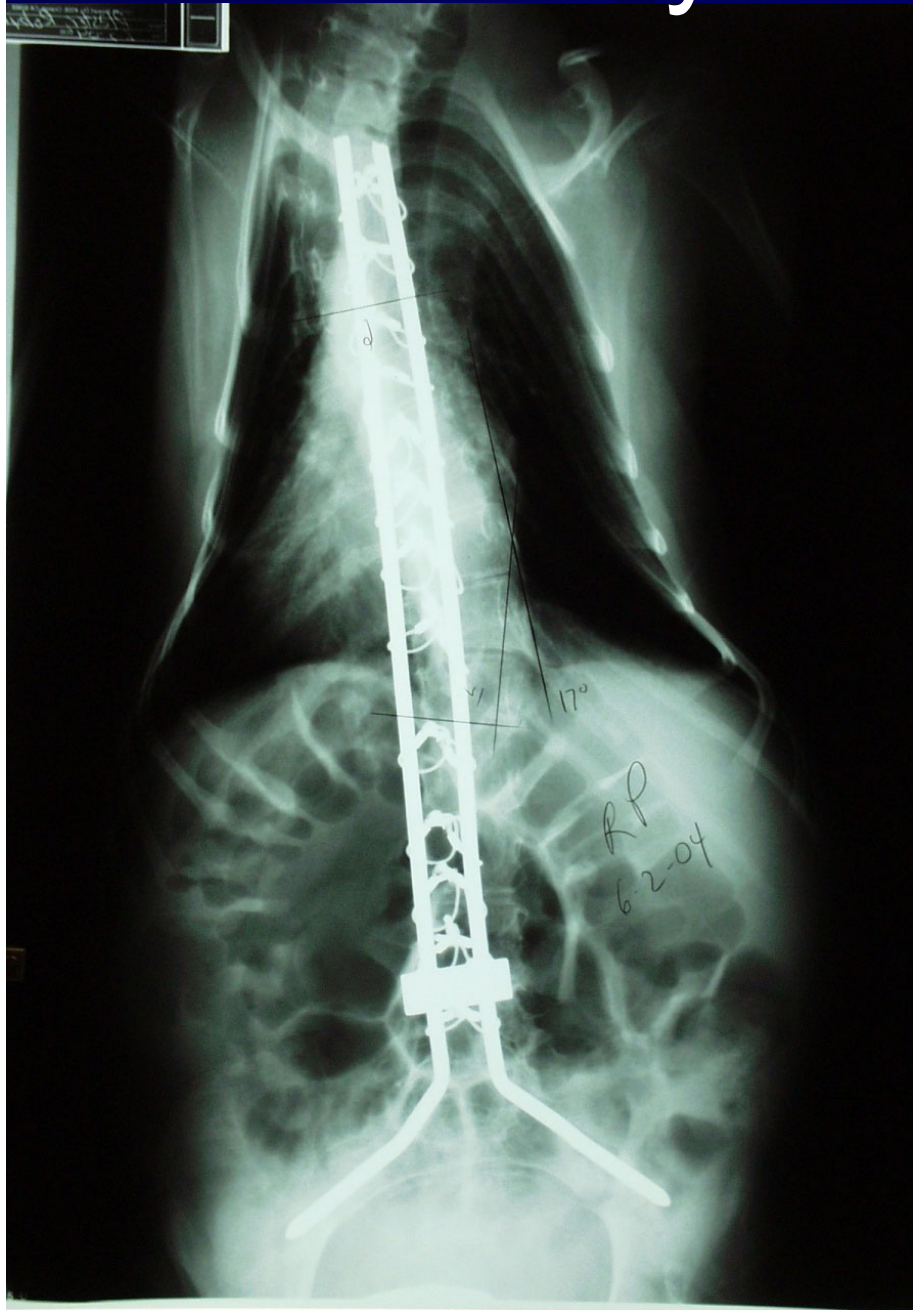9 years post op



Surgery age 4 years



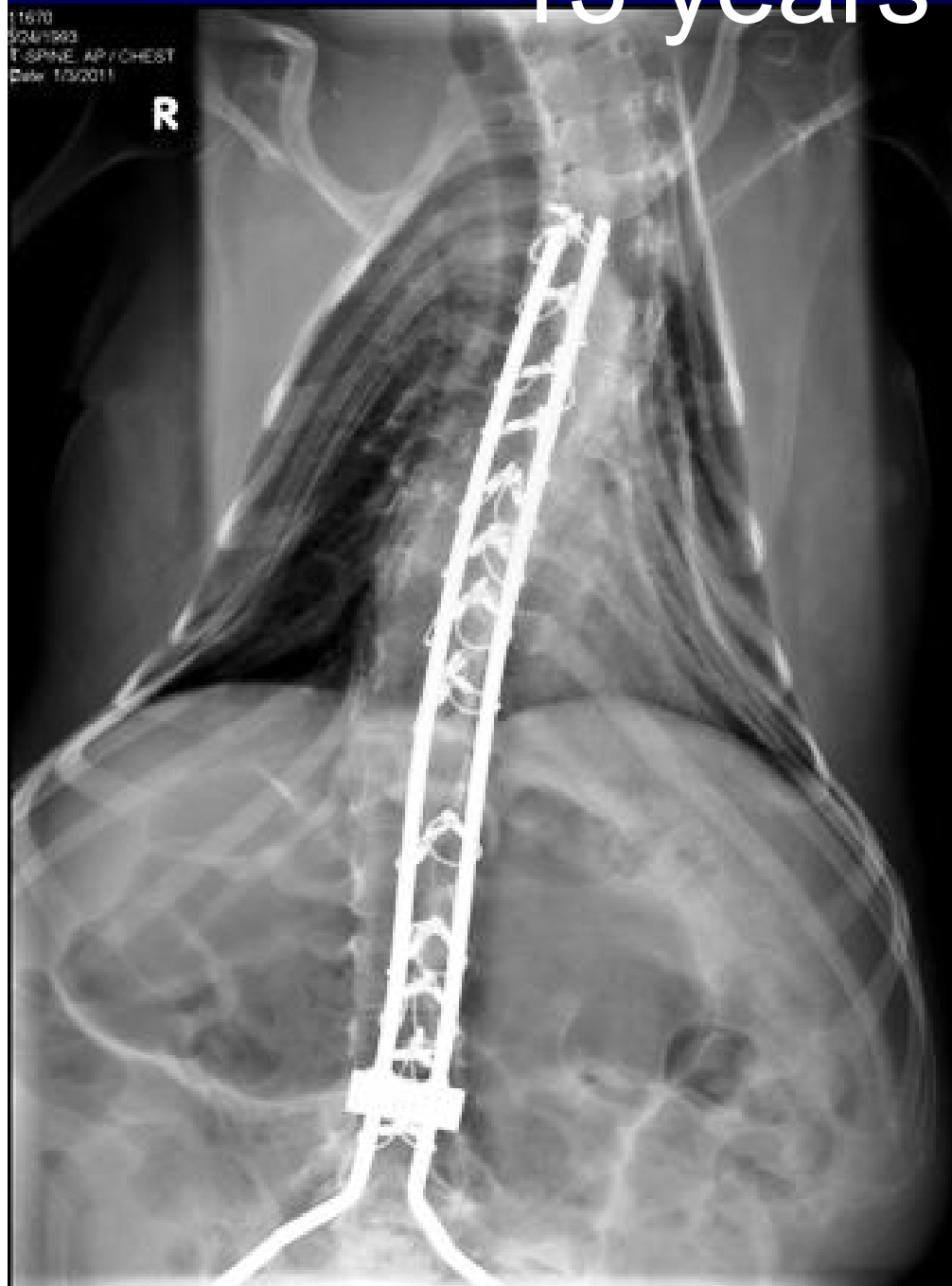
6 years post op



13 years post op

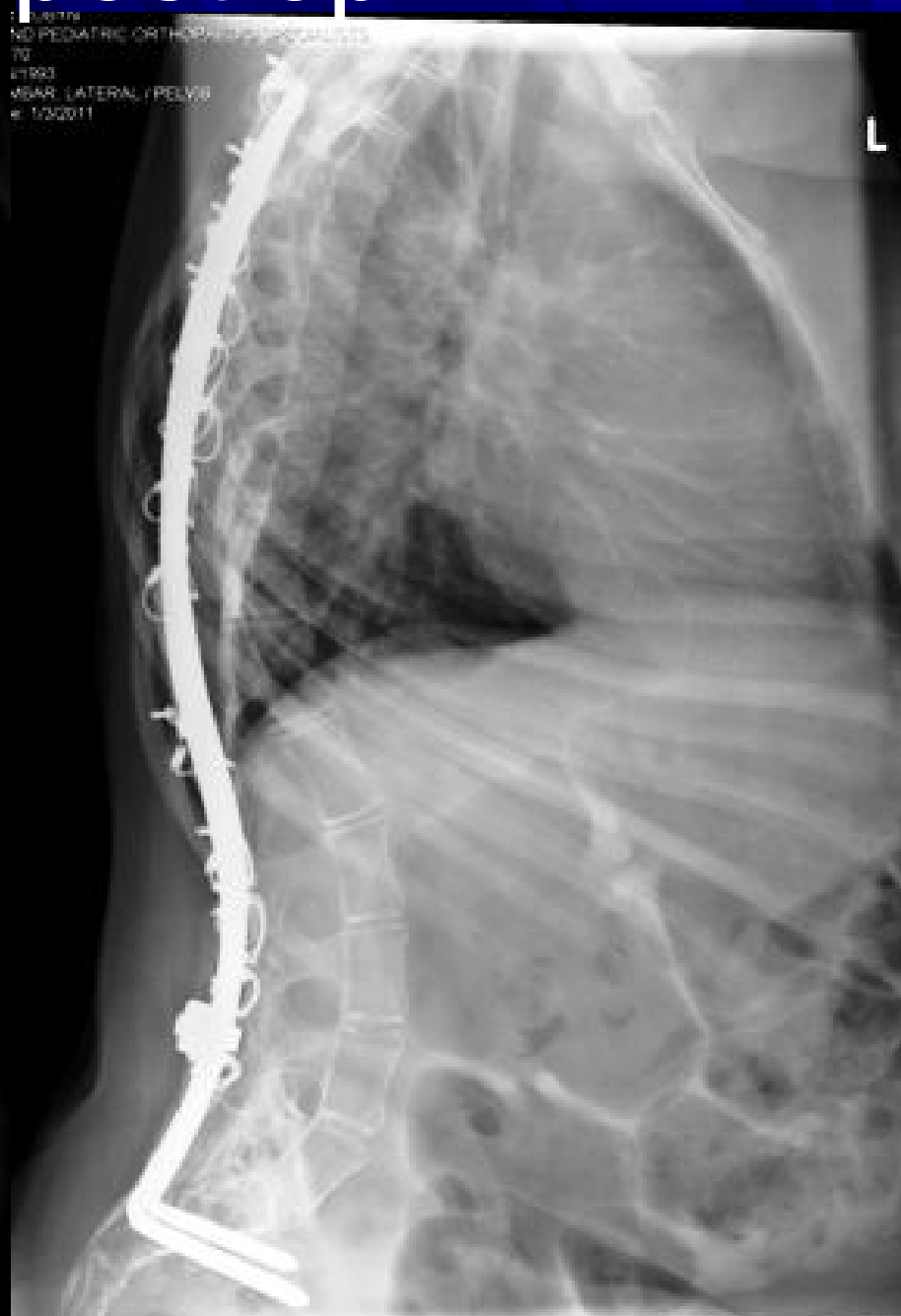11670
02/01/2003
T-Spine, AP / CHEST
Date: 1/3/2011

R

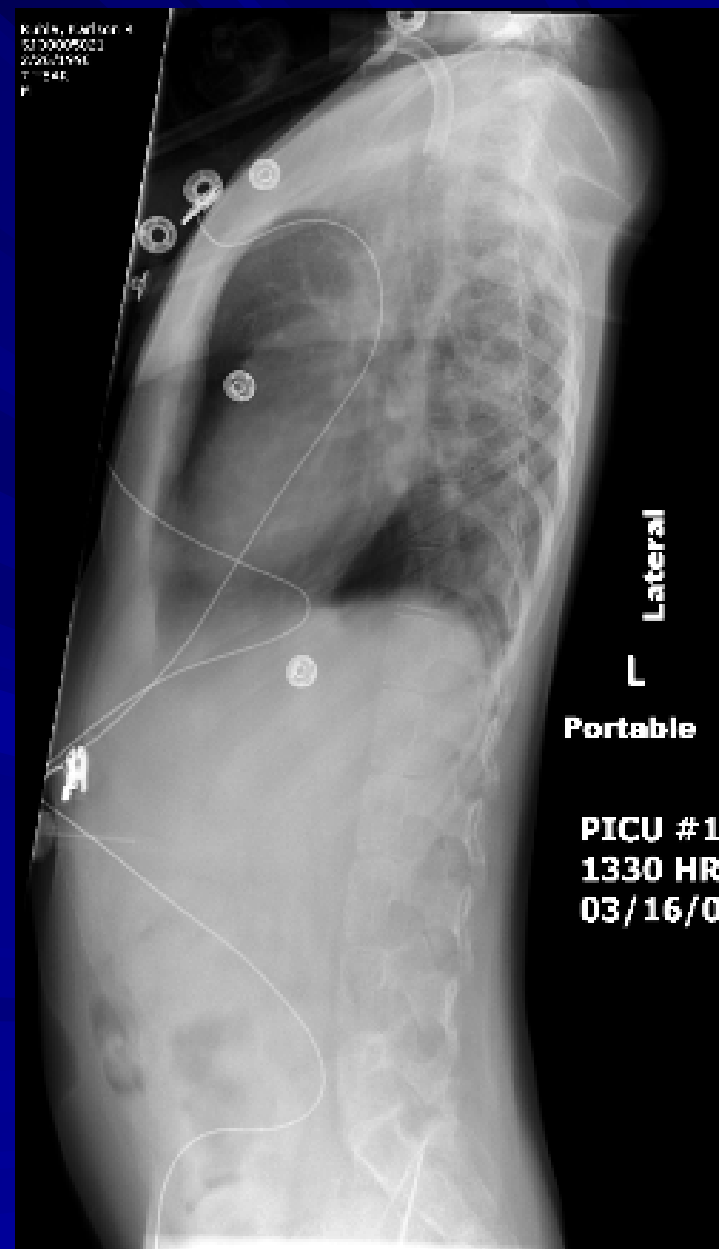
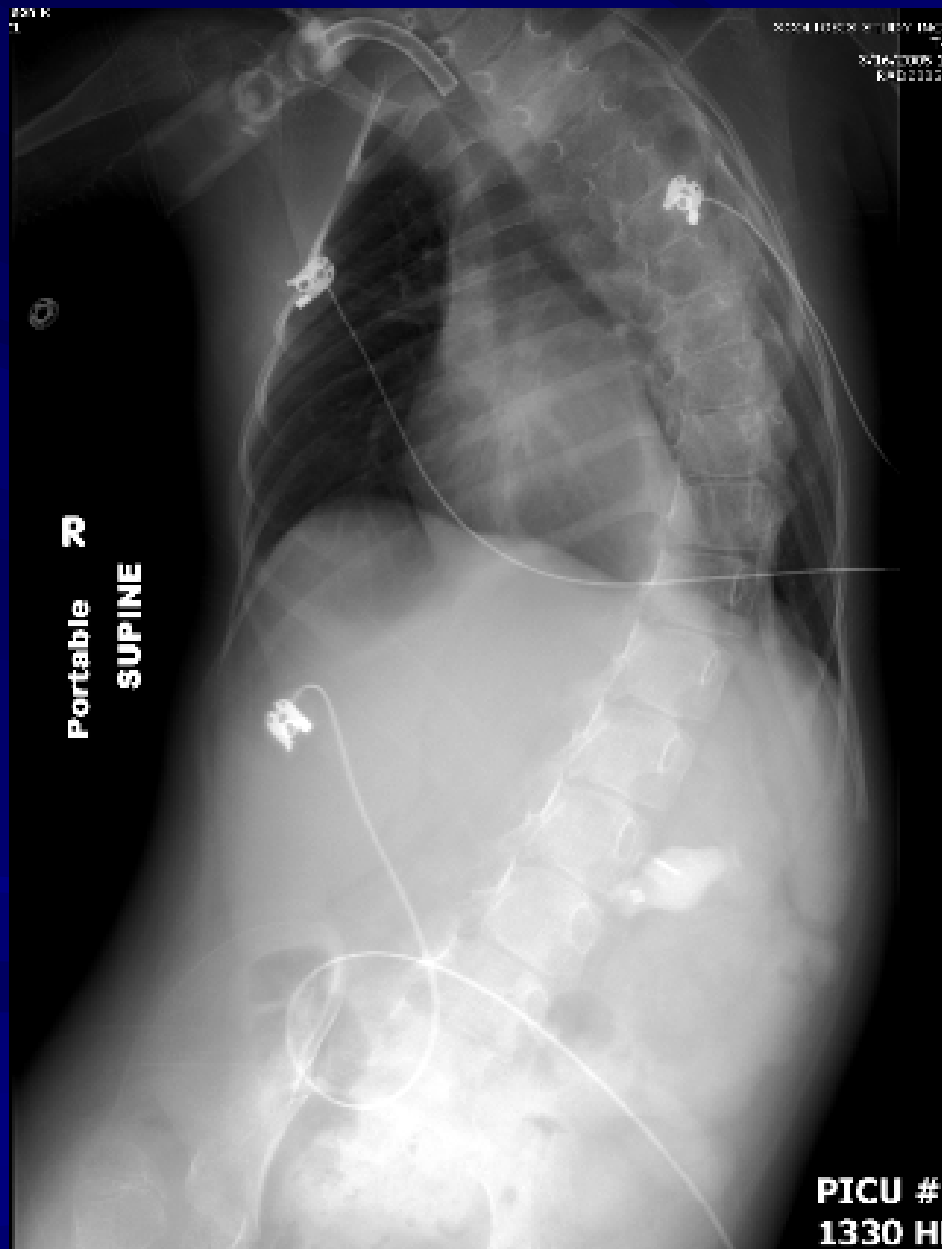


11670
02/01/2003
NO PEDIATRIC ORTHOPAEDIC SPECIALISTS
70
4/1993
WEAR, LATERAL / PELVIS
Date: 1/3/2011

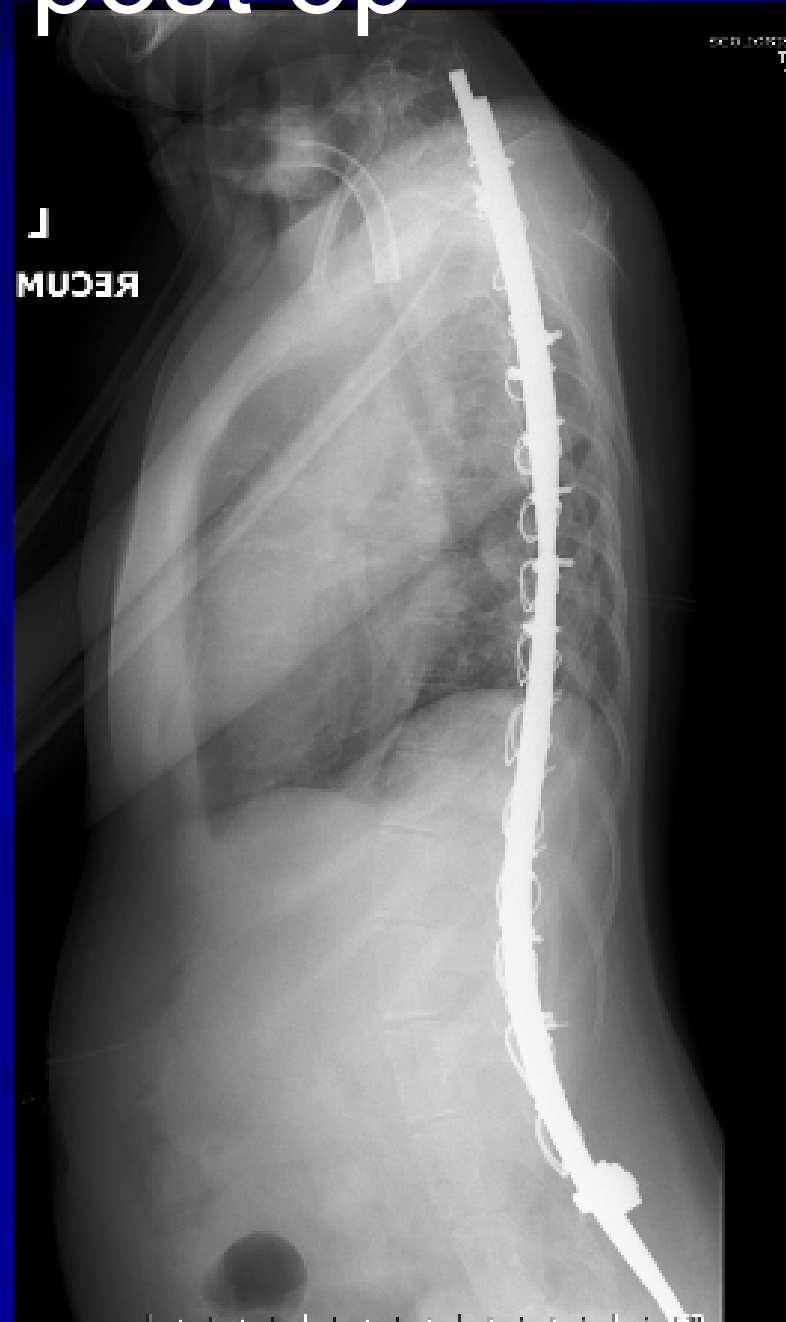
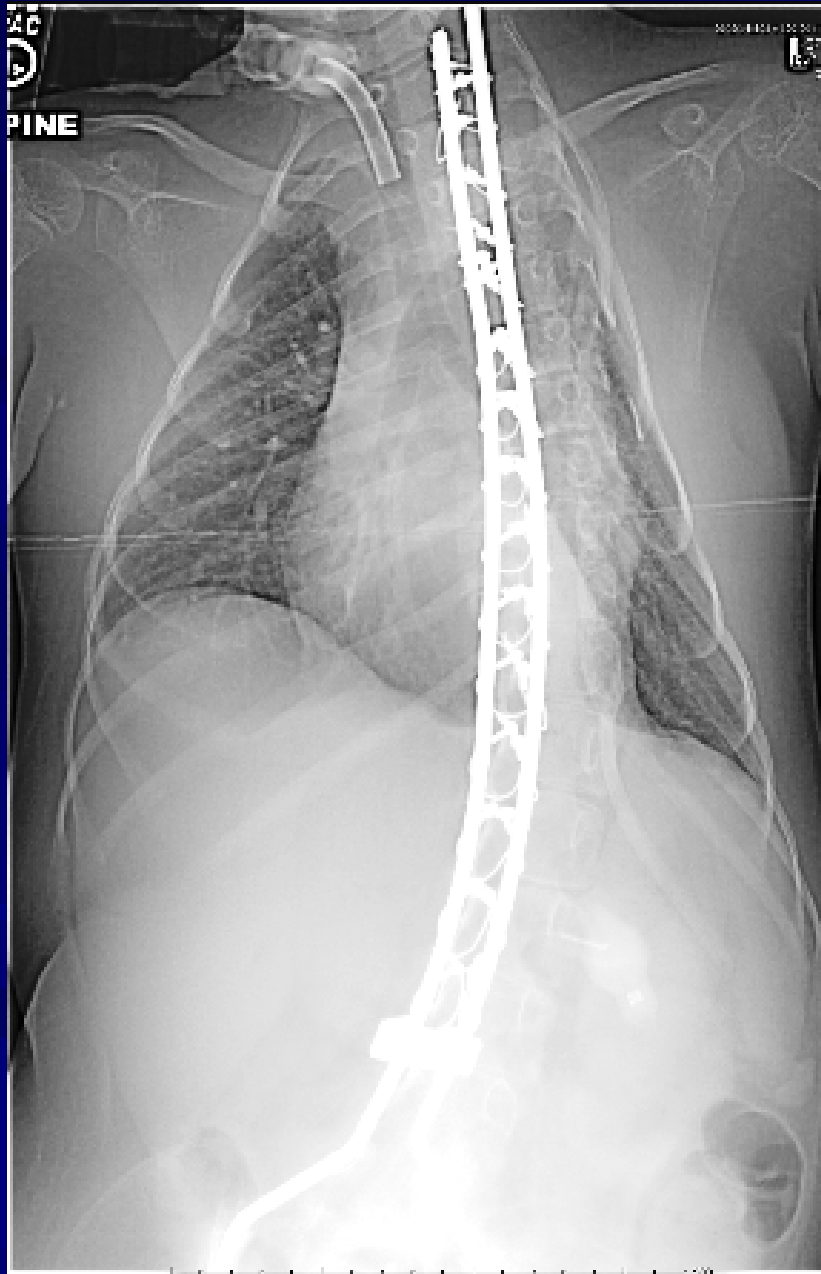
L



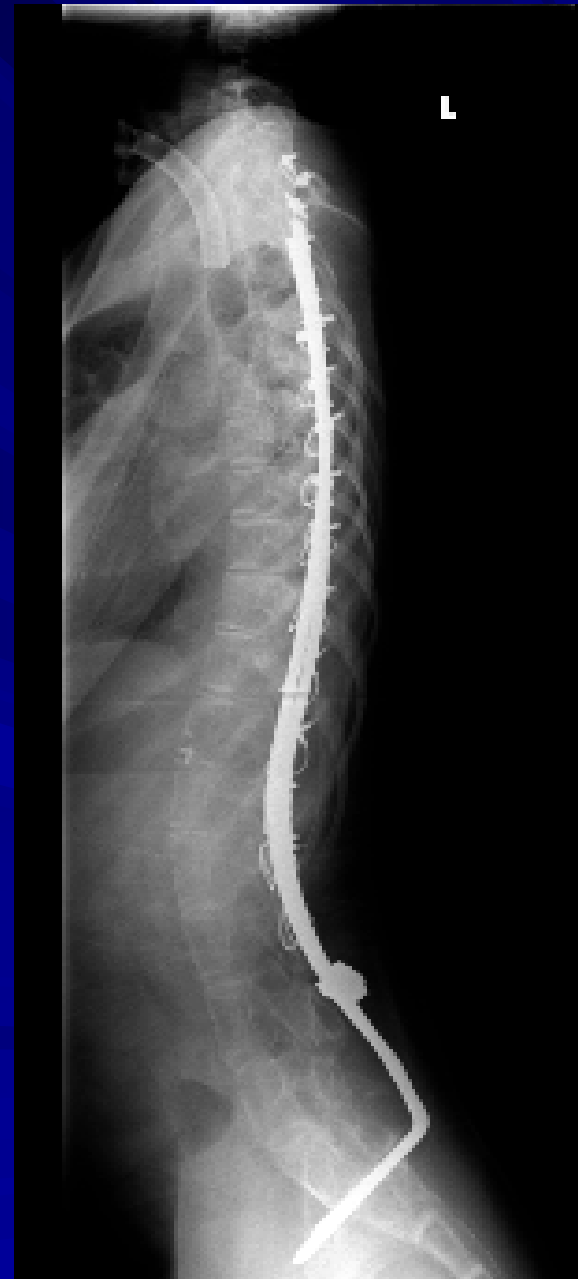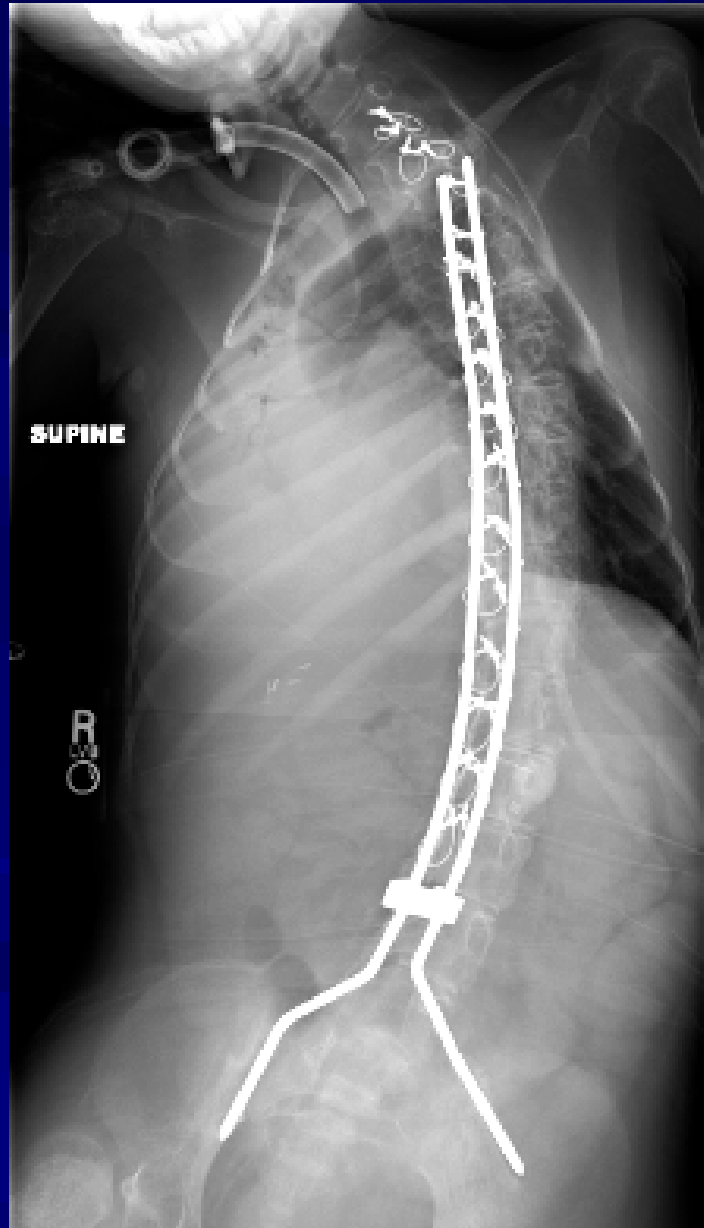
Surgery age 7 years



7 months post op



6 years post op



❖ Conclusions: Segmental Spinal Instrumentation without fusion is a safe and effective procedure when treating the spinal deformity associated with Spinal Muscular Atrophy. In this group of patients, scoliosis correction and sagittal alignment were maintained while allowing for continued growth without the use of external immobilization. None of these patients exhibited progressive restrictive pulmonary disease during treatment. Complications did not interfere with the spinal growth or compromise the instrumentation.

Take Home Points

- ❖ Growing Segmental Spinal Instrumentation without fusion is a well-tolerated & effective surgical technique that avoids the morbidity associated with multiple surgeries in this very fragile patient subset

