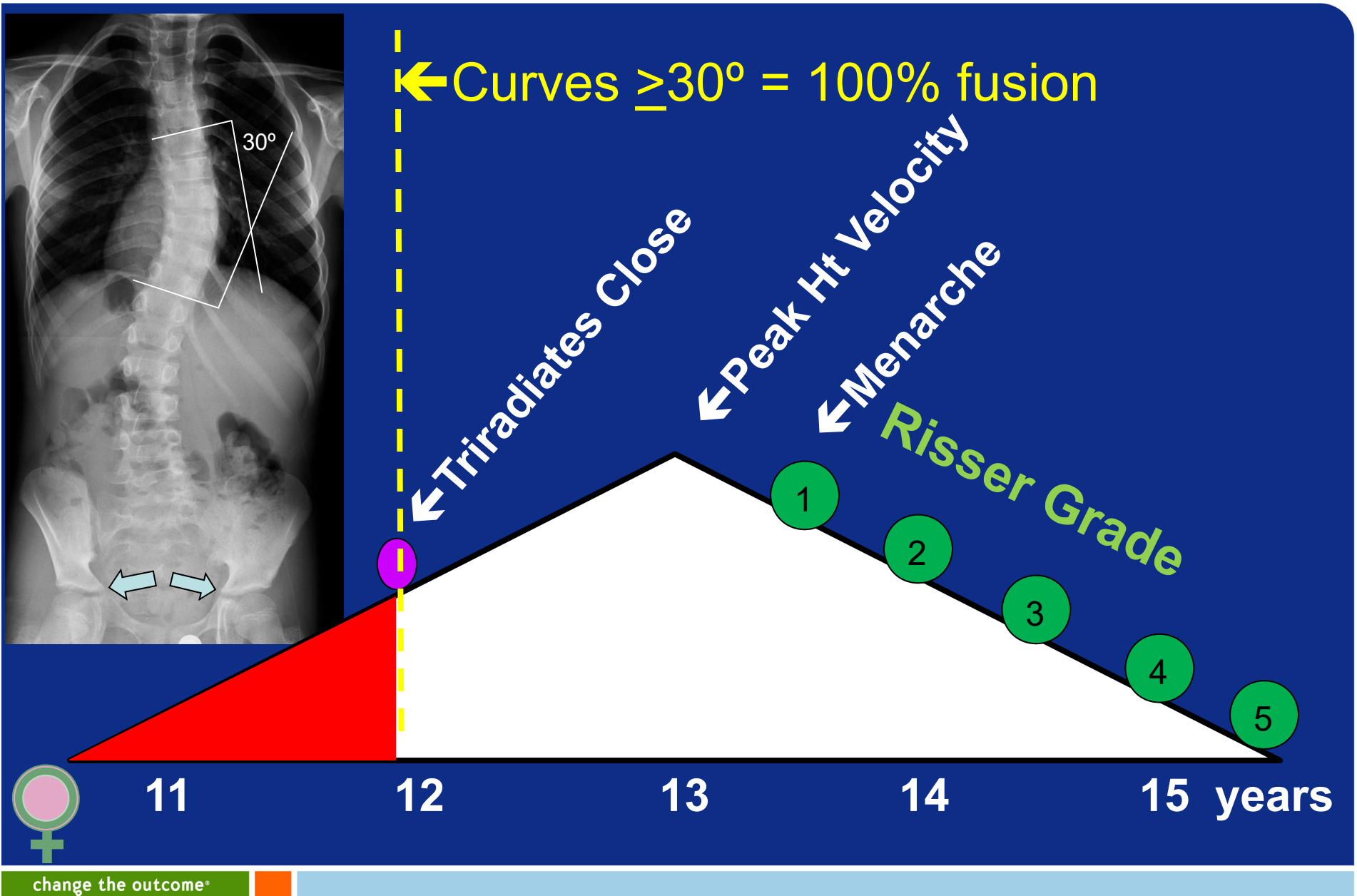


Reliability of Triradiate Cartilage and Risser Sign Staging on Pelvis and Scoliosis Radiographs

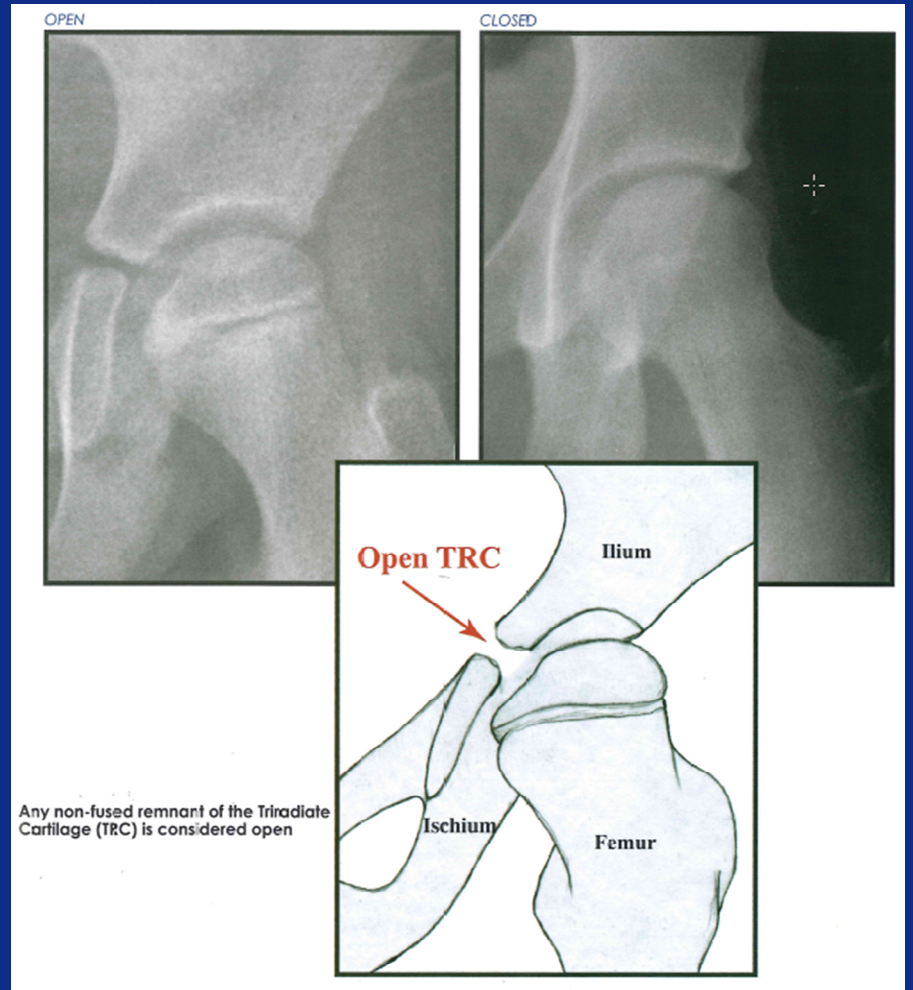
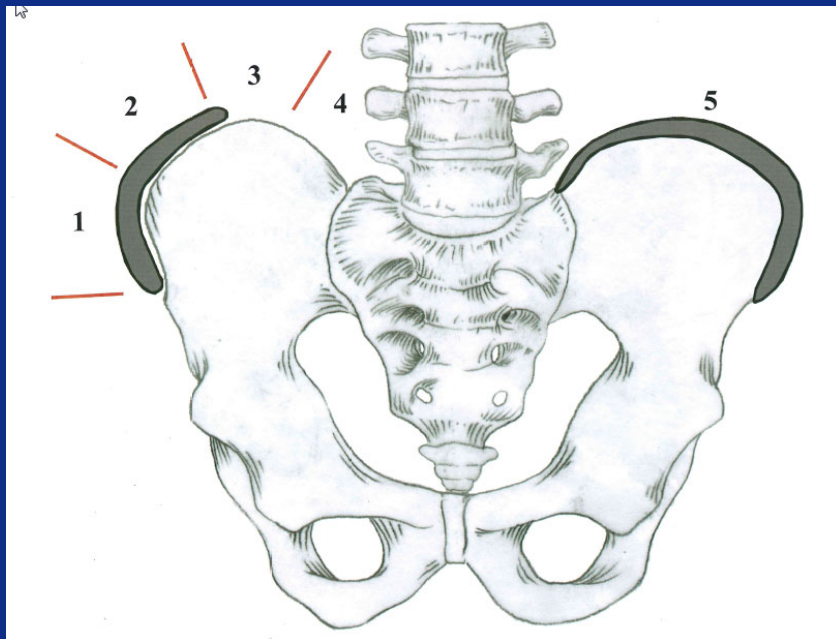
Nathan S, Wall E, Eismann E,
Jain V, Crawford A, Sturm P

RISK OF SCOLIOSIS PROGRESSION

- Correlates with remaining growth
 - Growth Curve, Peak Height Velocity
 - Hand x-ray
 - Guerlich and Pyle
 - Sander's Digital Skeletal Age
 - Risser sign. Triradiate cartilage
 - Elbow (Sauvergrain, Dimeglio)
 - Menses, Tanner Stage



Spine Film

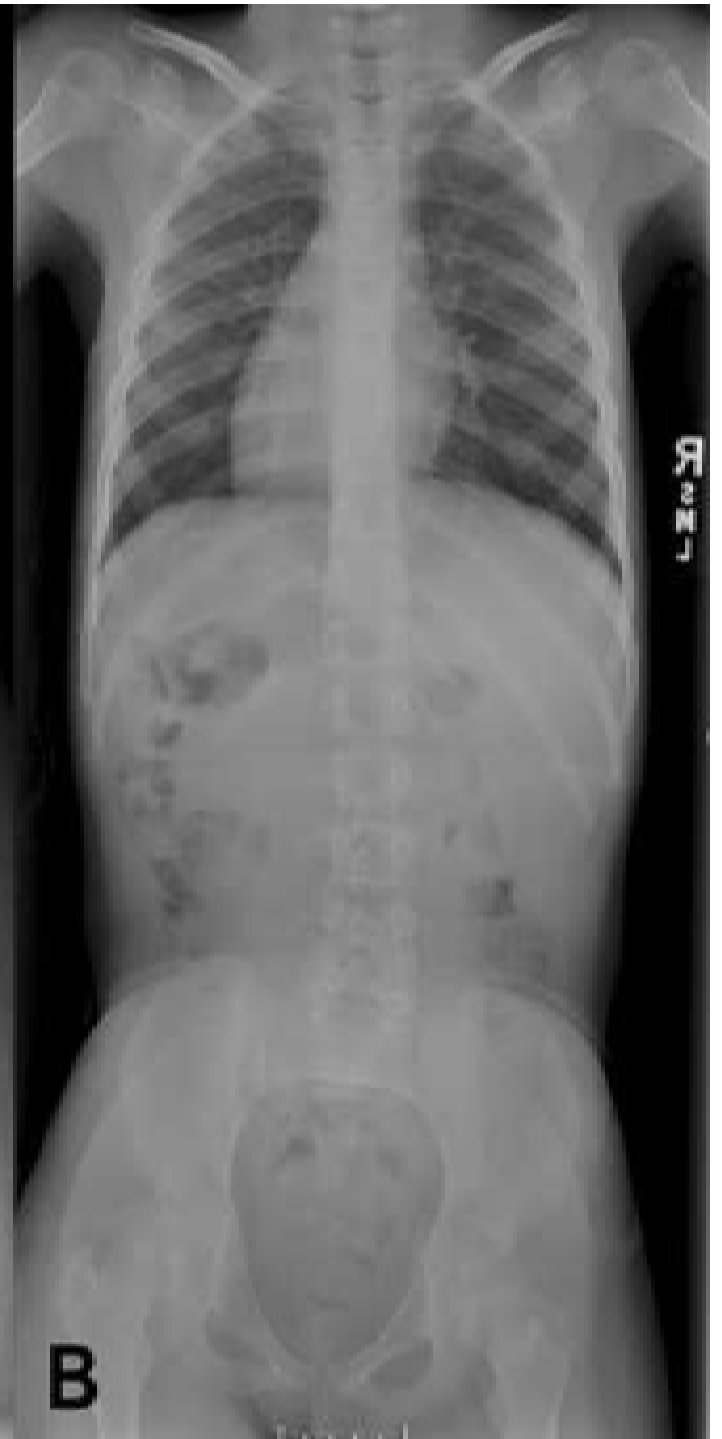
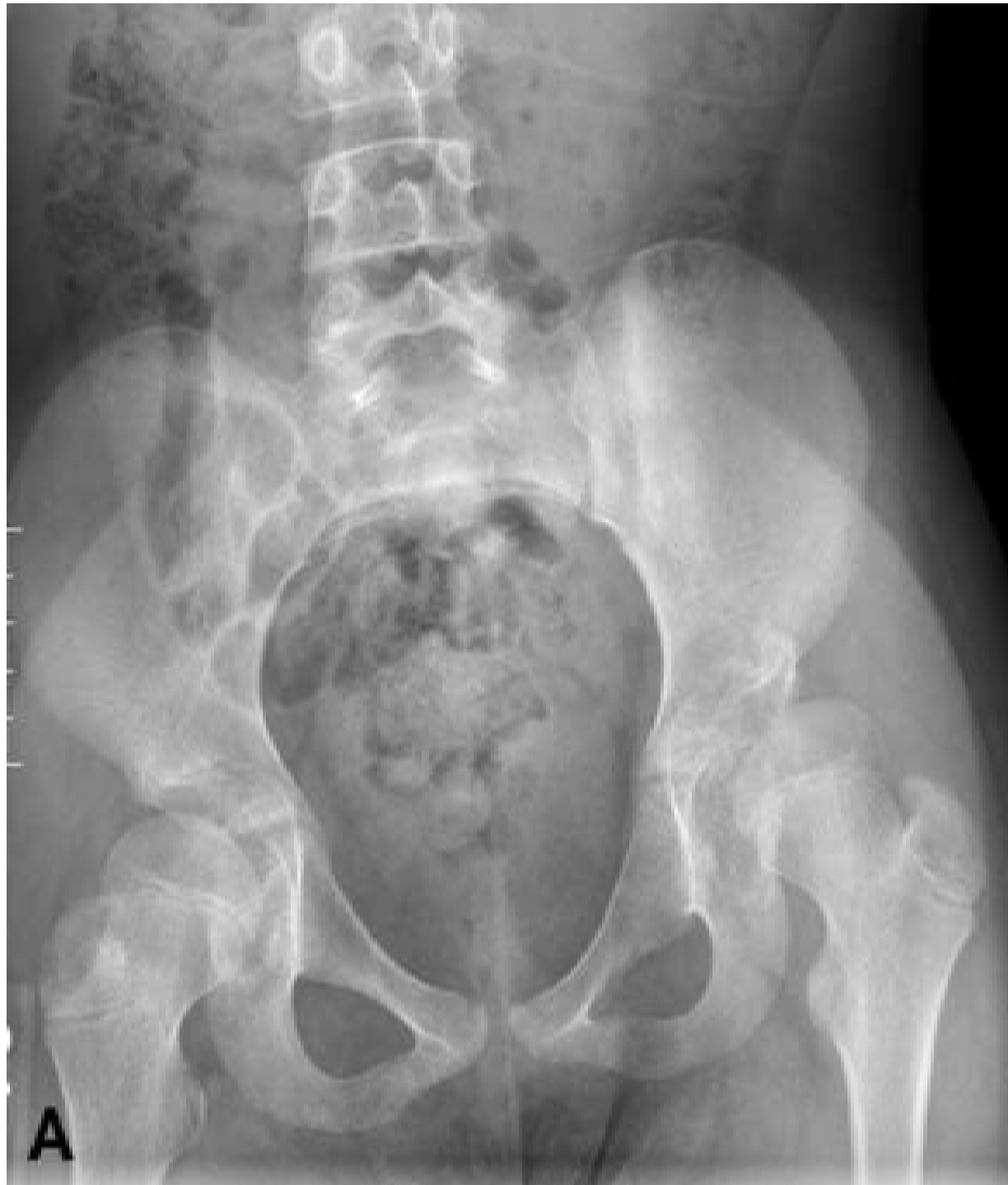
change the outcome®

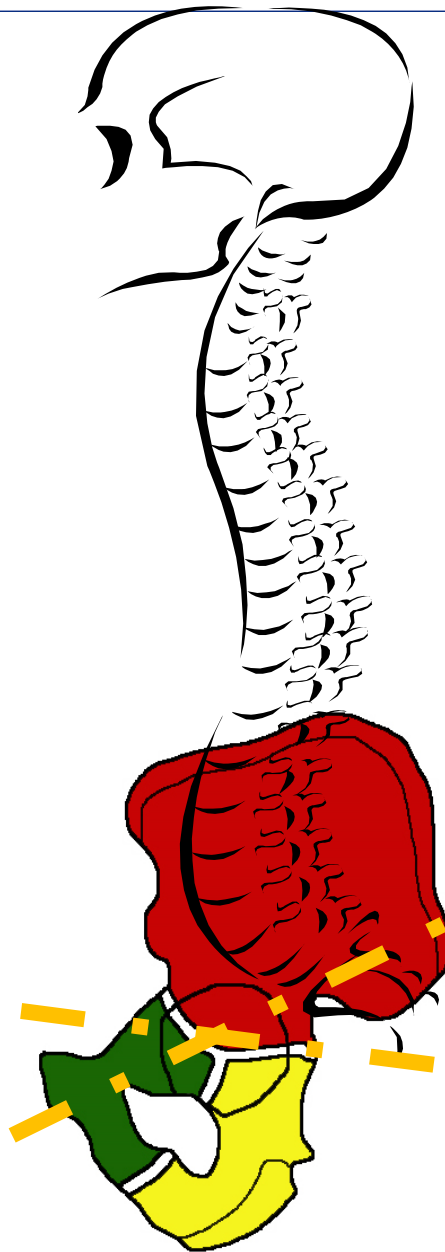
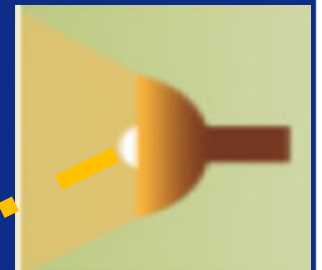
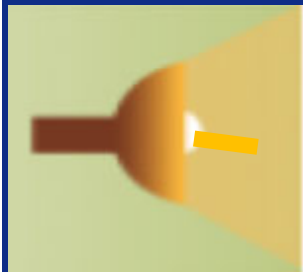
Eric Wall MD
ICEOS 11/16/1012

Question

- We noticed a patient in our pre-op scoliosis conference appeared to have a closed triradiate on her scoliosis film, but an open triradiate on a pelvis film taken the same day.



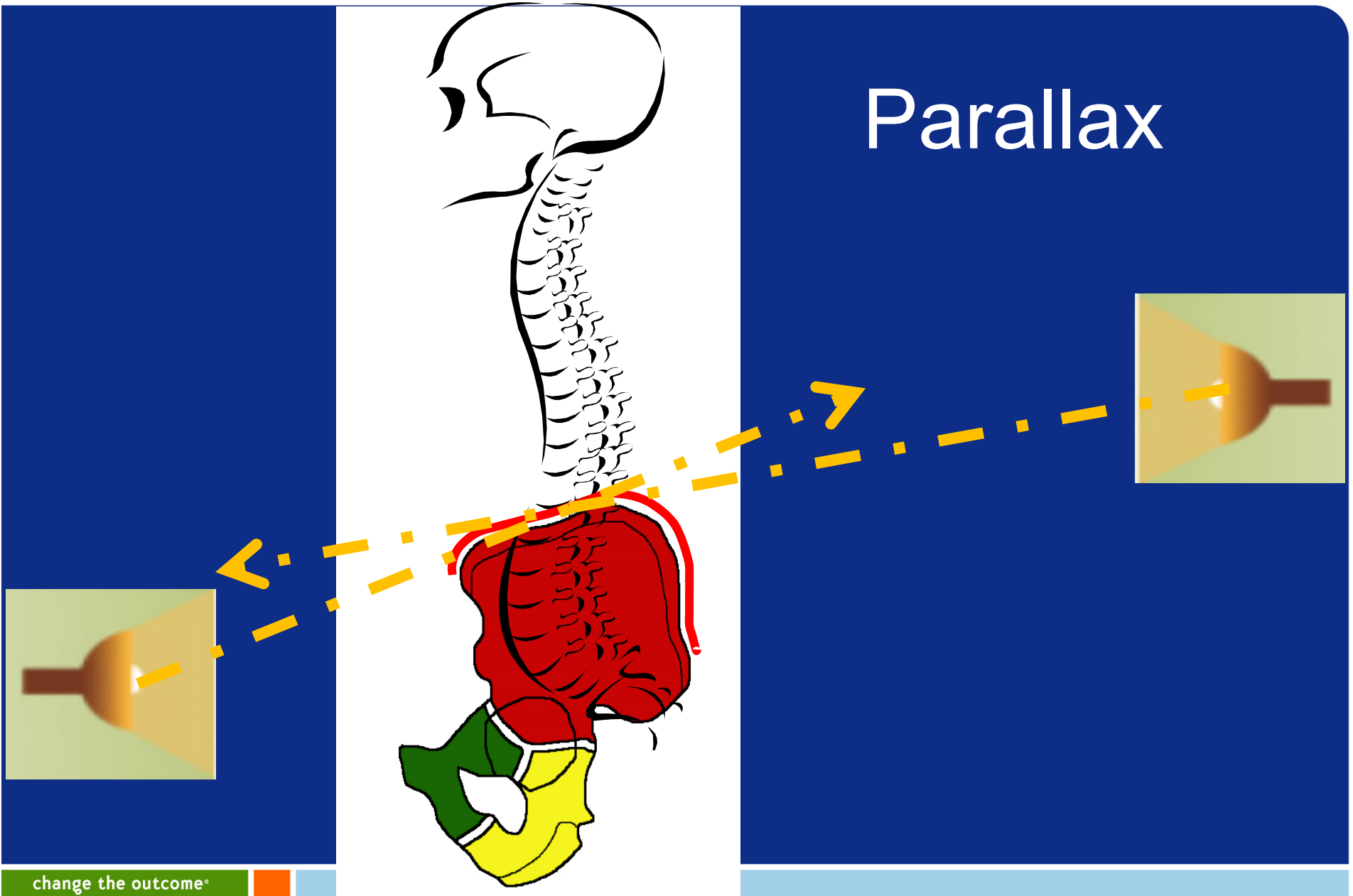
Parallax



change the outcome*

Eric Wall MD
ICEOS 11/16/1012

Parallax



change the outcome®

Eric Wall MD
ICEOS 11/16/1012

Gap in Knowledge?

- No studies comparing pelvis to scoliosis films for Triradiate or Risser Sign
- No studies on Triradiate reliability

Methods

- 43 adolescents with coincidental pelvis and scoliosis film taken < 3 months apart
- 3 reviewers rated films twice, one month apart
- Reliability calculated
 - between reviewers (INTER)
 - same reviewer at different time points (INTRA)

Reliability Vocabulary

- Cohen's kappa (Pelvic to Scoli film)
 - $\geq .60$ substantial agree
- Randolph's kappa (among all raters)
 - $\geq .70$ =acceptable agree

Pelvic better than Scoliosis

		Pelvis	Scoliosis
INTER	Triradiate	.86*	.76
	Risser	.80*	.60
INTRA	Triradiate	.77	.80
	Risser	.79*	.66

change the outcome*

Triradiate Cartilage

- Classified differently on pelvis and scoliosis films 23%, with 80% read as more immature on pelvis

Risser Sign

- Classified differently on pelvis and scoliosis films 22% of time, with 56% being more immature on pelvis.

Prior Studies Risser

- Goldberg '98
 - Kappa .8 on scoliosis films
- Shuren '92
 - Kappa .31-.53 on scoliosis films
- Reem '09
 - Kappa .93, .86, .88 using pelvic films

If Critical

- Use pelvic film to judge Triradiate or Risser

Thank you

change the outcome®

Eric Wall MD
ICEOS 11/16/1012

