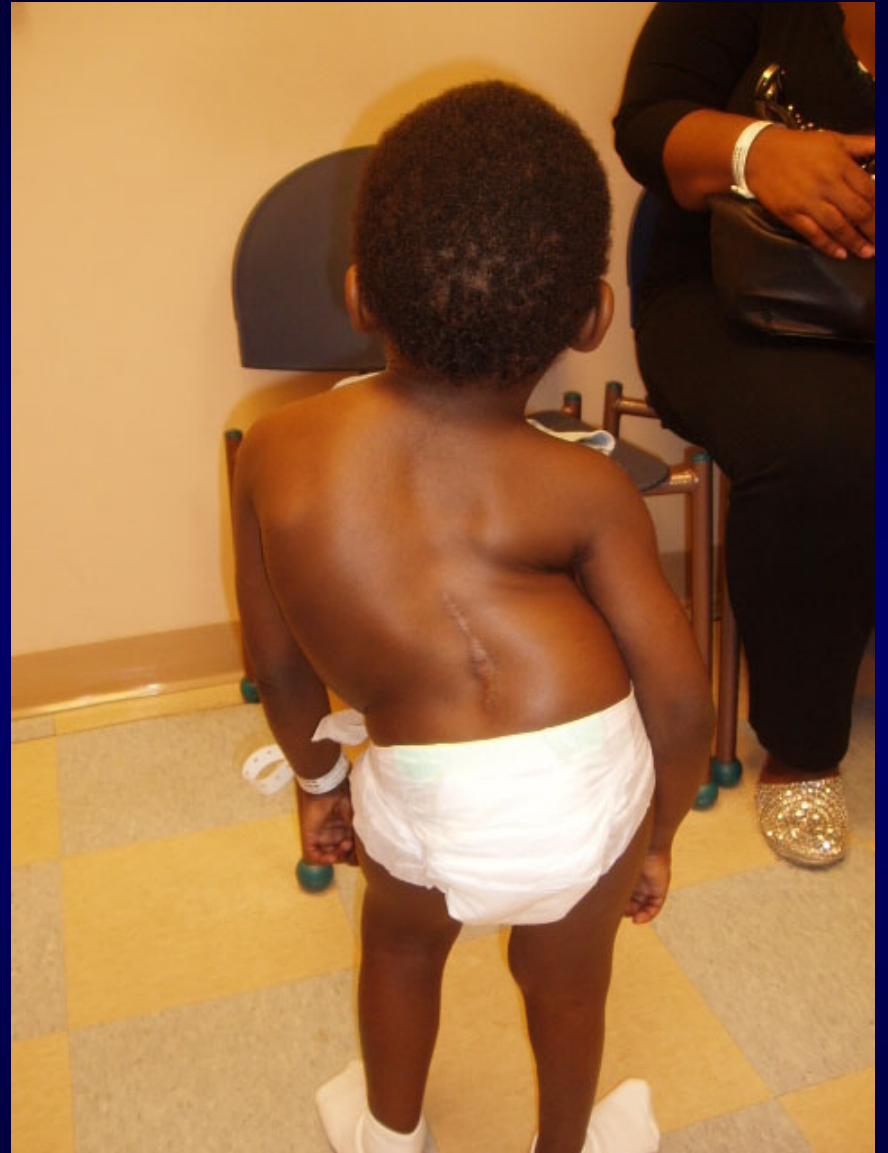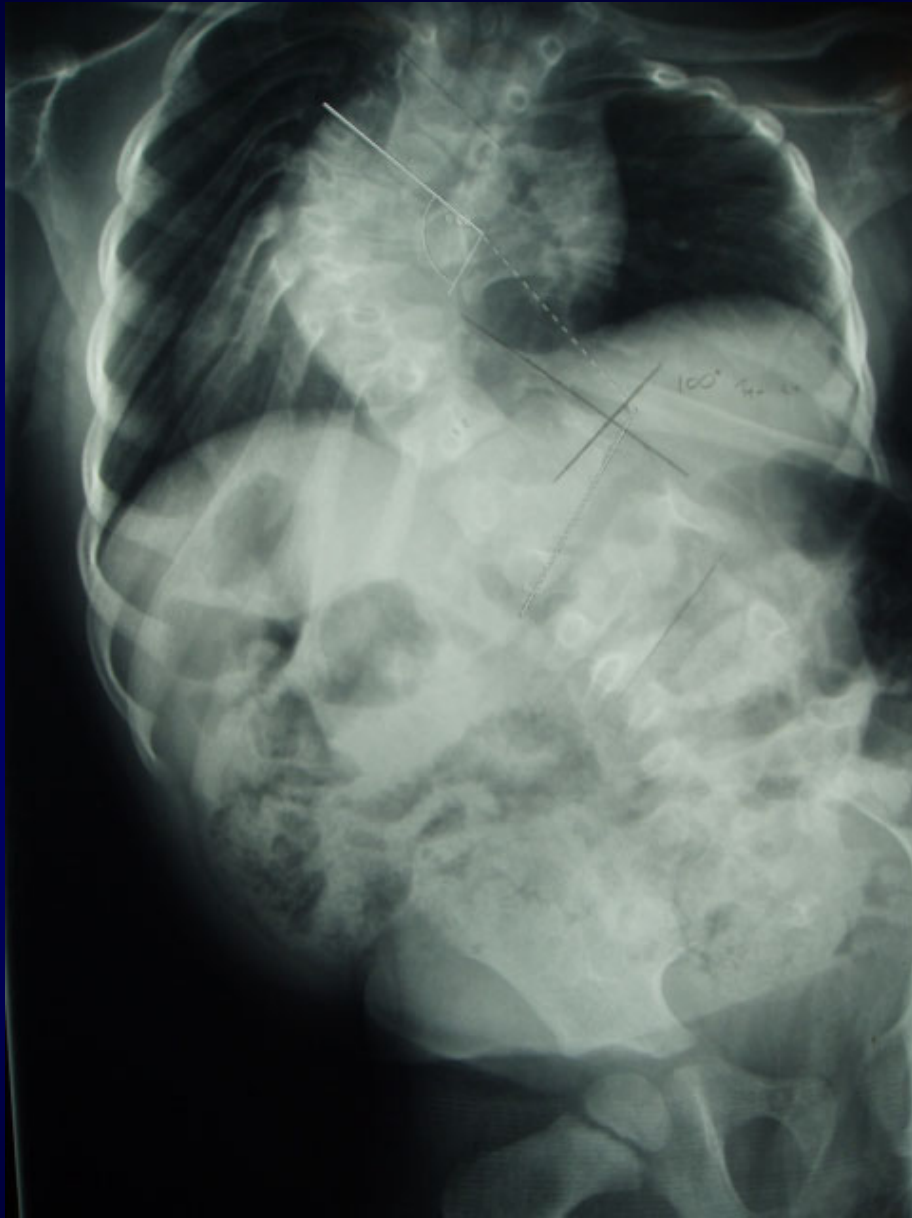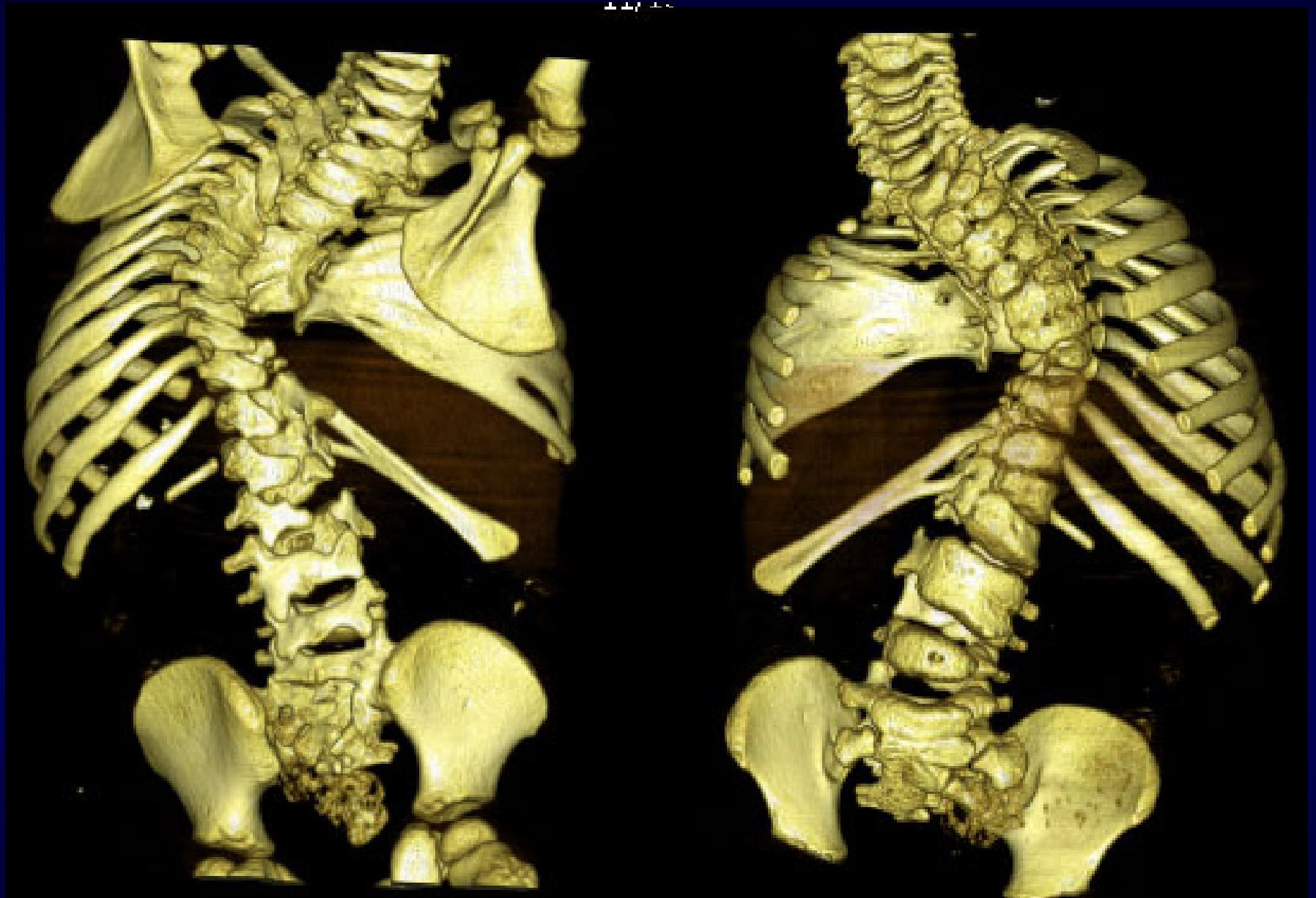


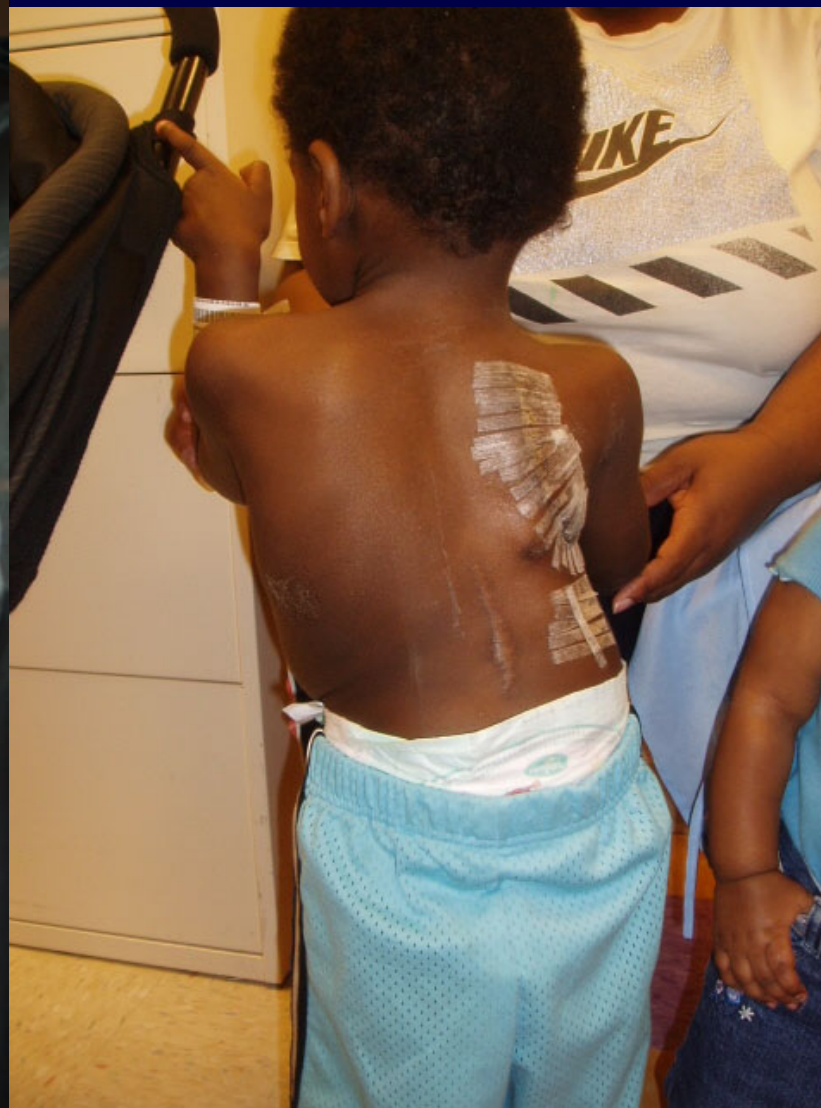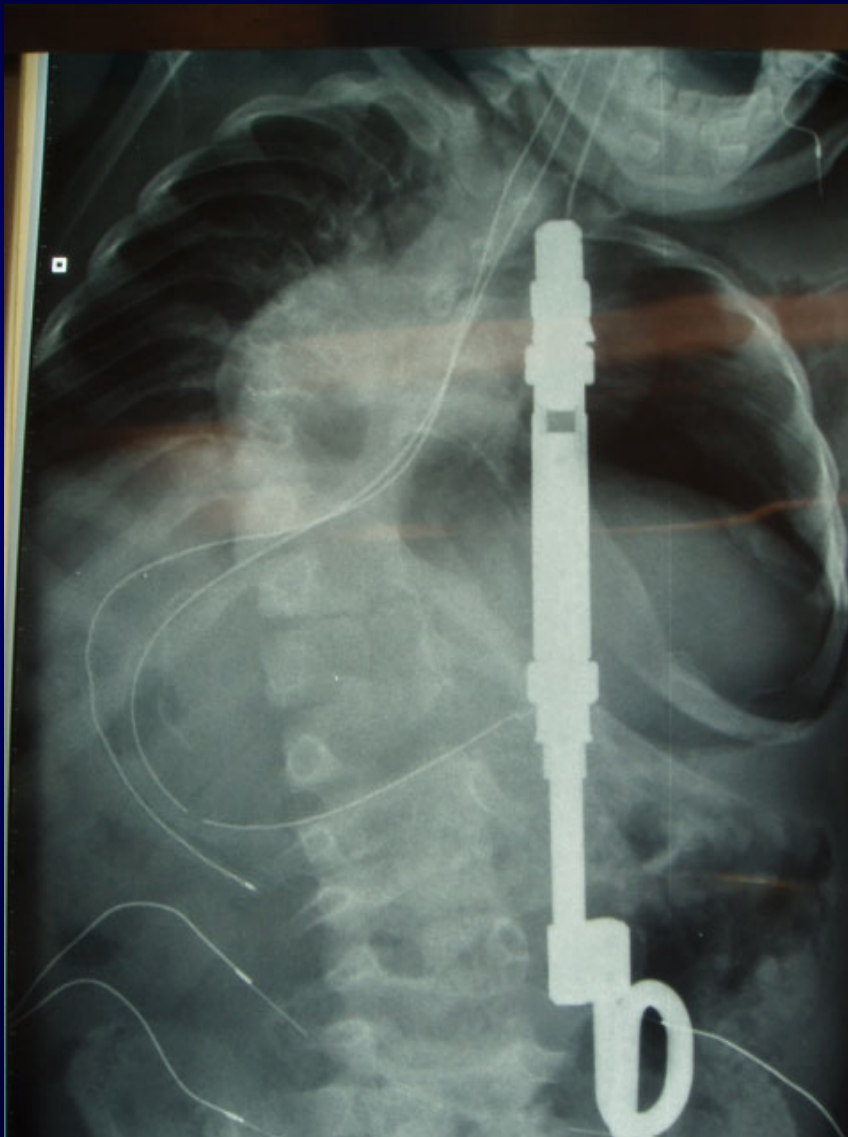
JT

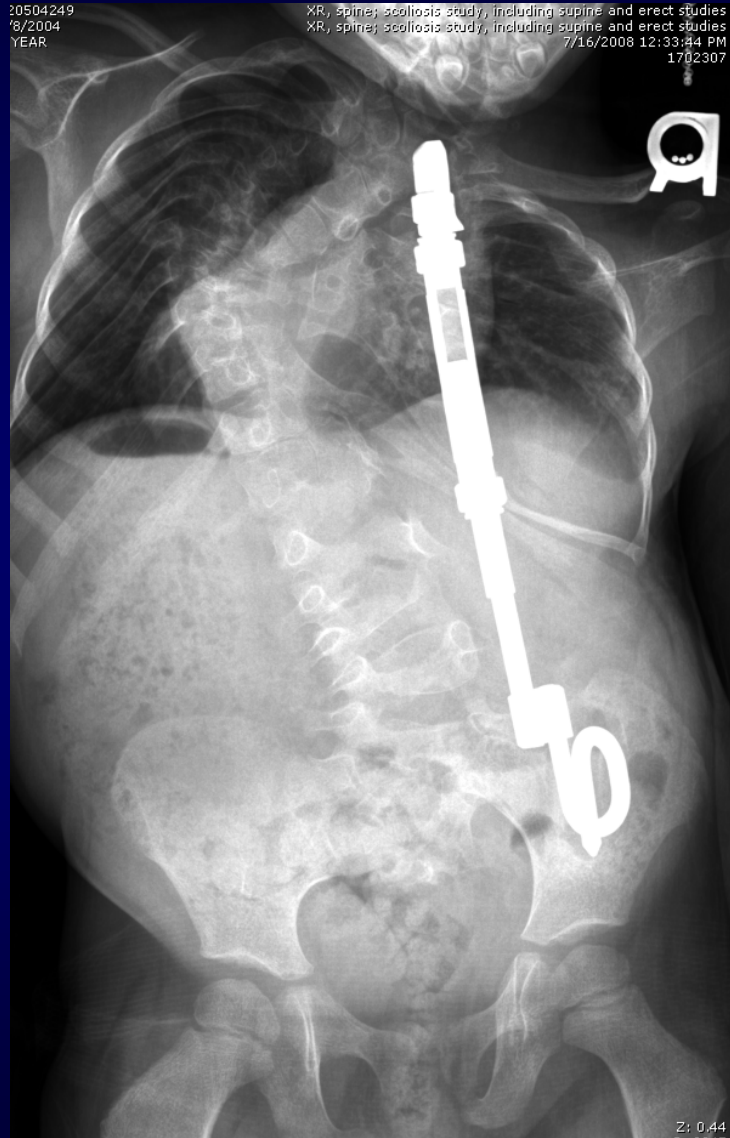
4 yo M



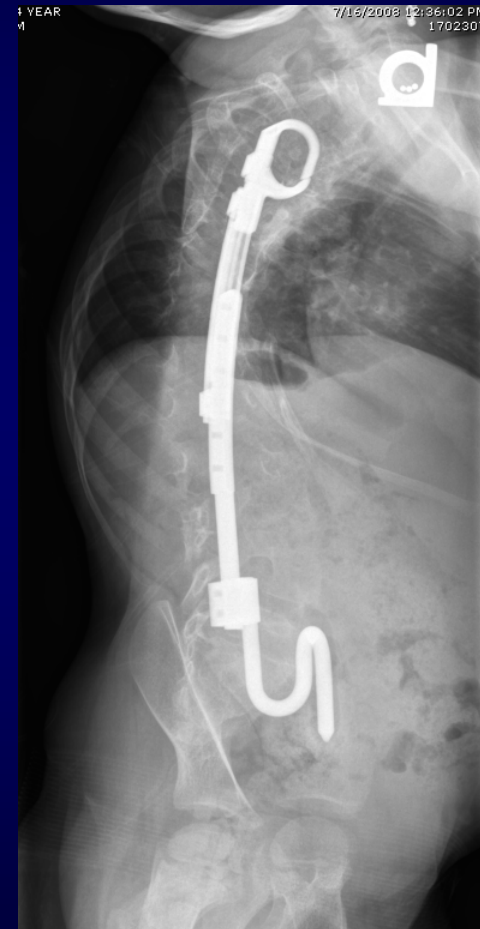


4/2007

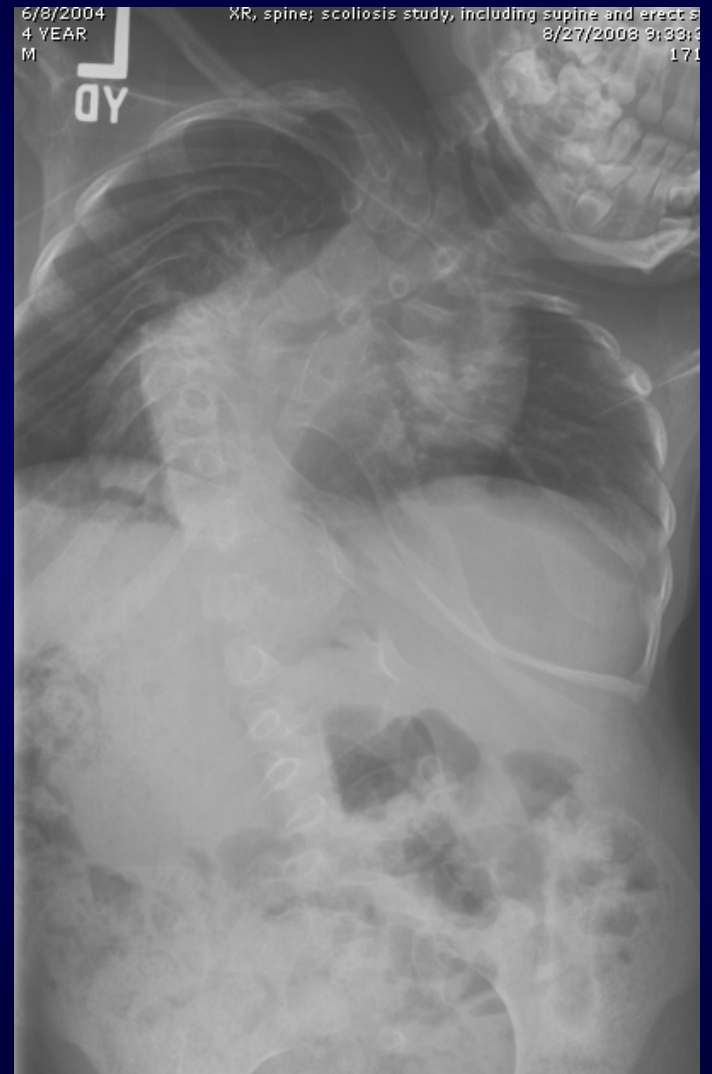


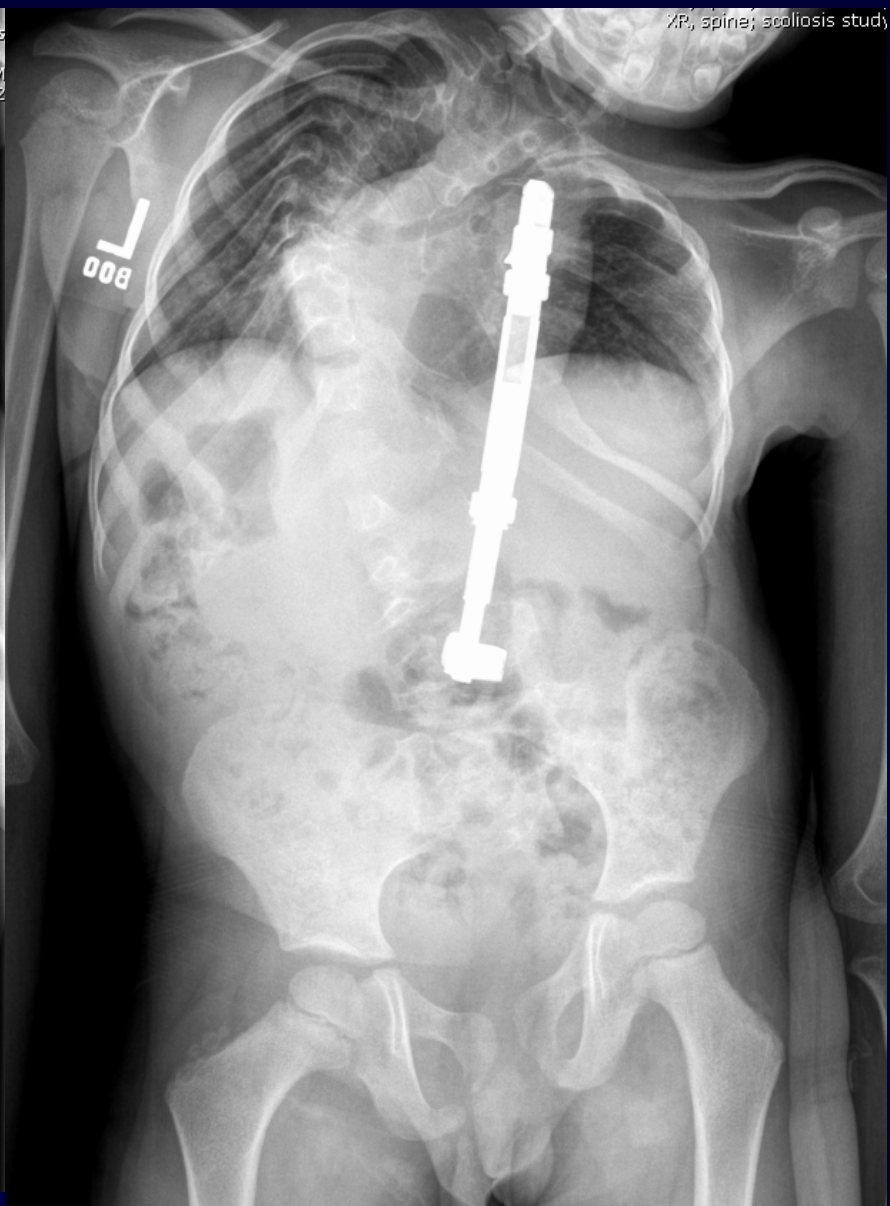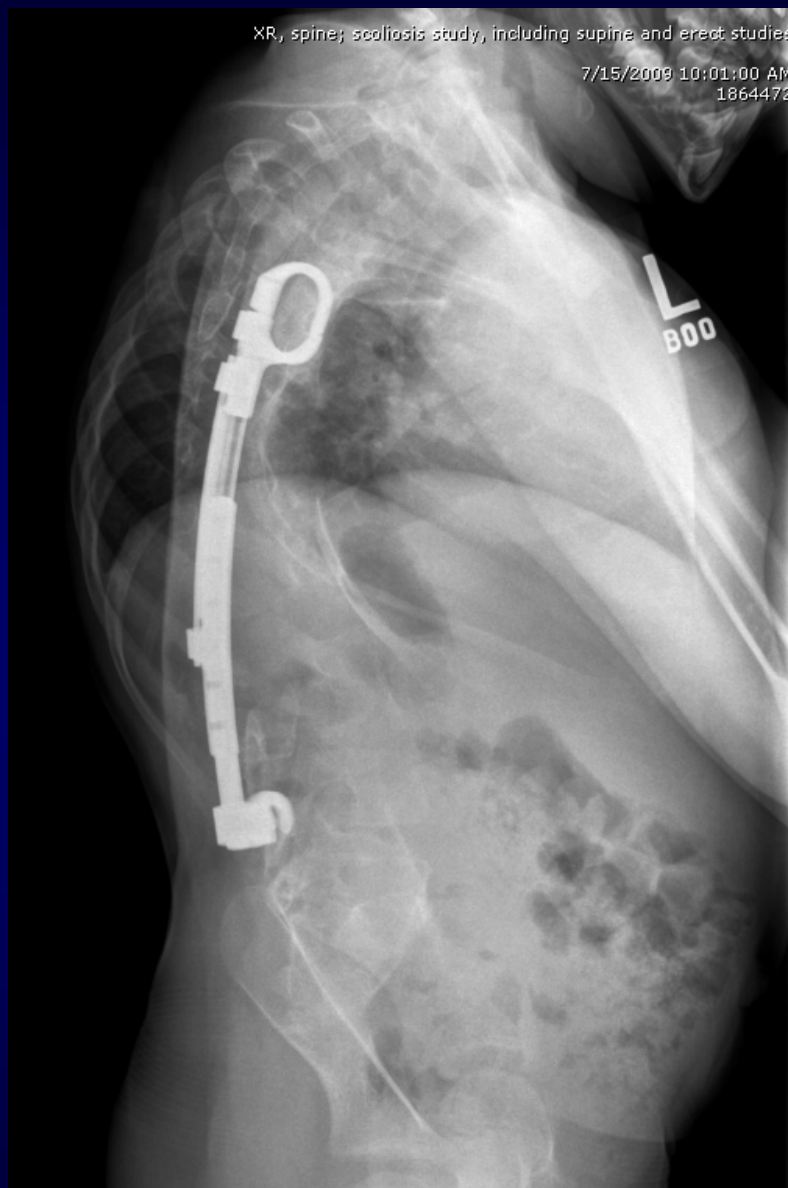


1 year later

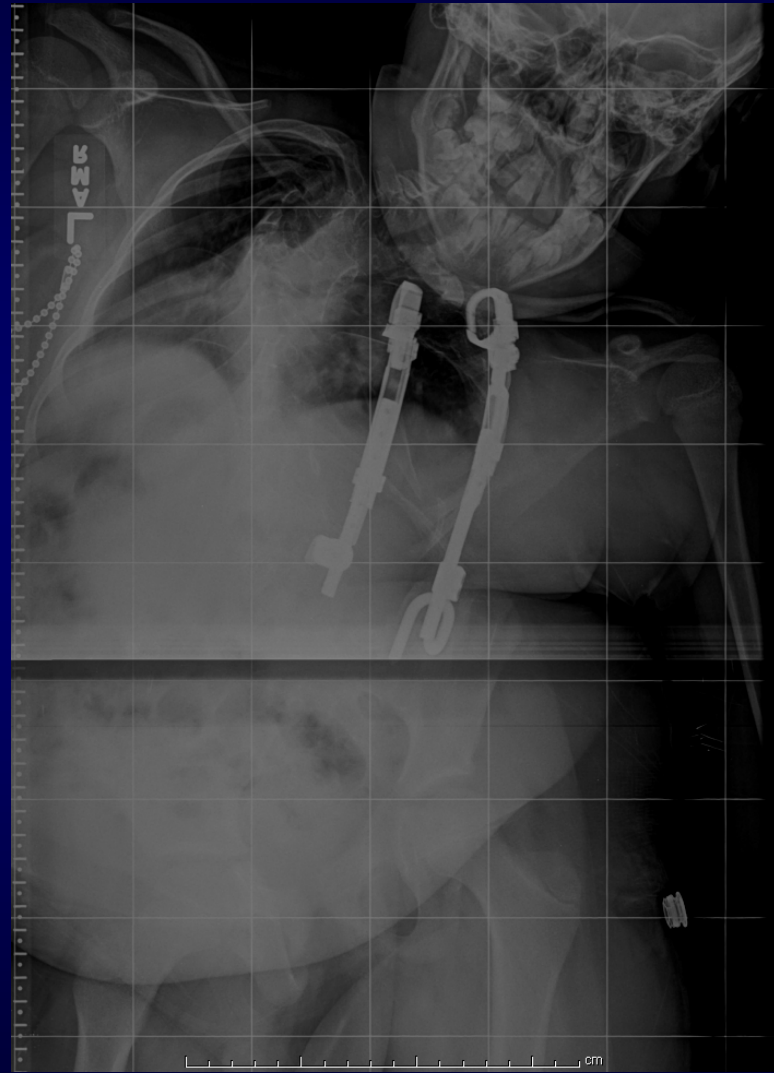
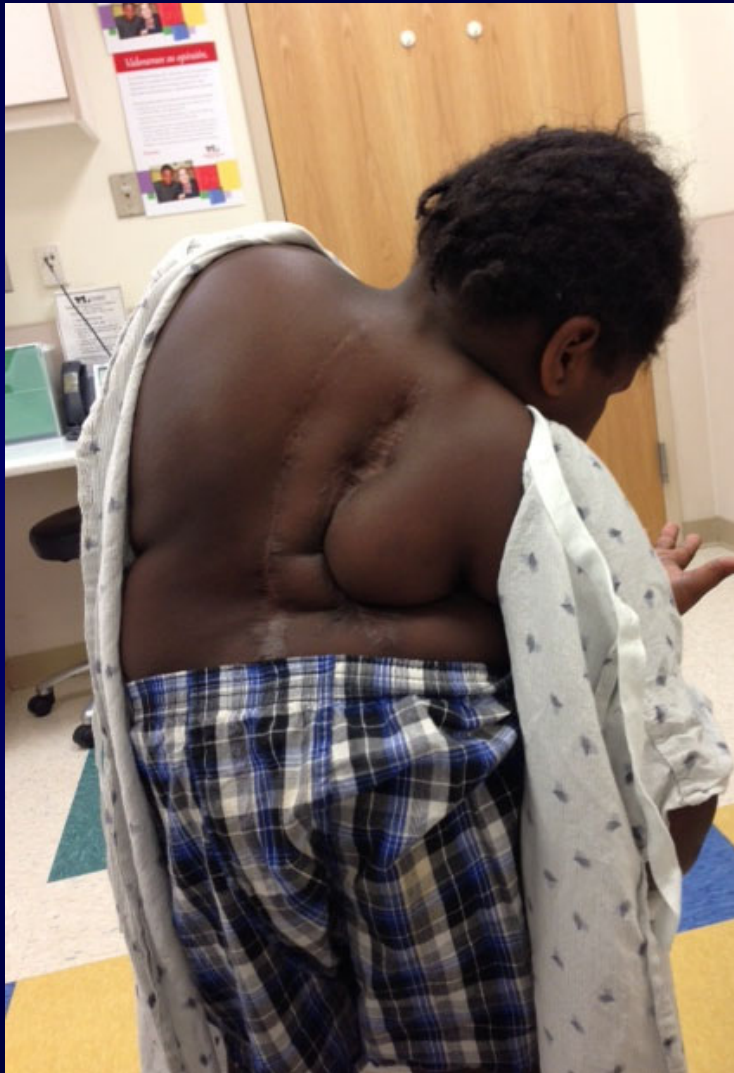

- 7/30/08- entire VEPTR infected → removed
- Treated w/IV abx
- VEPTR replaced with muscle flap 10/08

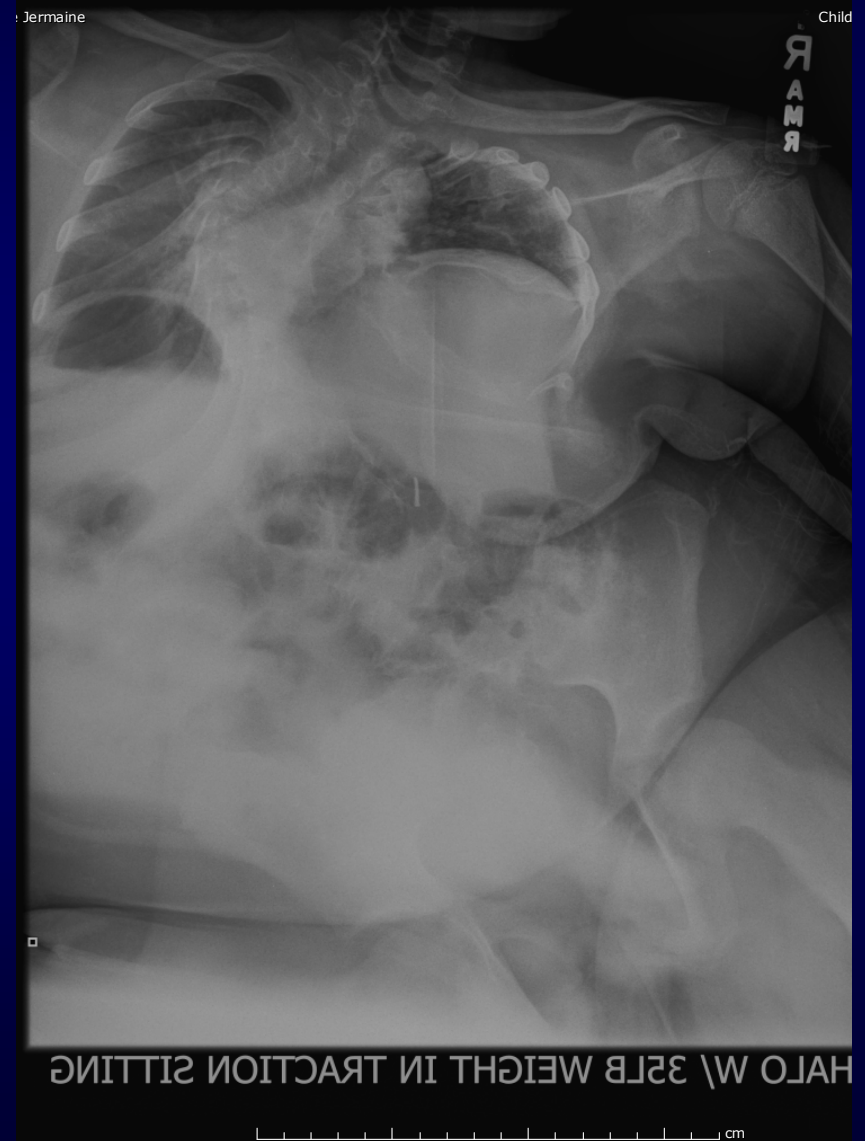
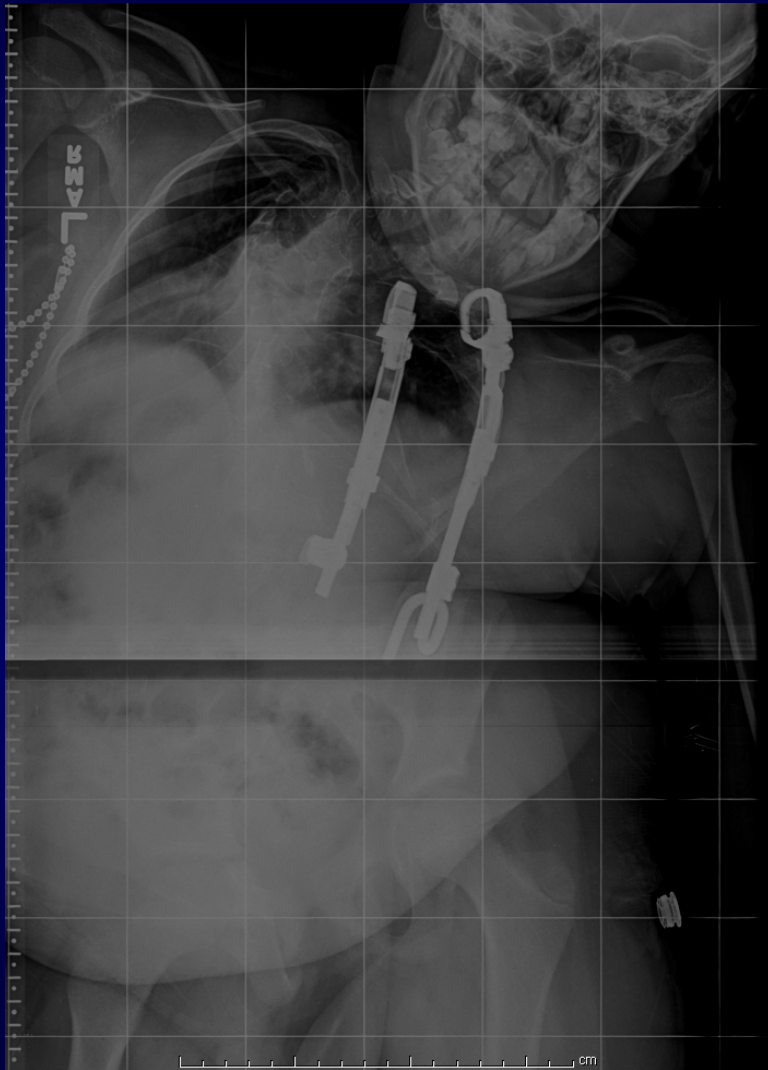


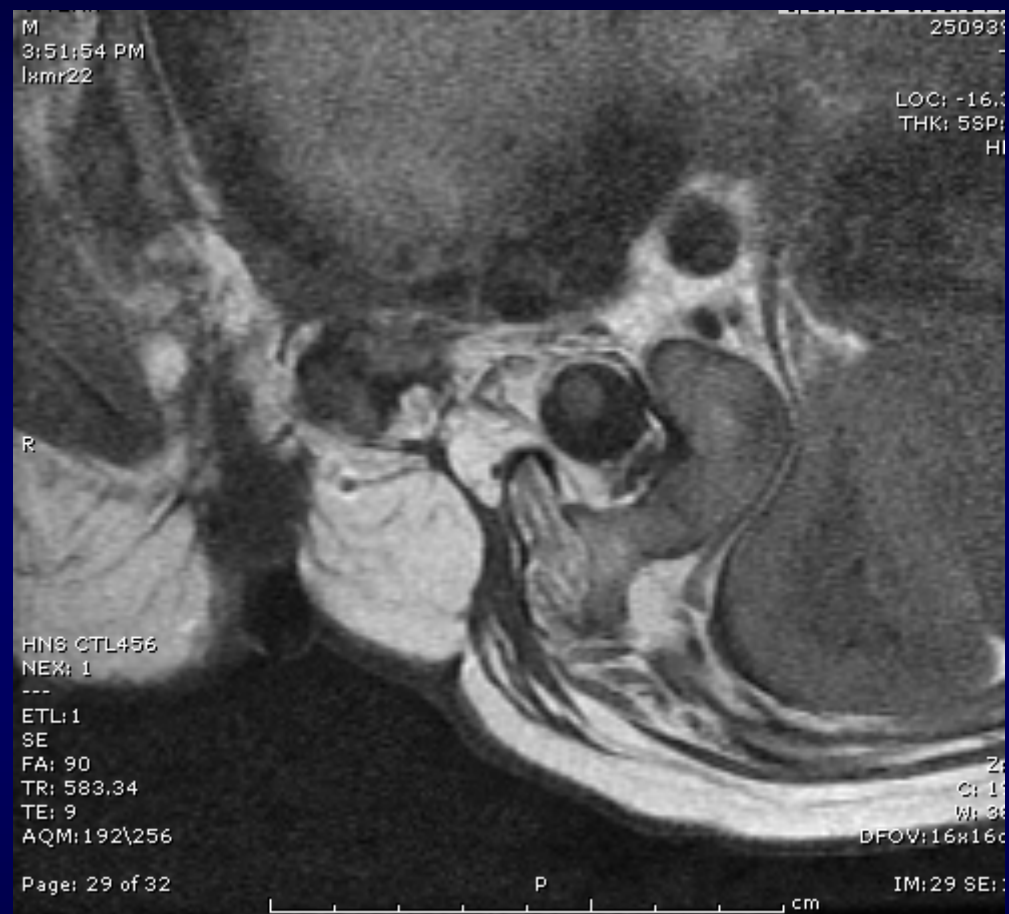
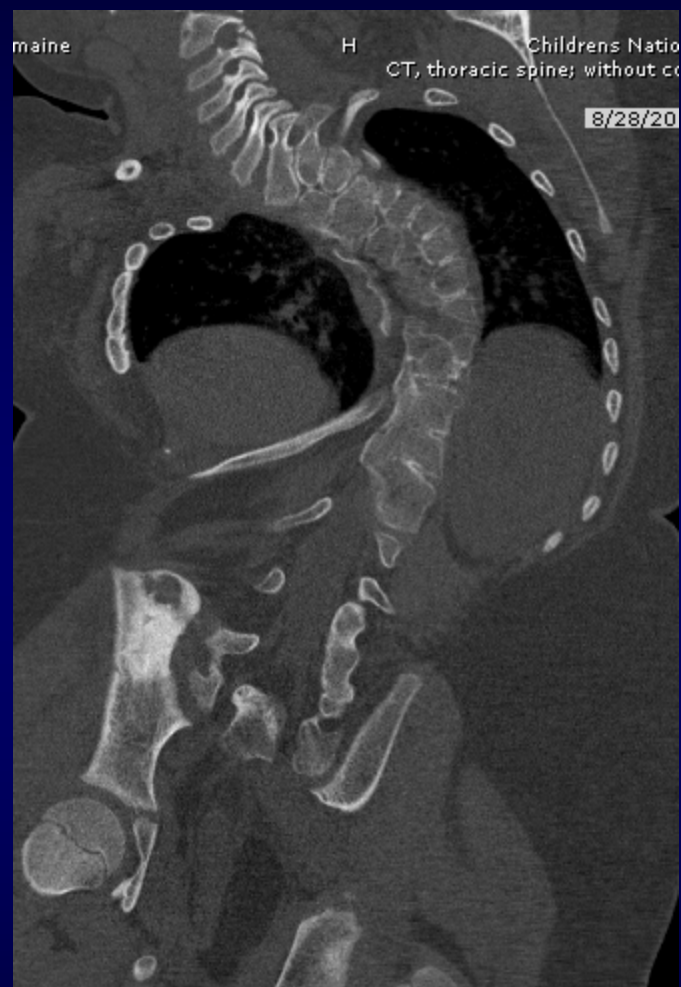
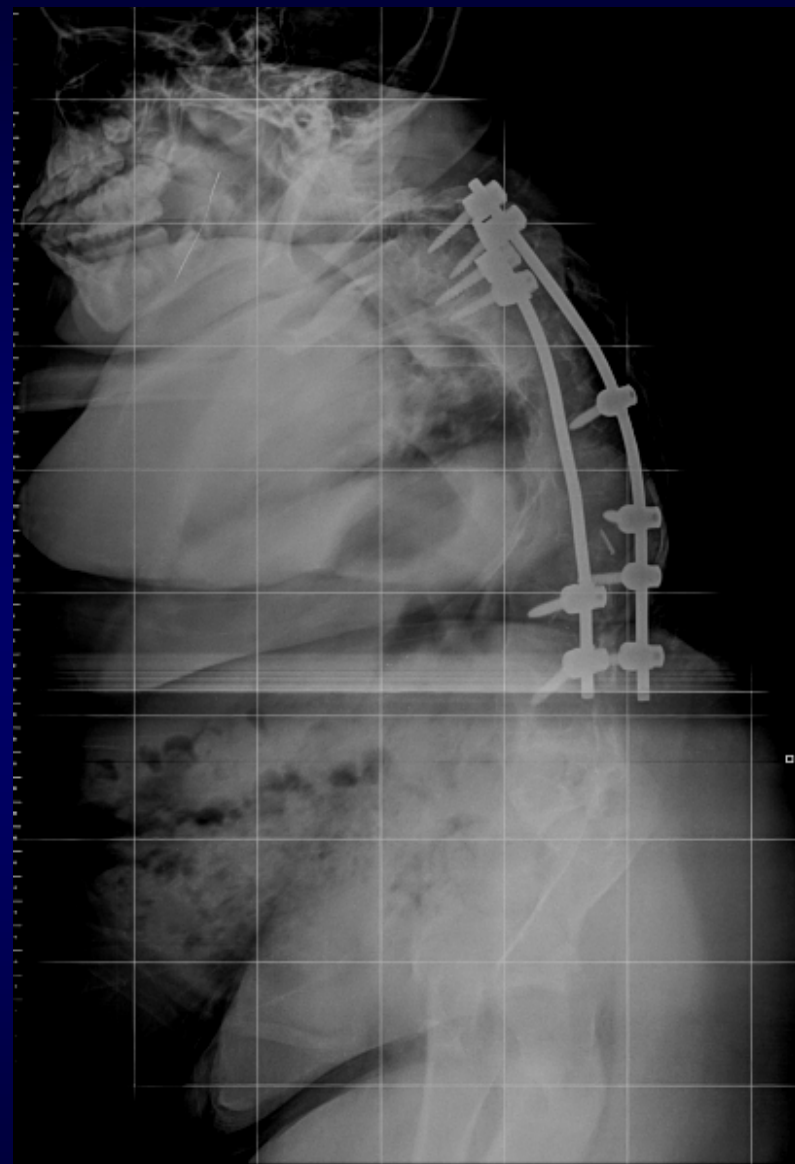
8/2013



In 35# halo traction







Factors

- Complex deformity
- VEPTR complication rates
 - >100% overall
 - infection 20% +
 - implant migration 27% +
 - spontaneous fusion 48%
- Difficult social situation

