

Tethering for Growth Modulation of the Spine – Technique



Rady
Children's
Hospital
San Diego



Peter O. Newton, MD

**Rady Children's Hospital
University of California, San Diego**



San Diego – Orthopaedics

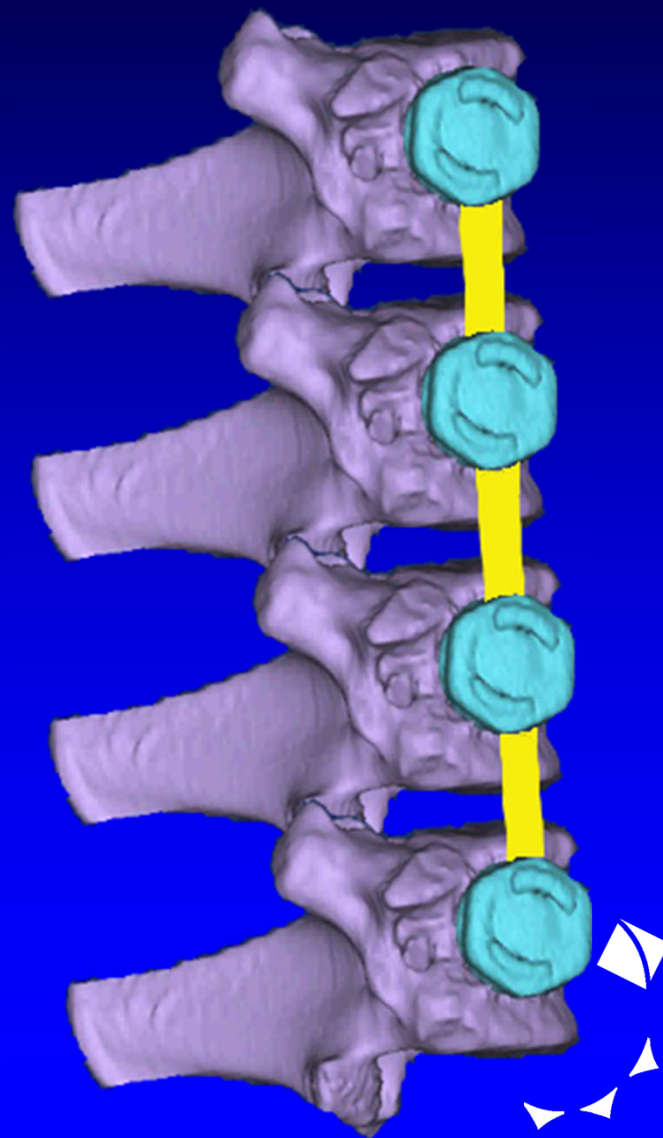
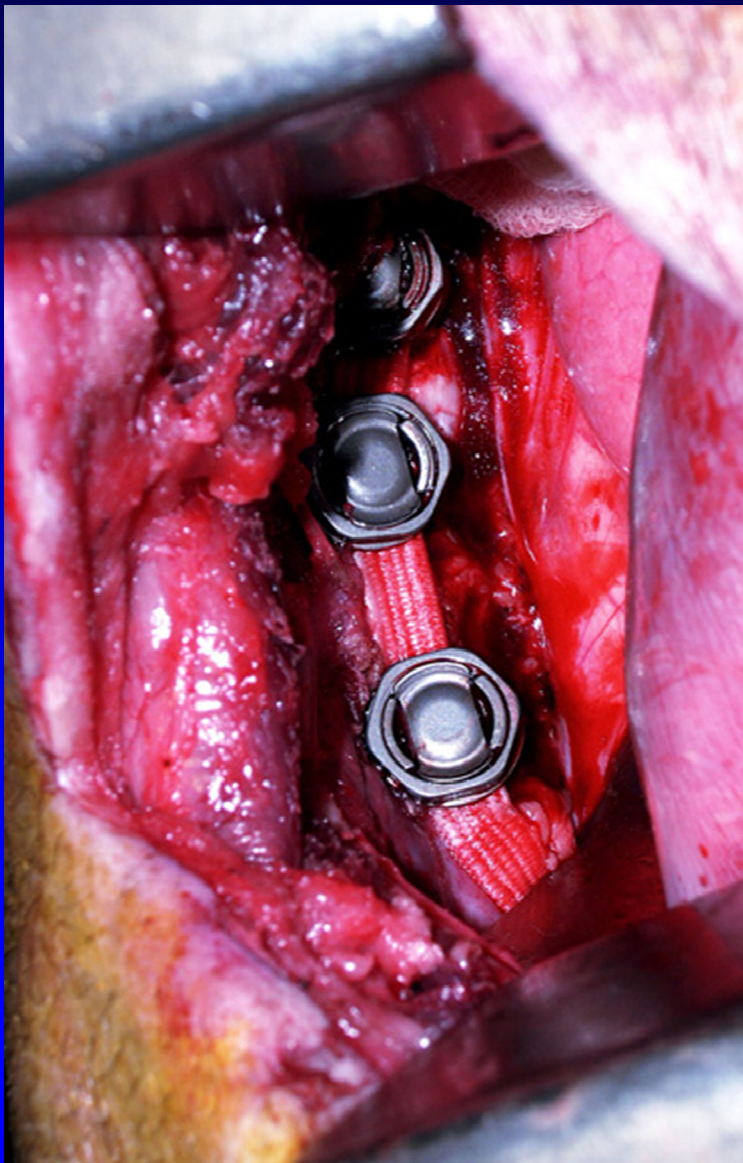


Disclosures & Acknowledgements

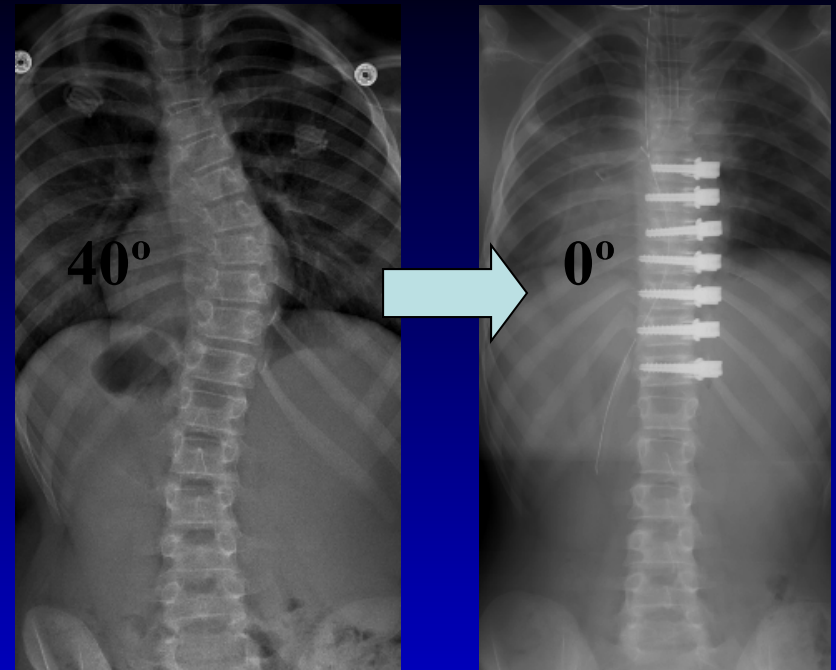
- **DePuy Spine: Royalties, Consultant, Research support, IP (tether)**
- **EOS Biospace: Research**
- **OREF, POSNA, SRS, CSF: Research support**



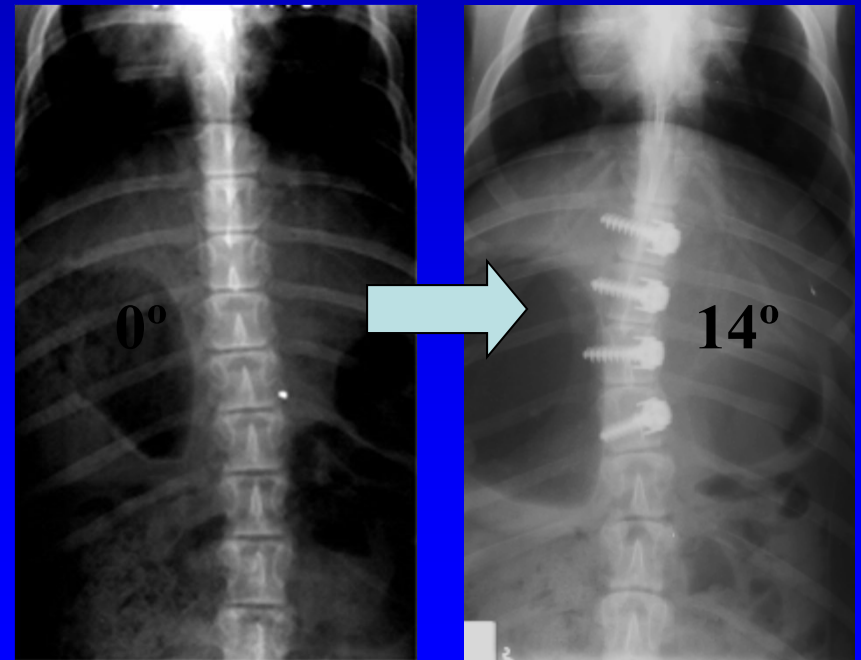
Anterior Spinal Tethering



Clinical Application

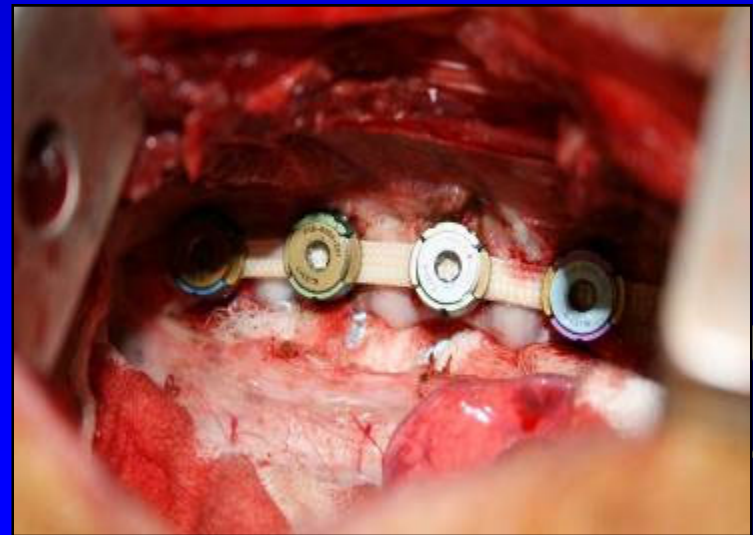
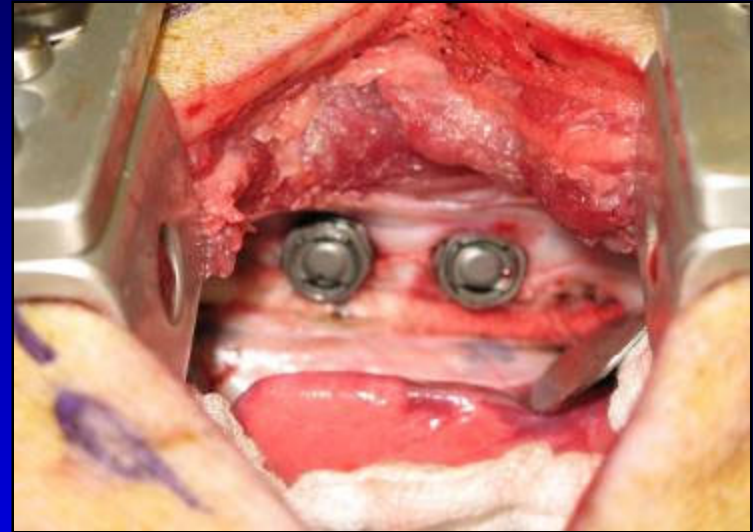


Experimental Application



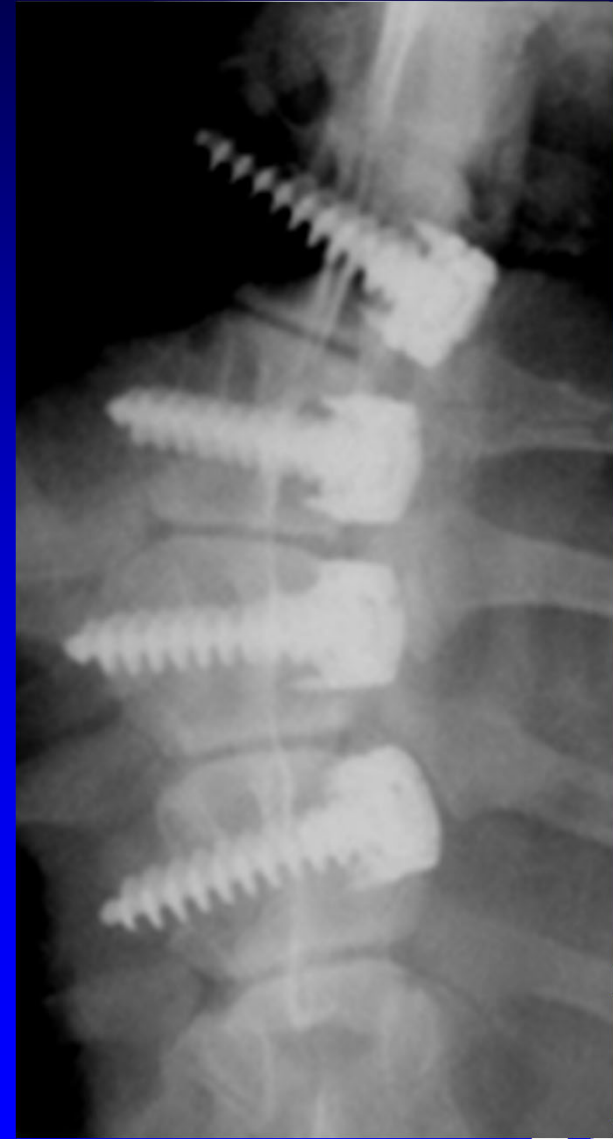Control vs. Tether Groups

- **Control group (n=6):**
 - Sham surgery with only screws
- **Tether group (n=6):**
 - Tapered screw-staple design with a UHMWPE ribbon
- **6-month survival**



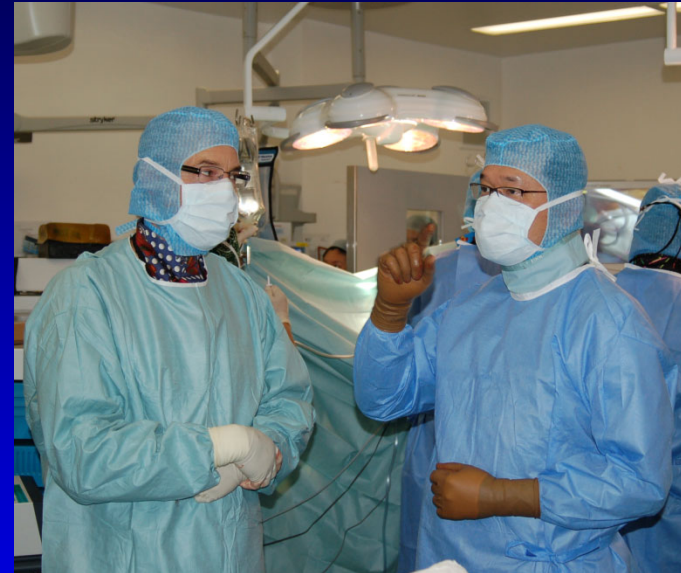
Conclusions


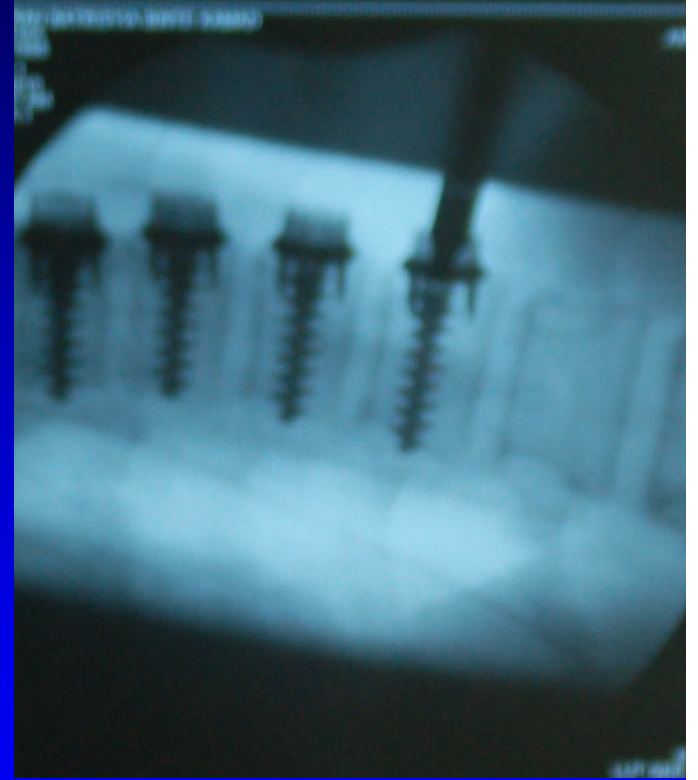
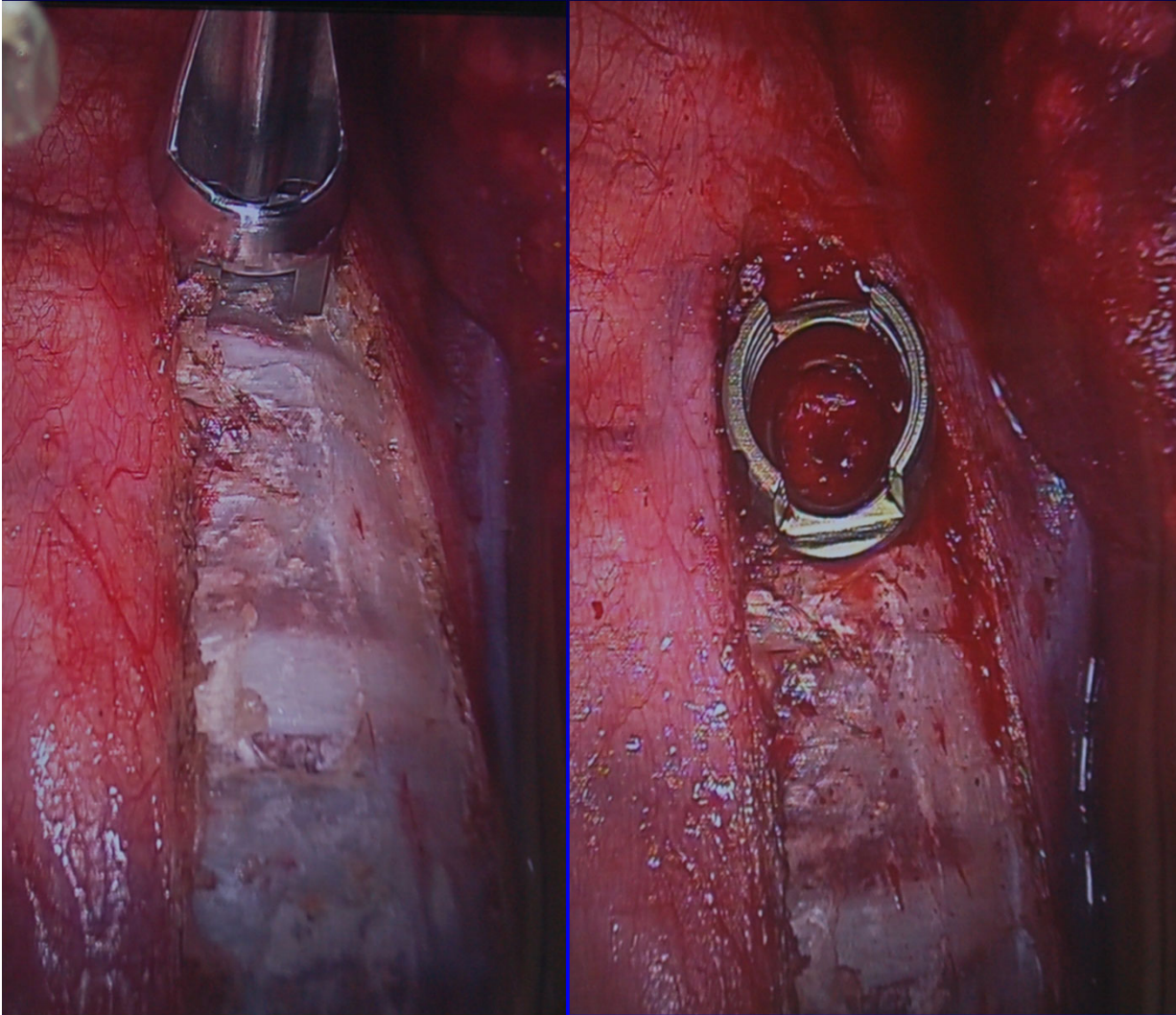
- **Consistent growth modulation**
- **Discs seem OK**
- **Might work in humans...**

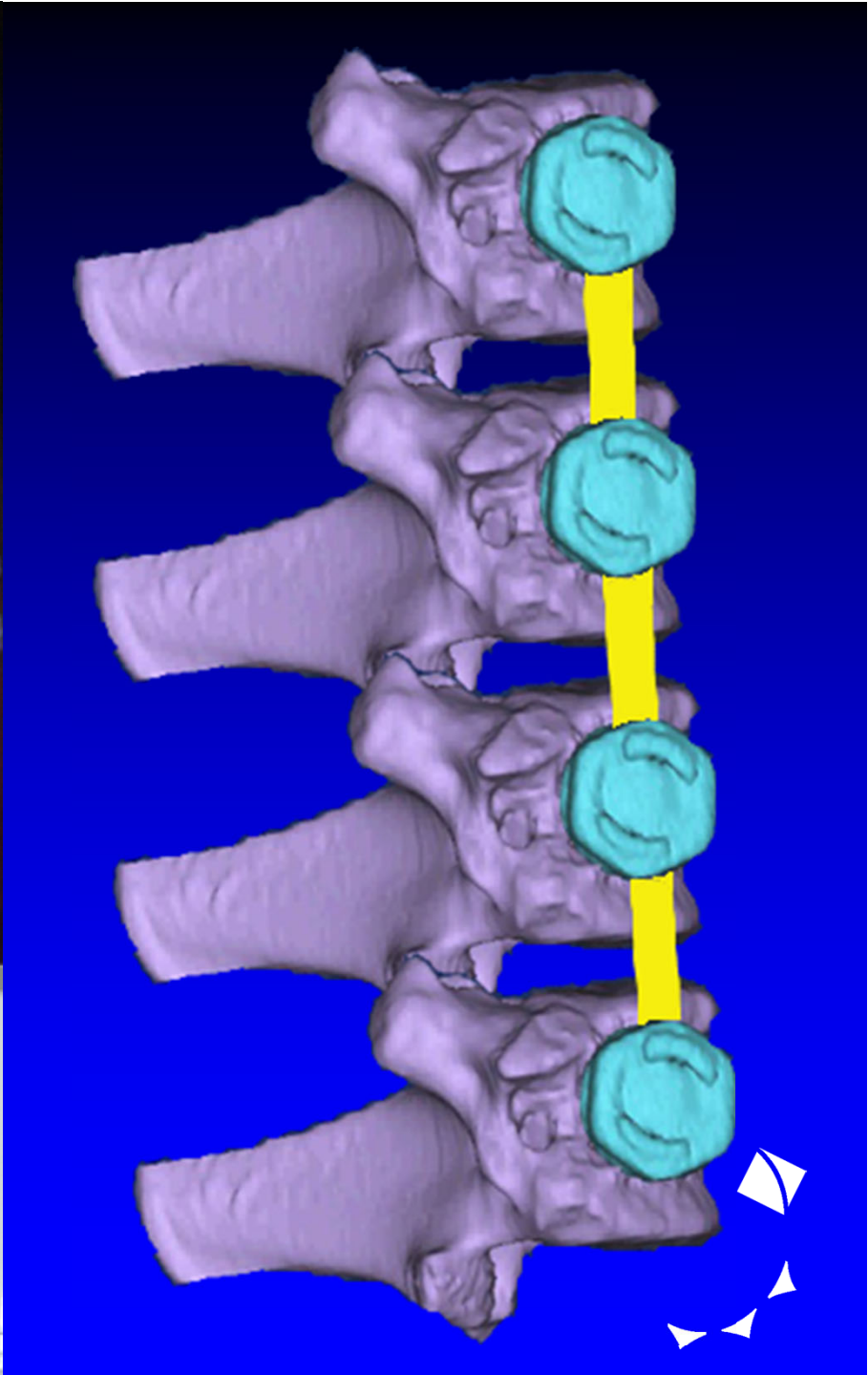
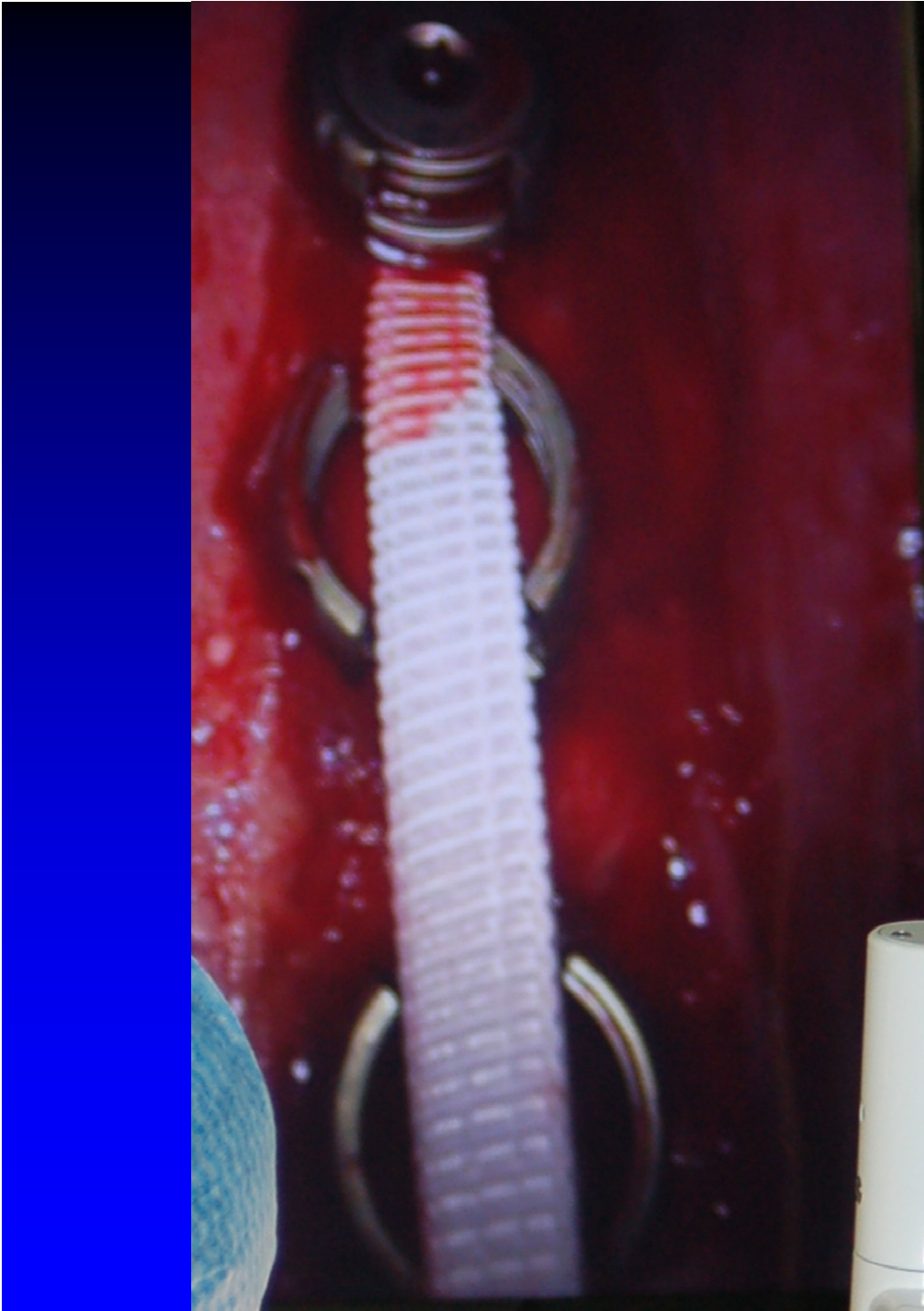

Singapore Trial – Hee Kit Wong

- **Male and female**
- **8 to 15 years of age**
- **juvenile or adolescent idiopathic scoliosis**
- **Major thoracic curve of 35° to 55° who are at high risk for progression**
- **At least three years of estimated growth remaining based on hand/wrist radiograph assessment of bone age (less than or equal to 13 for girls, less than or equal to 13 for boys.)**

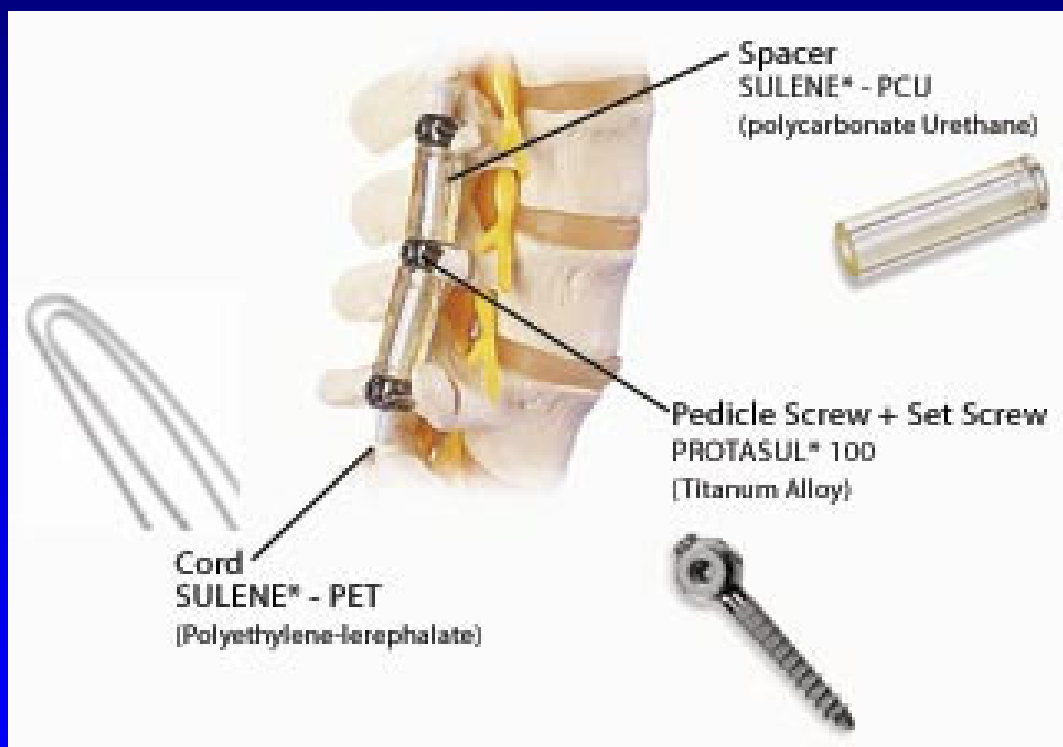







Off Label Anterior Tethering

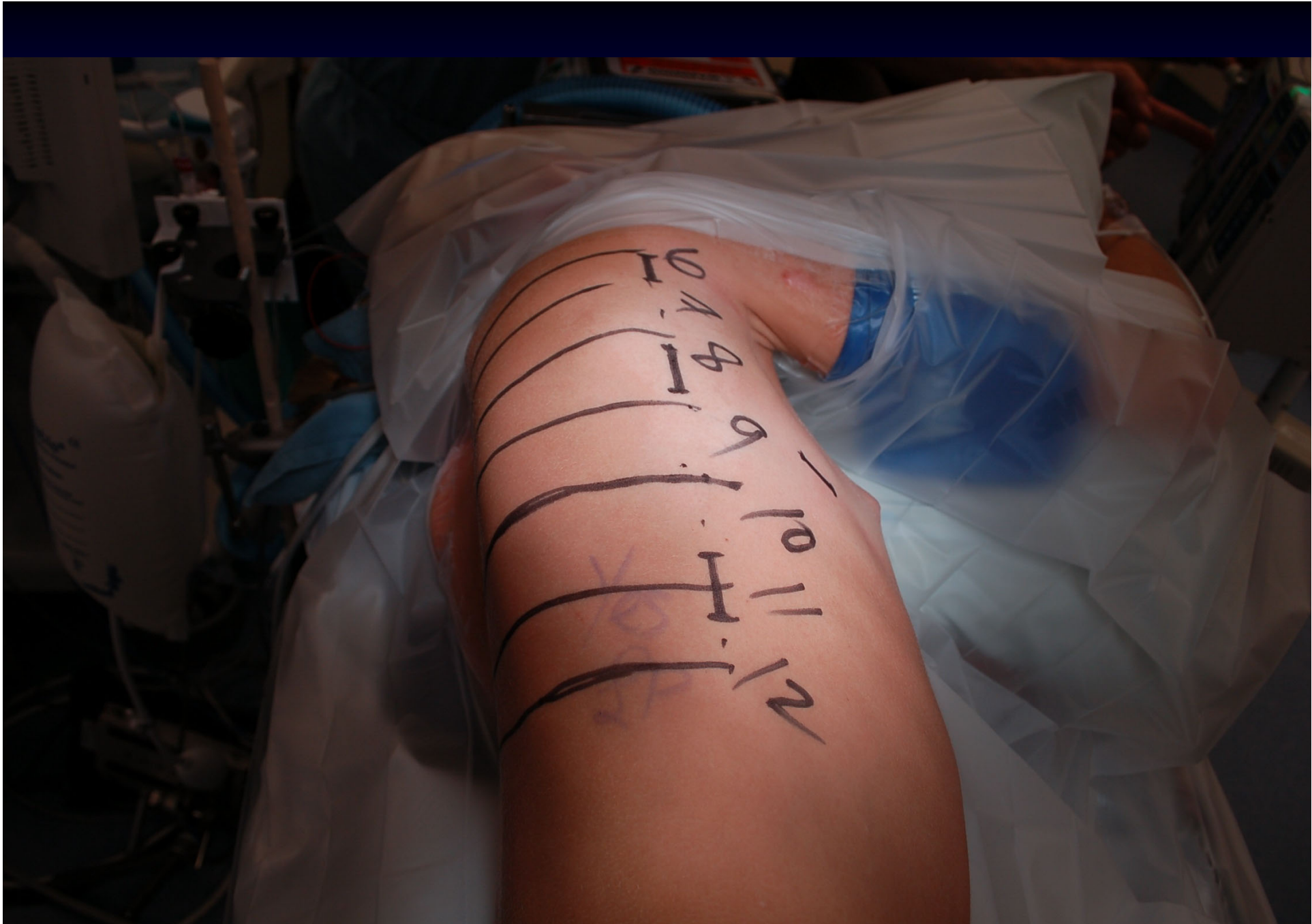- **Dynesys components**
- **Thoracoscopic**
- **Early results promising**



Indications


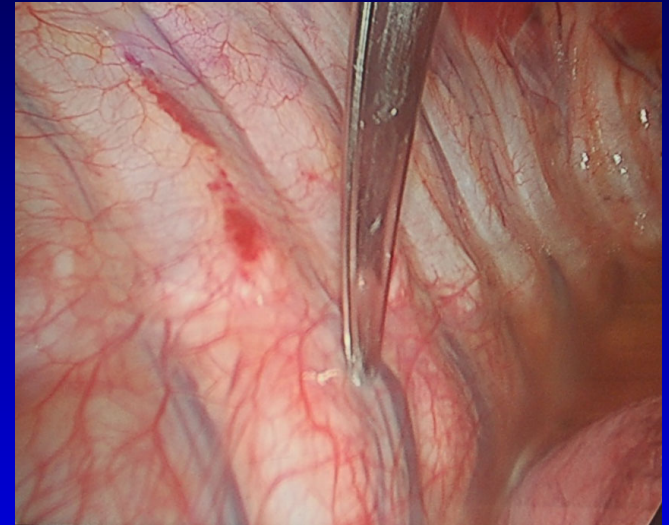
- **Juvenile or young Adolescent Idiopathic Scoliosis**
- **Risser 0, Open Triradiate cartilage preferred**
- **Thoracic curves $>45-50$, <65**
- **Flexible upper thoracic, lumbar curves**

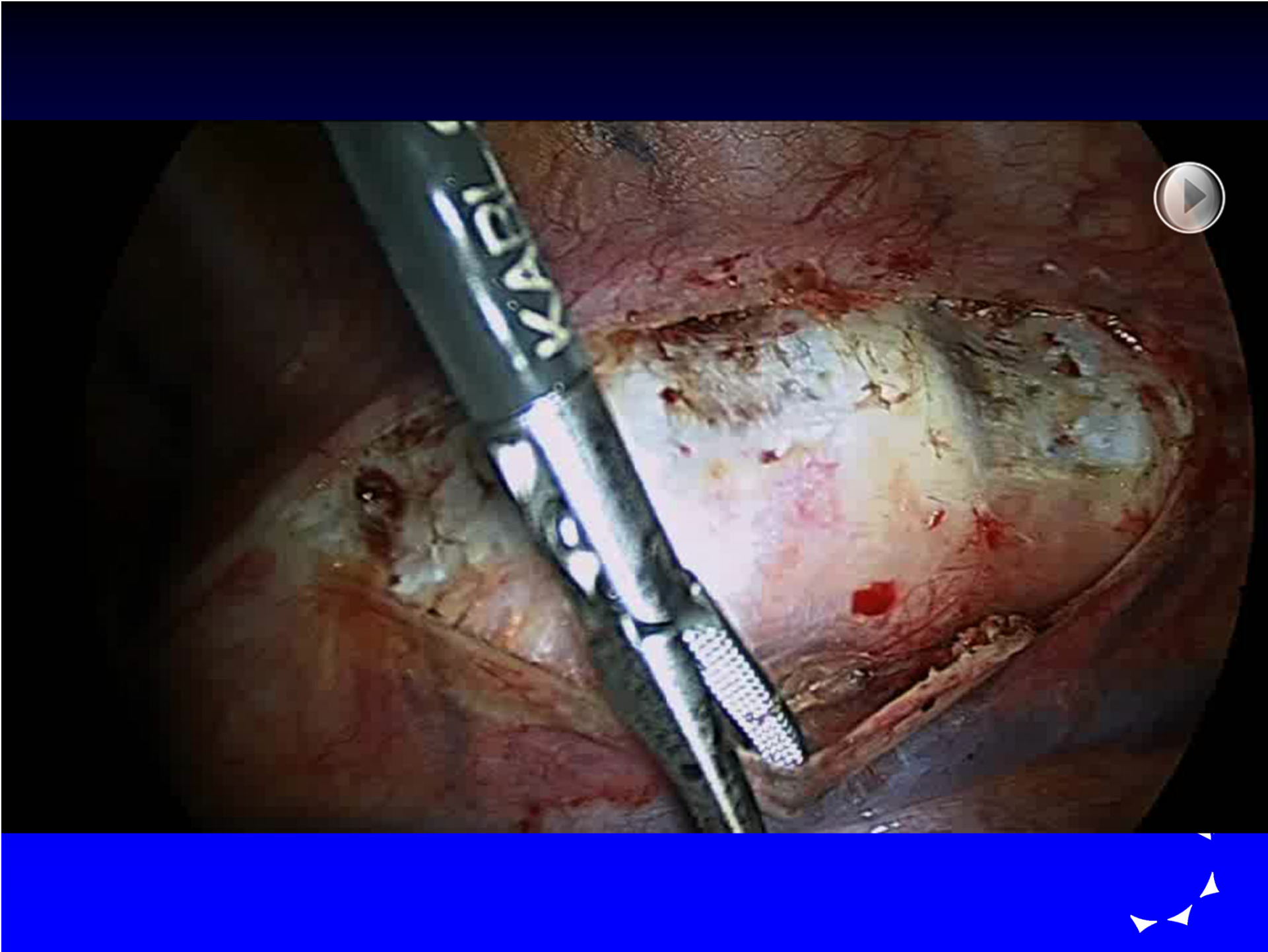


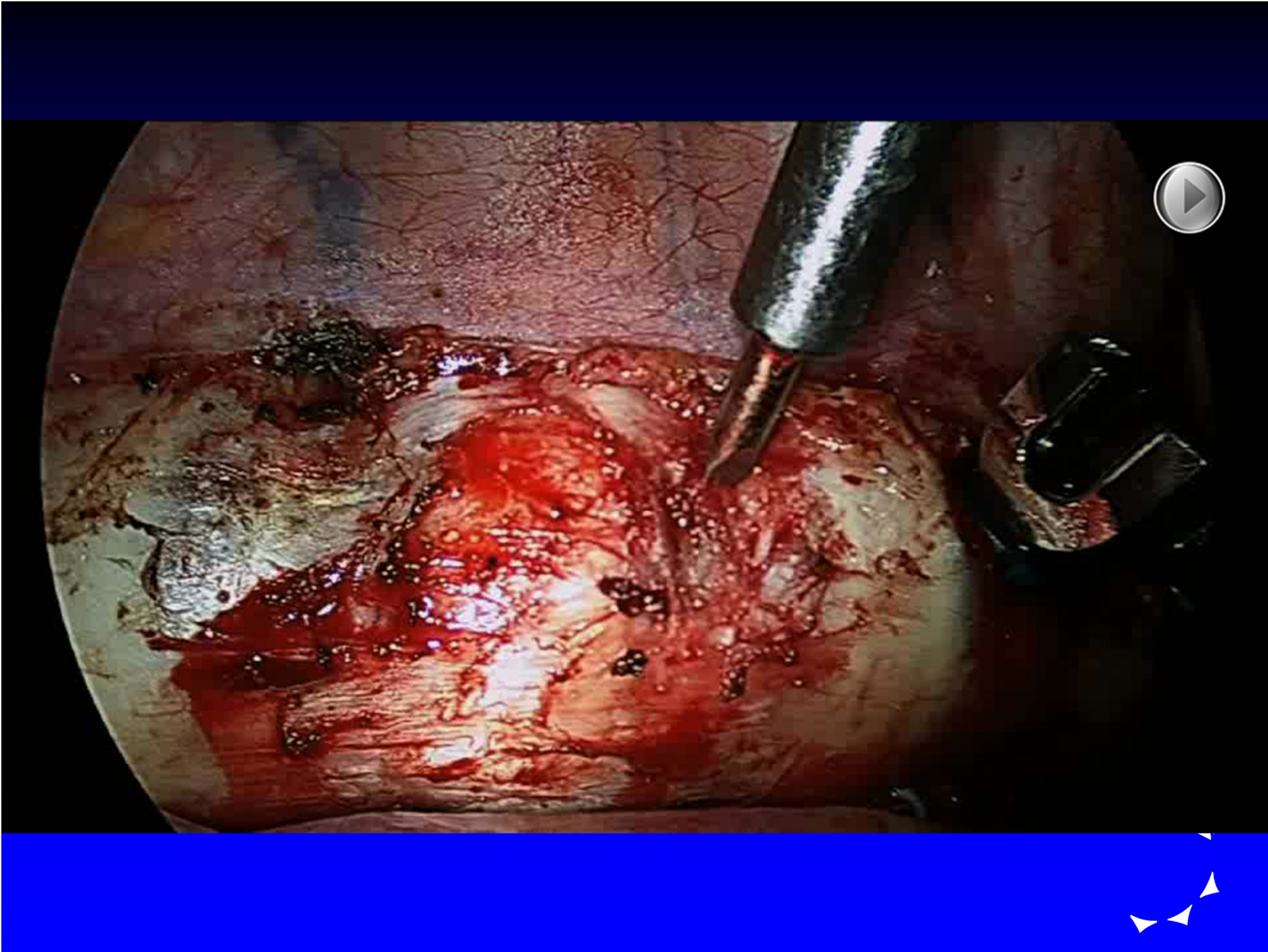


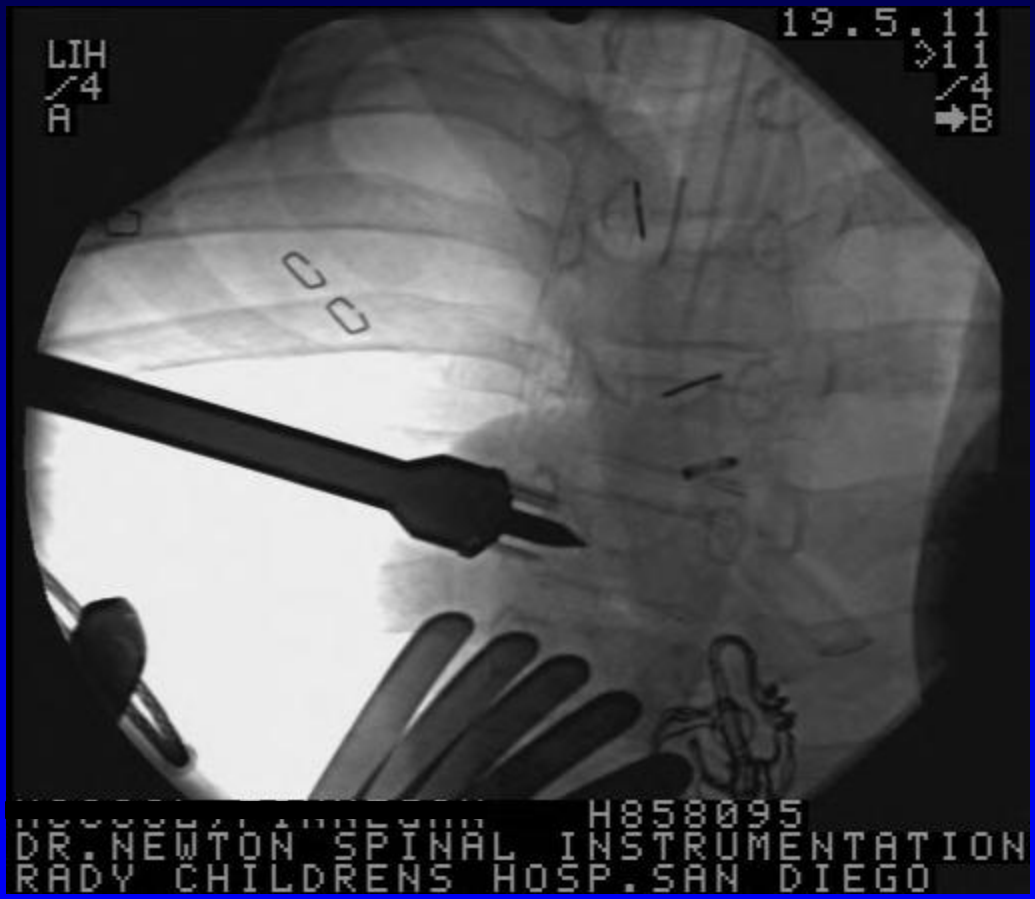
Thoracoscopic Approach

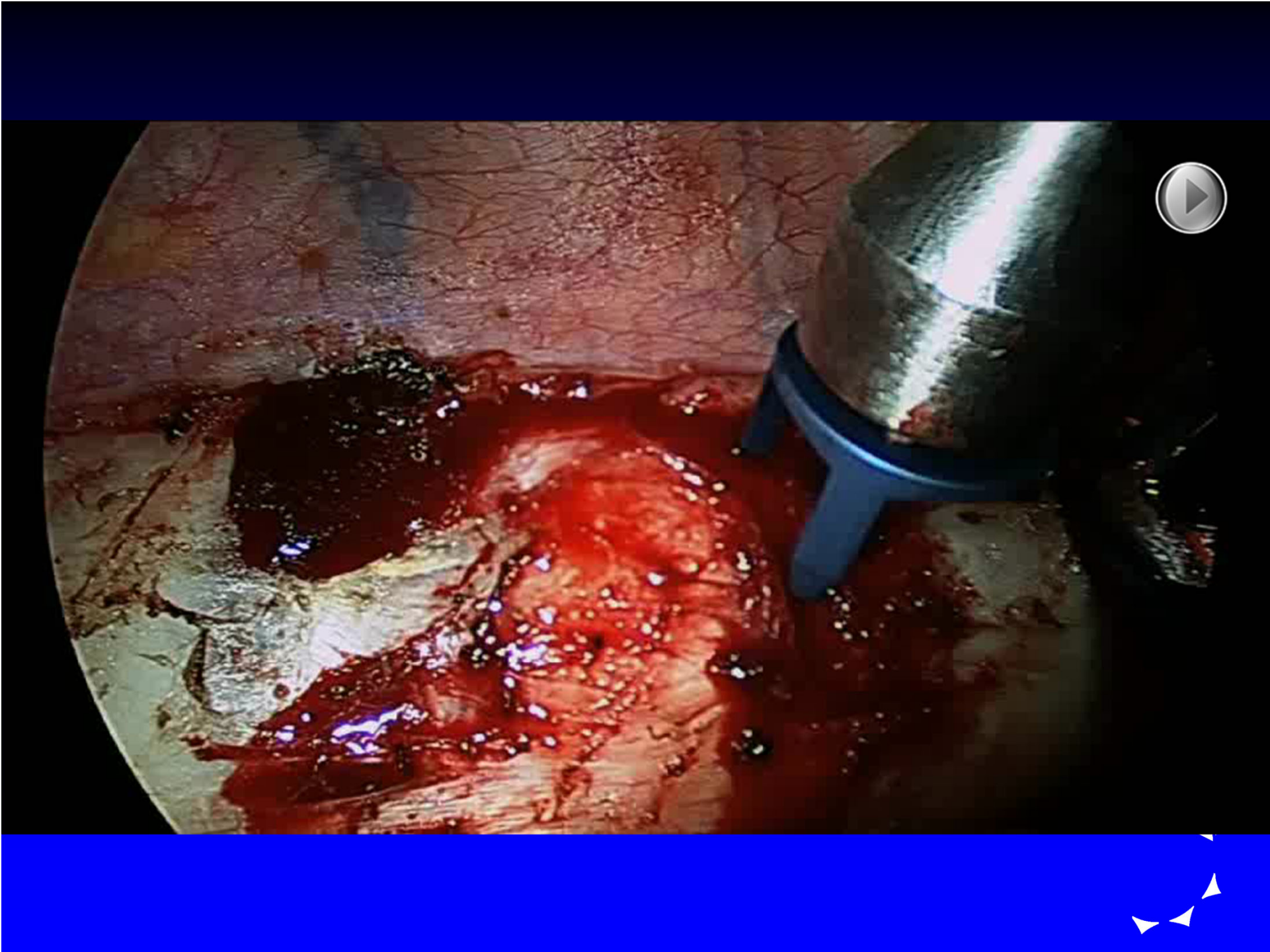- **Single lung ventilation**
- **4 incisions (15mm)**
- **Divide segmental vessels**
- **Vertebral pronged staple & screw**
- **Tension the tether**


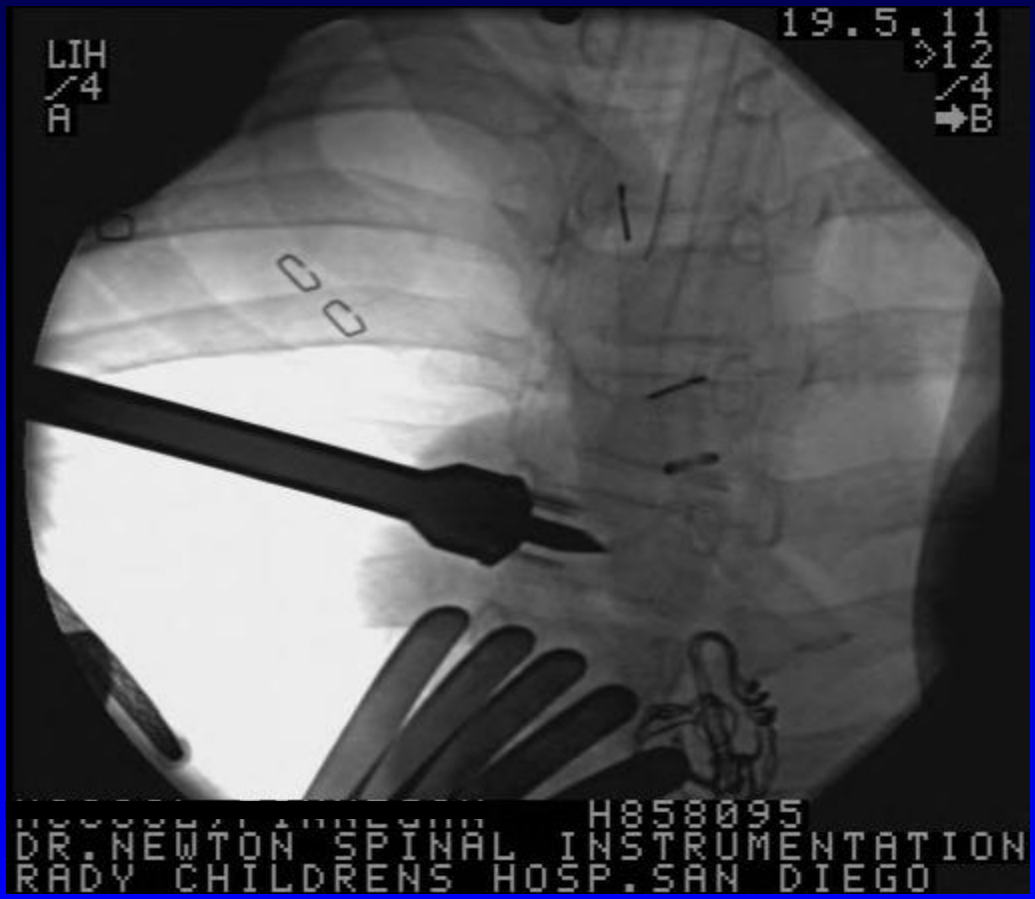


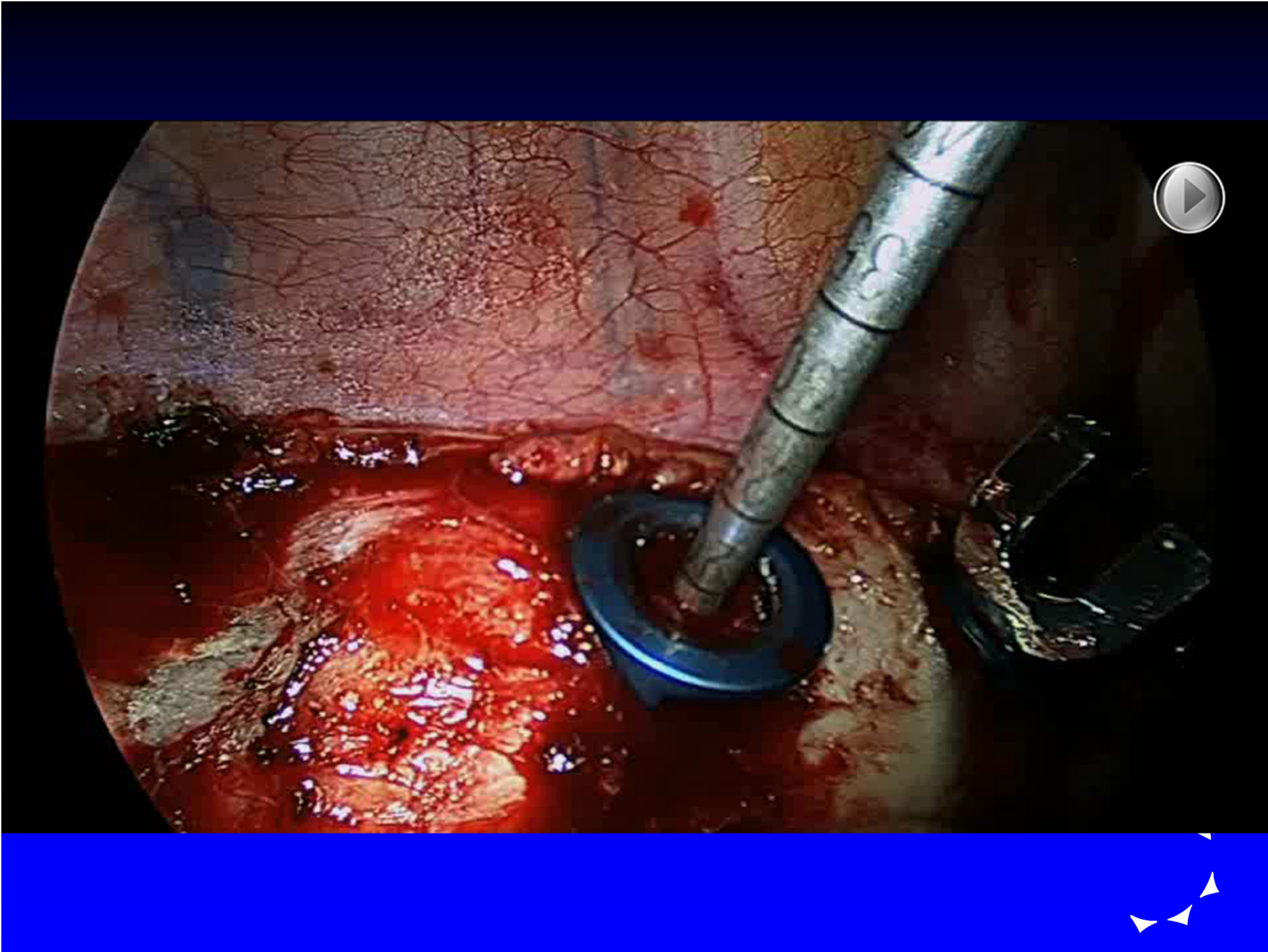



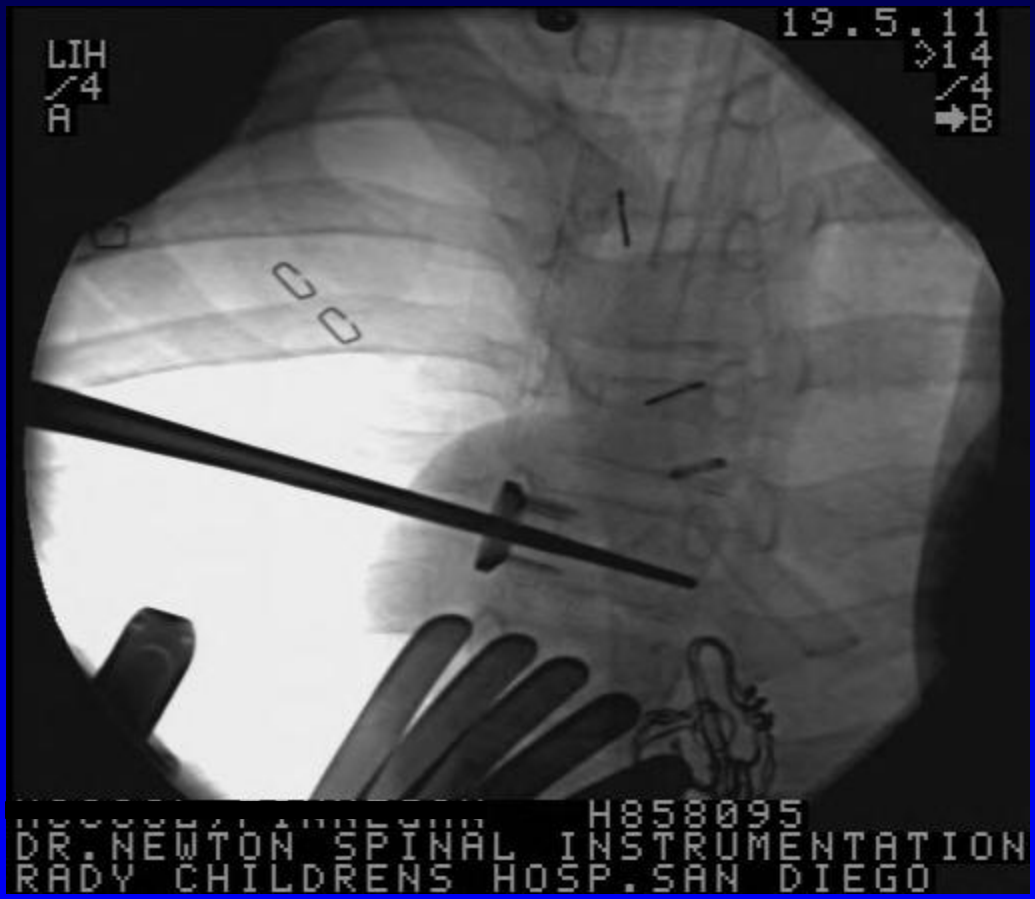
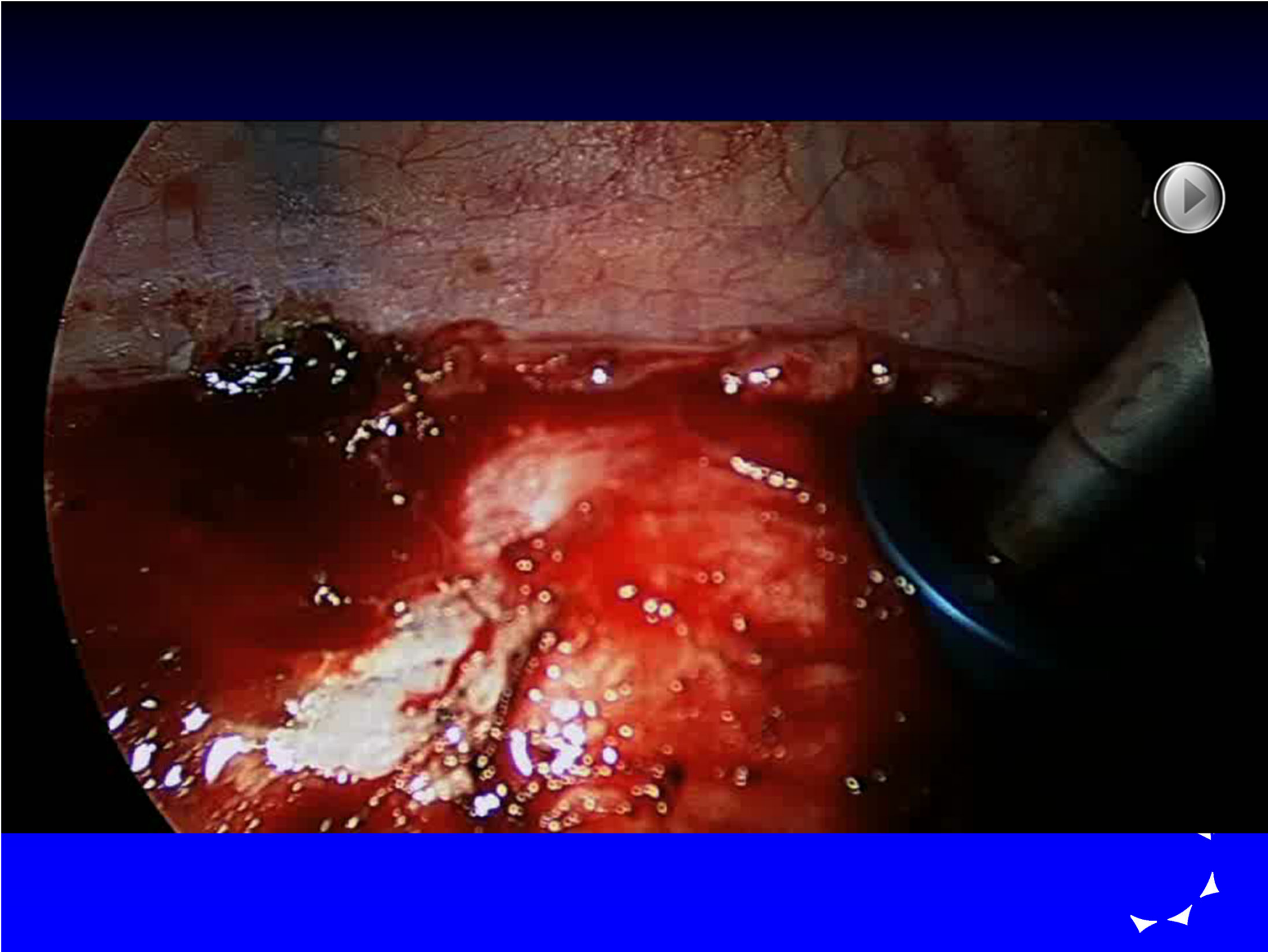




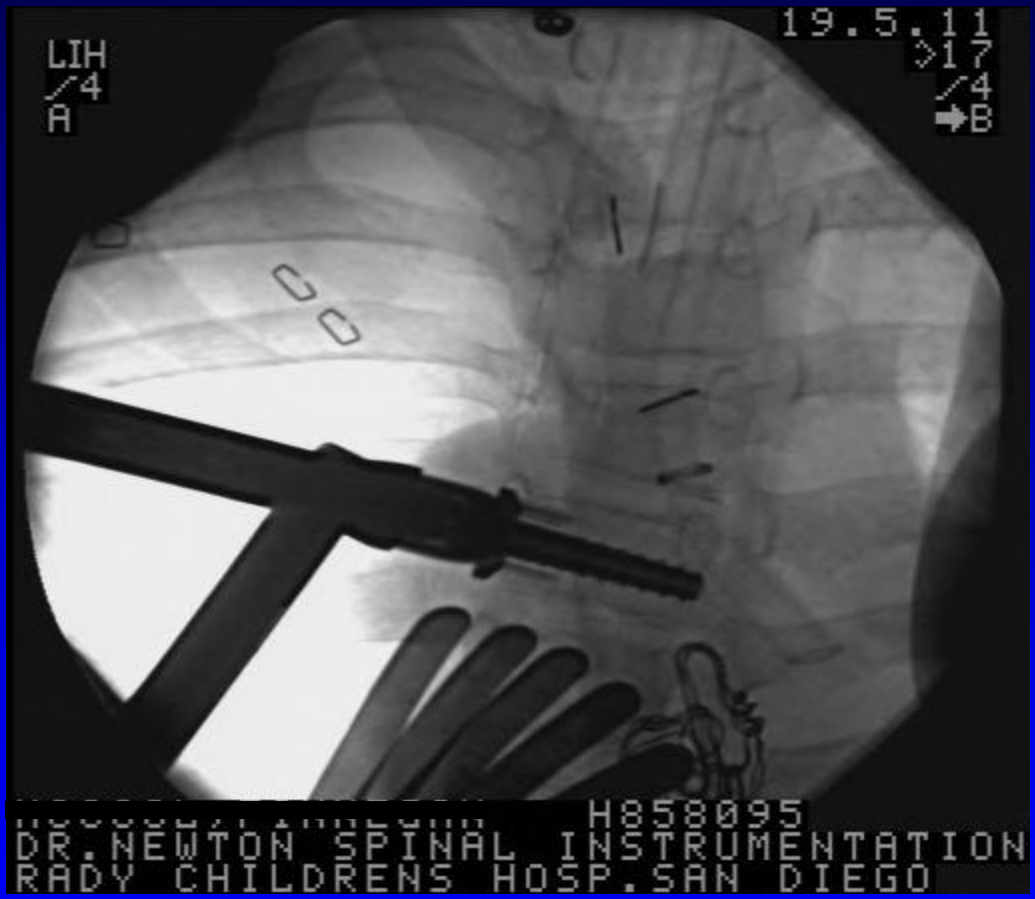



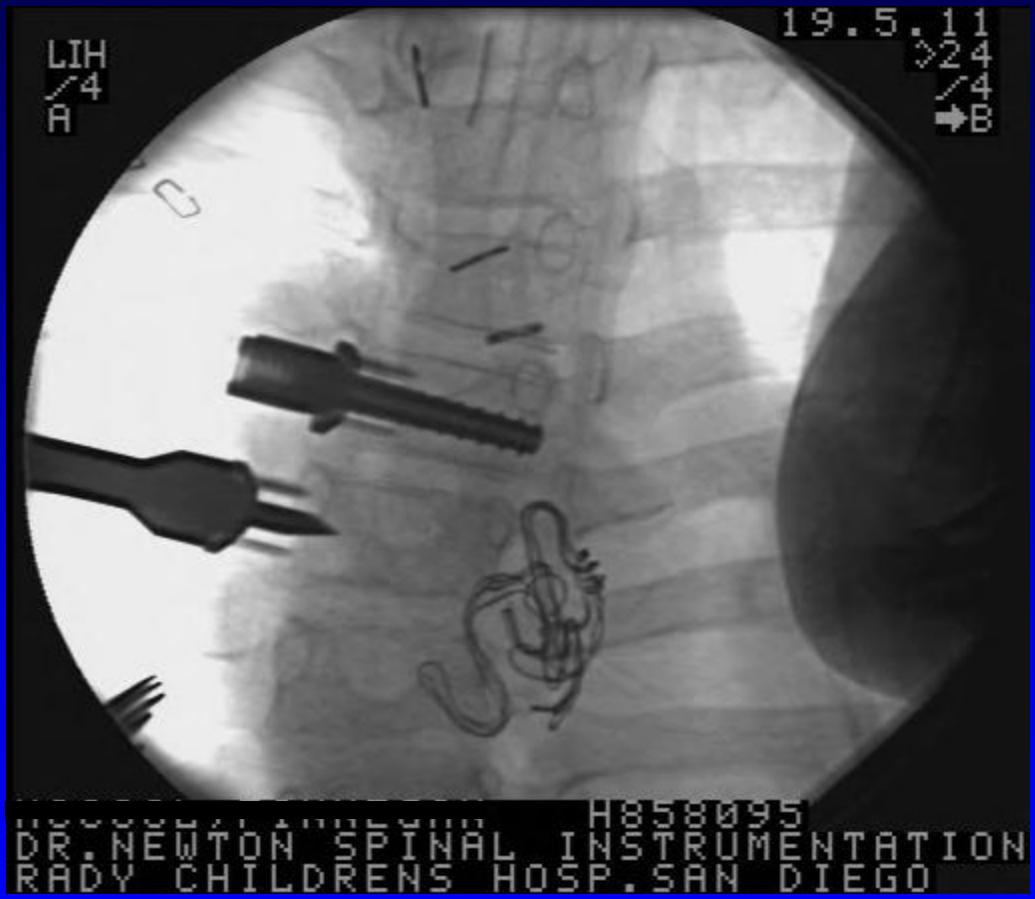



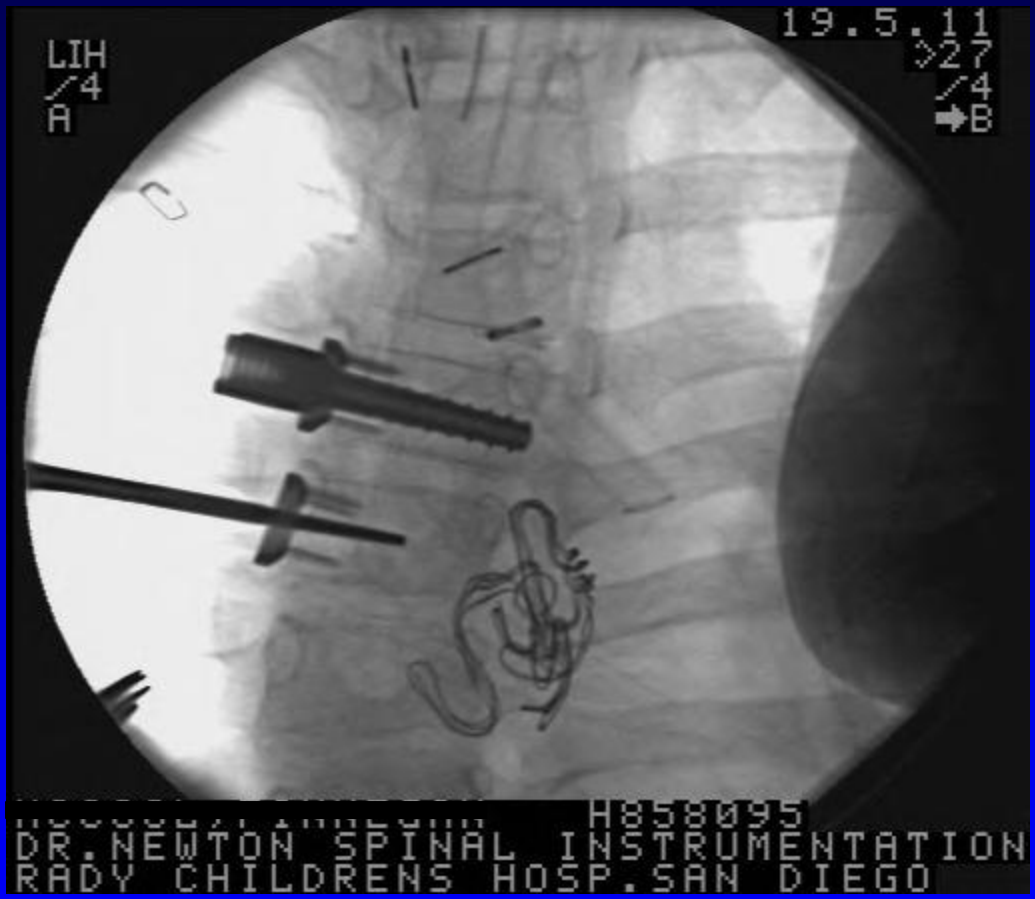



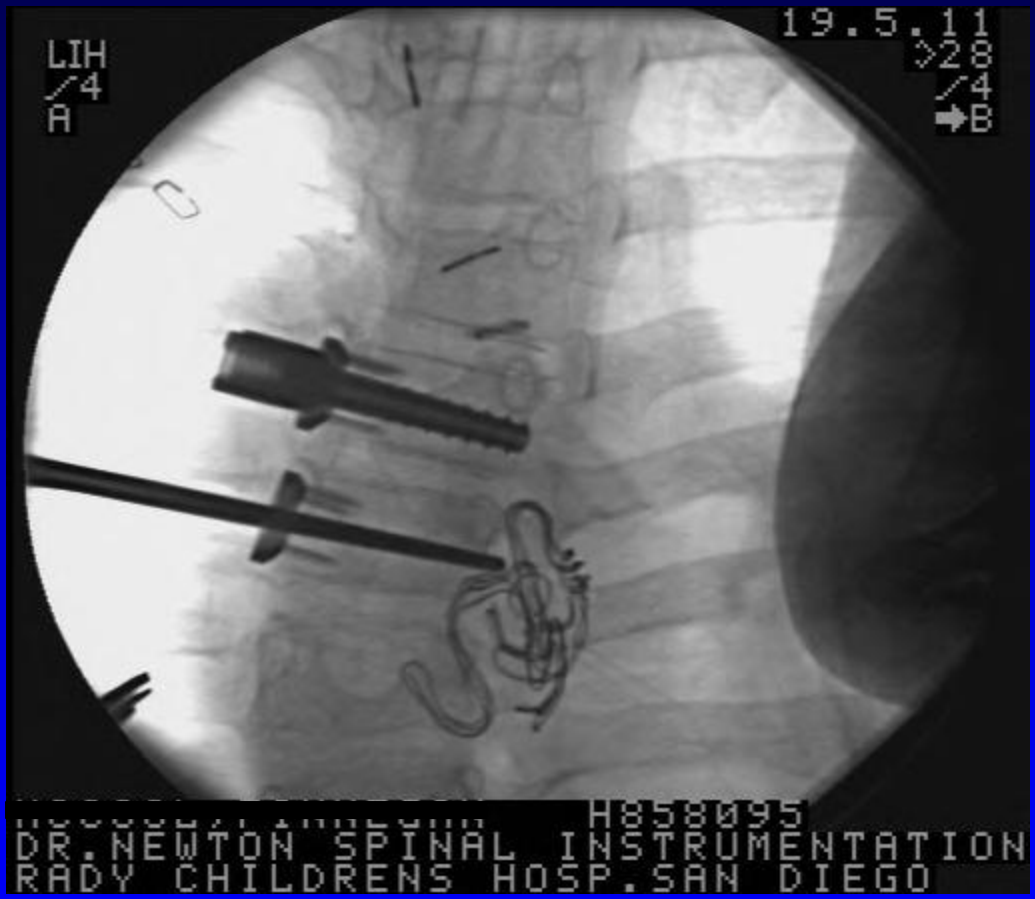



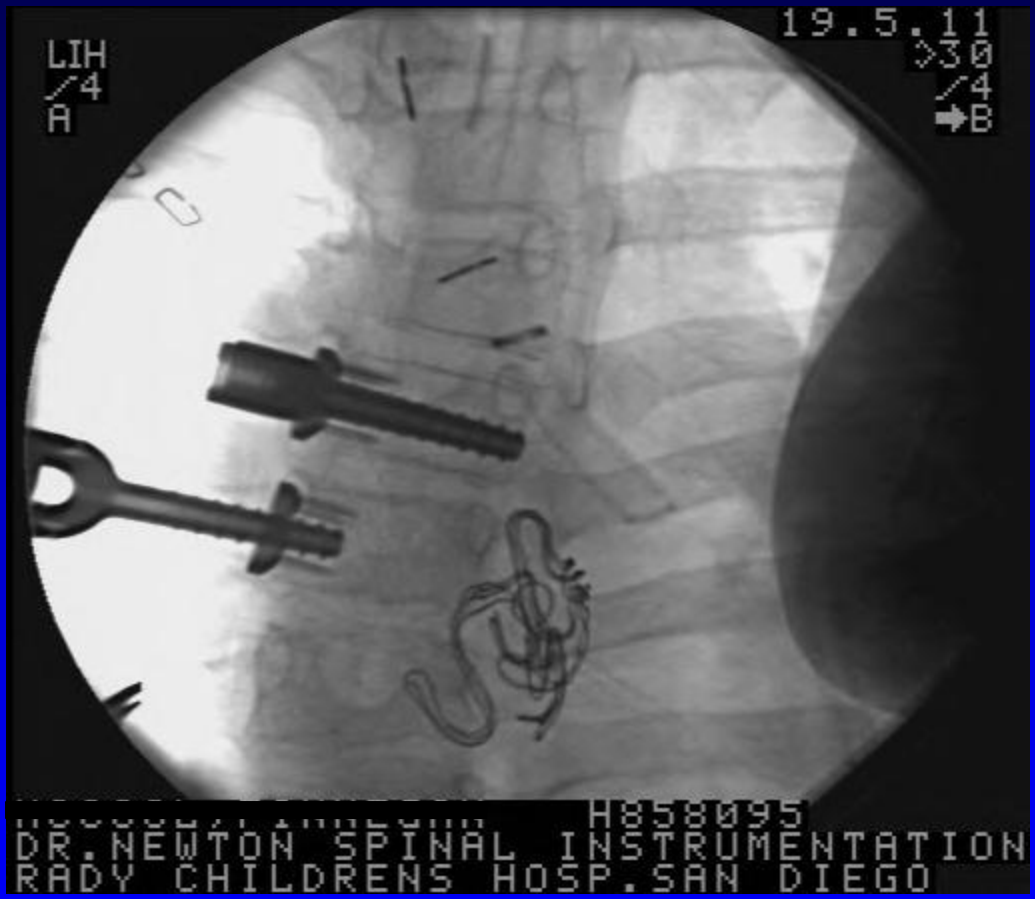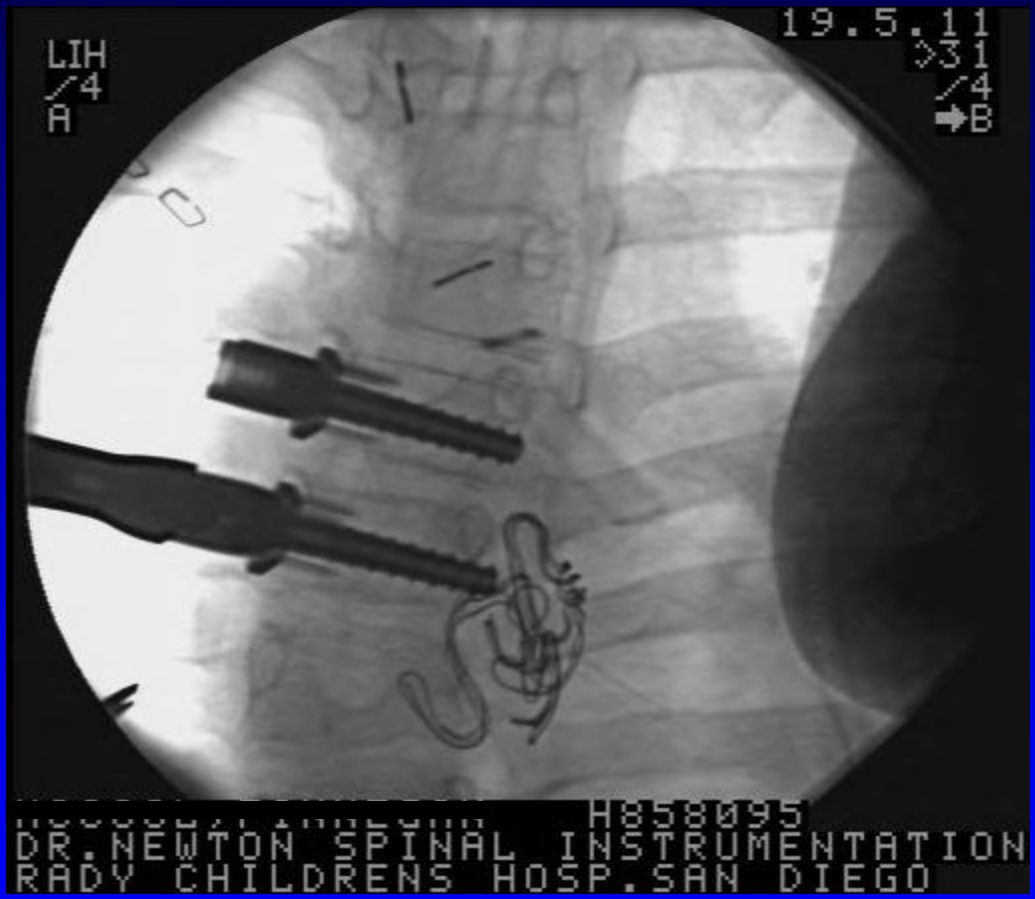






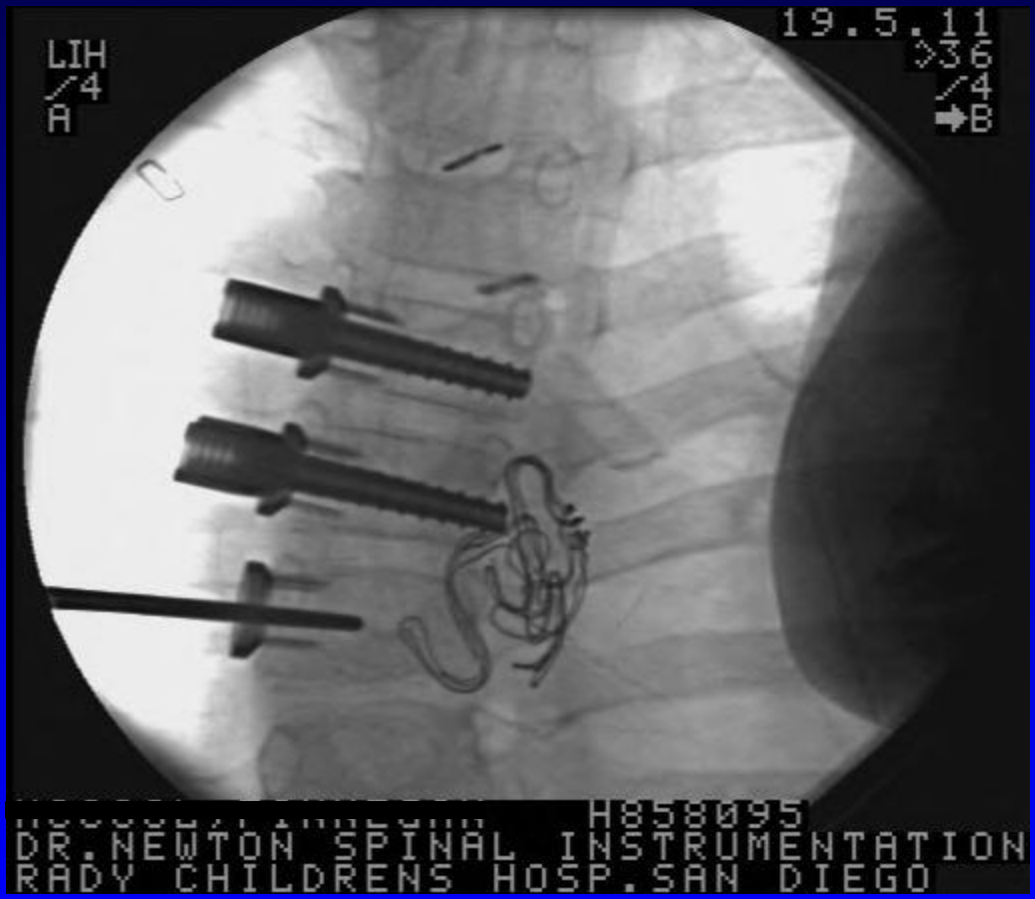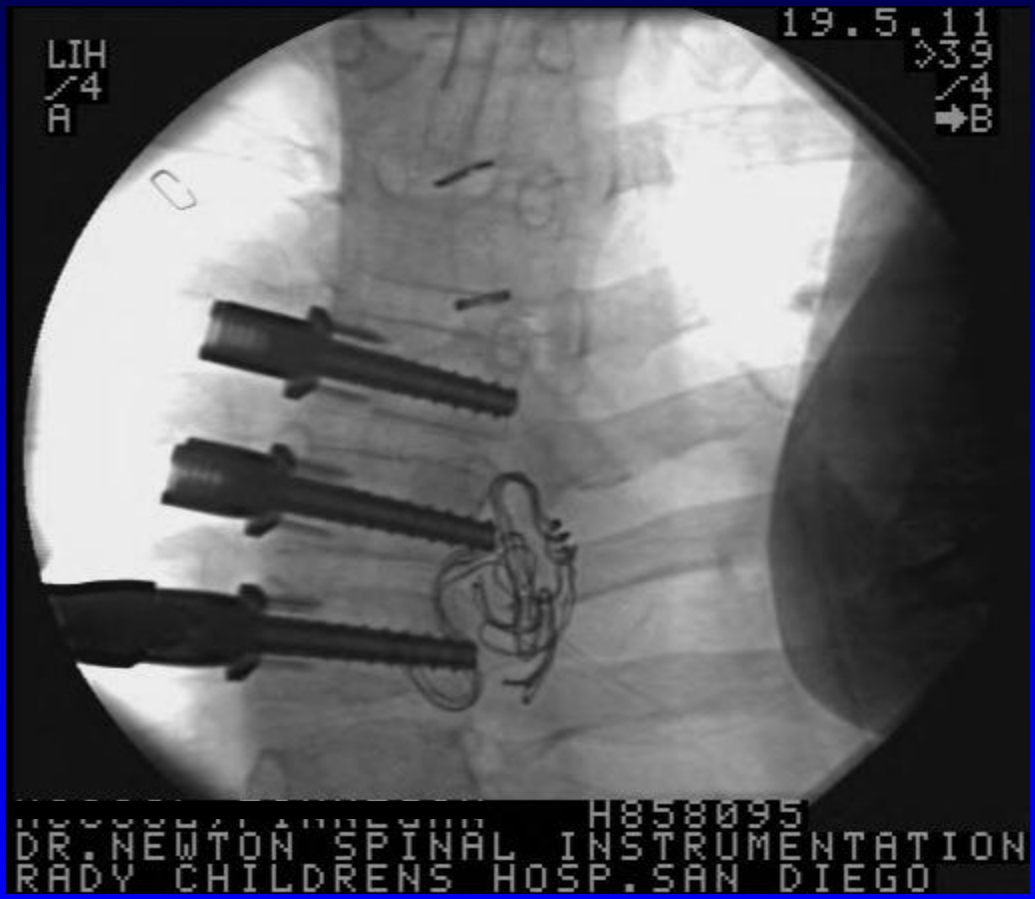





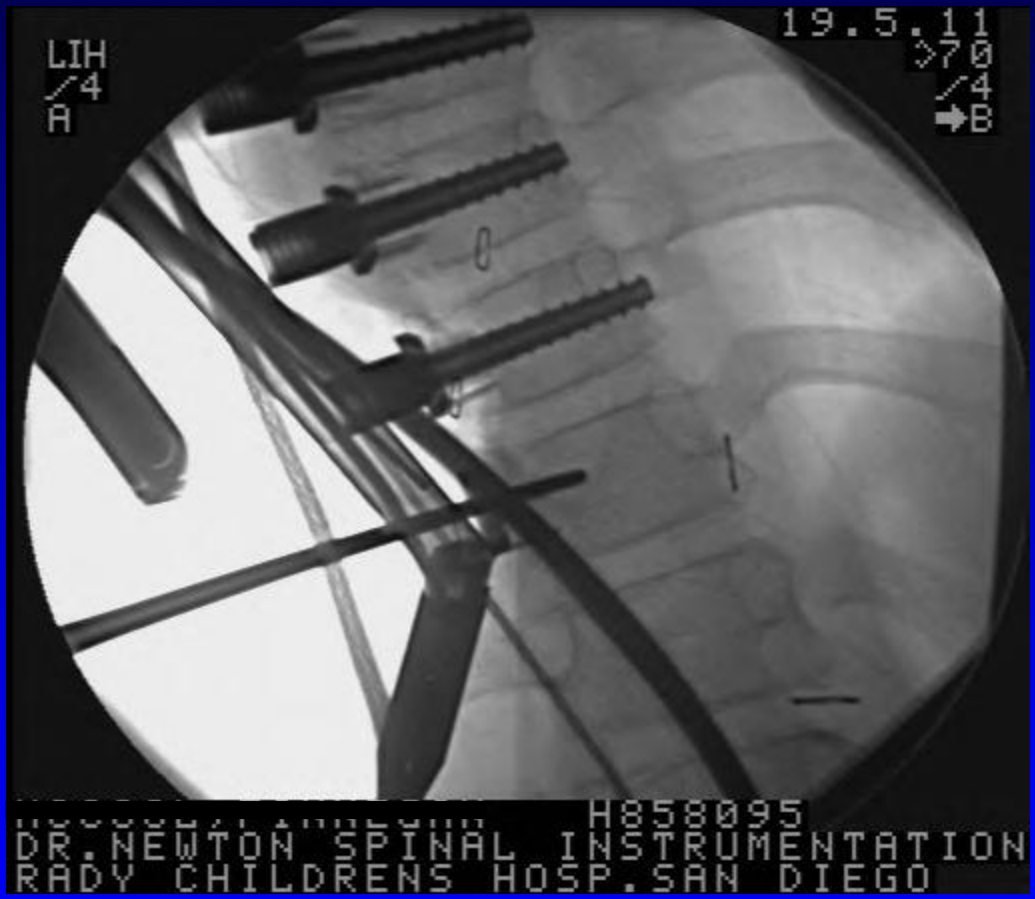



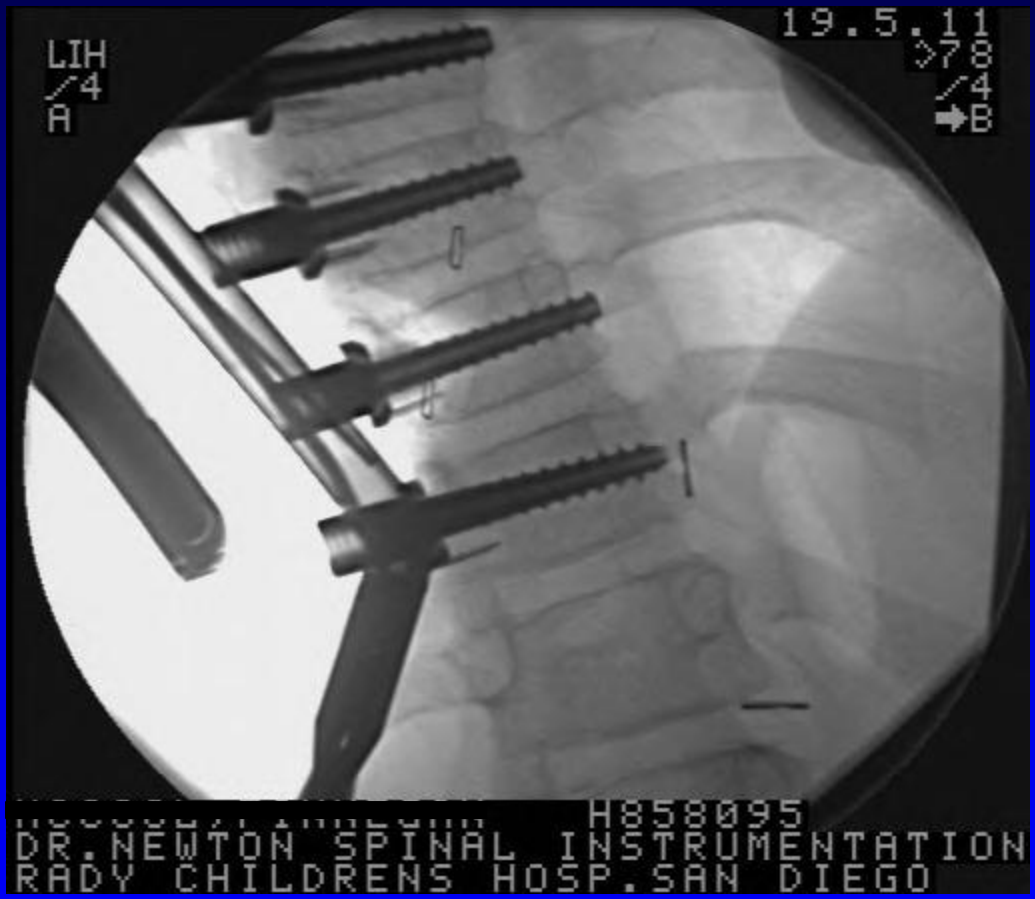


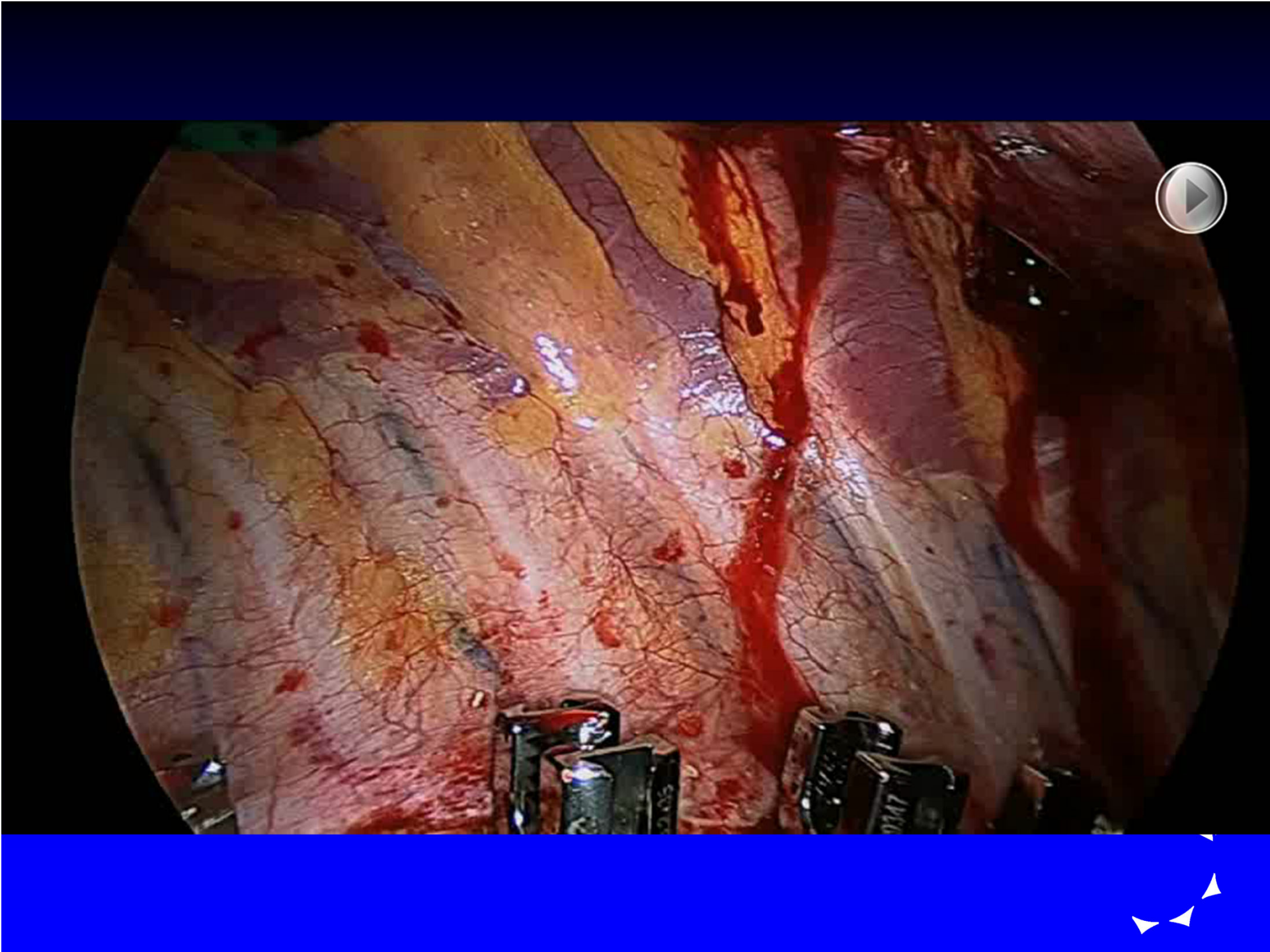


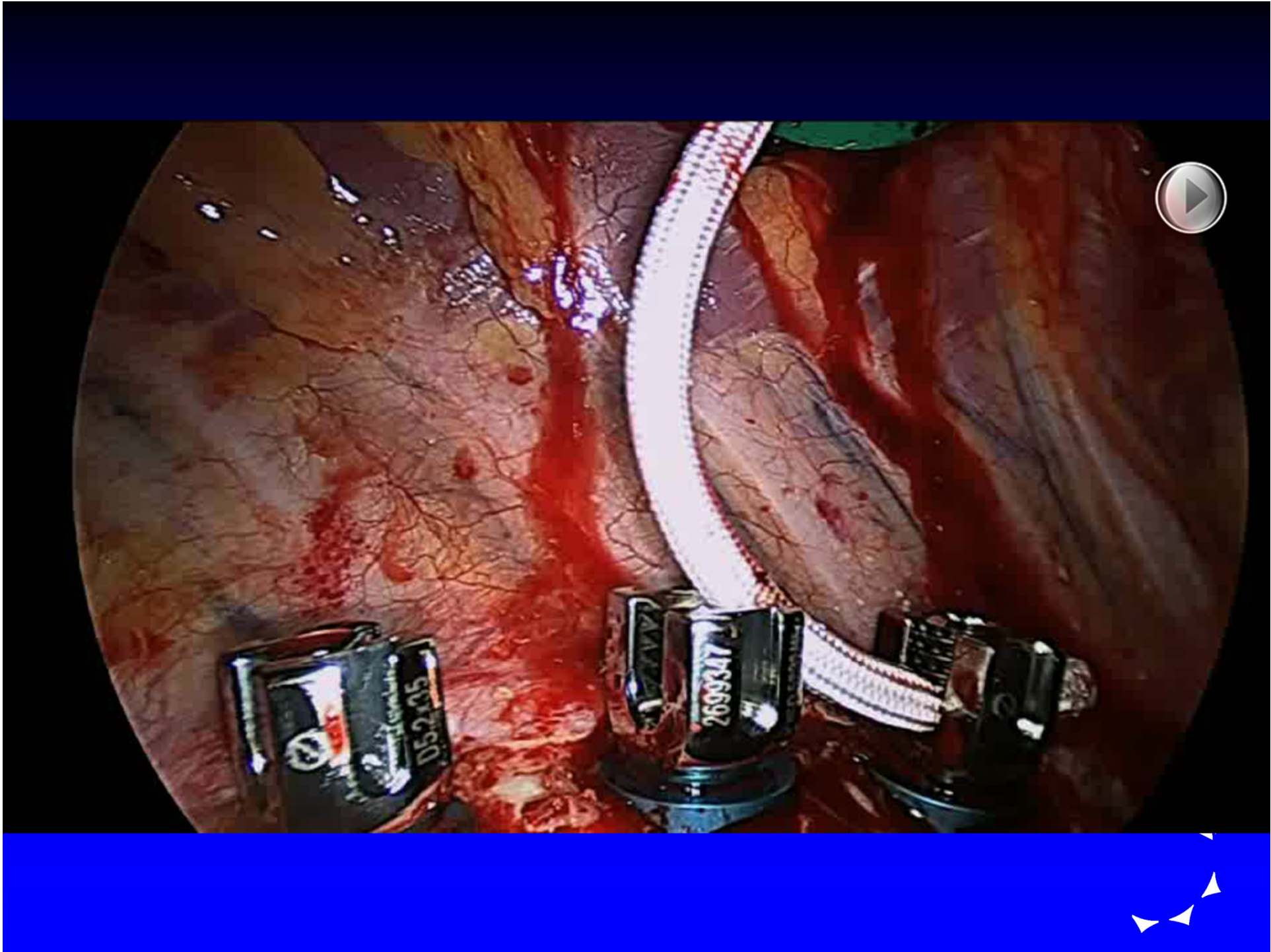


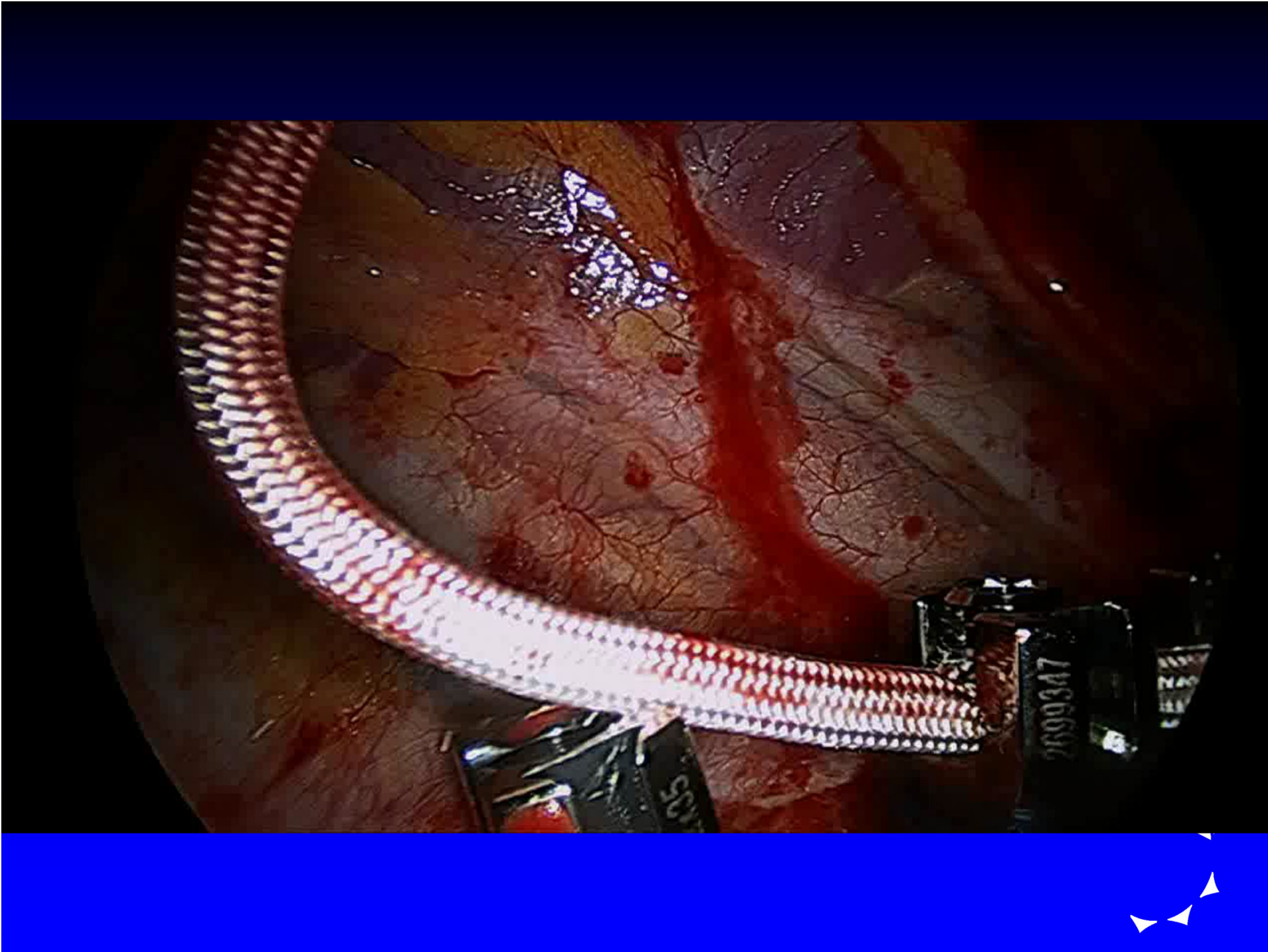






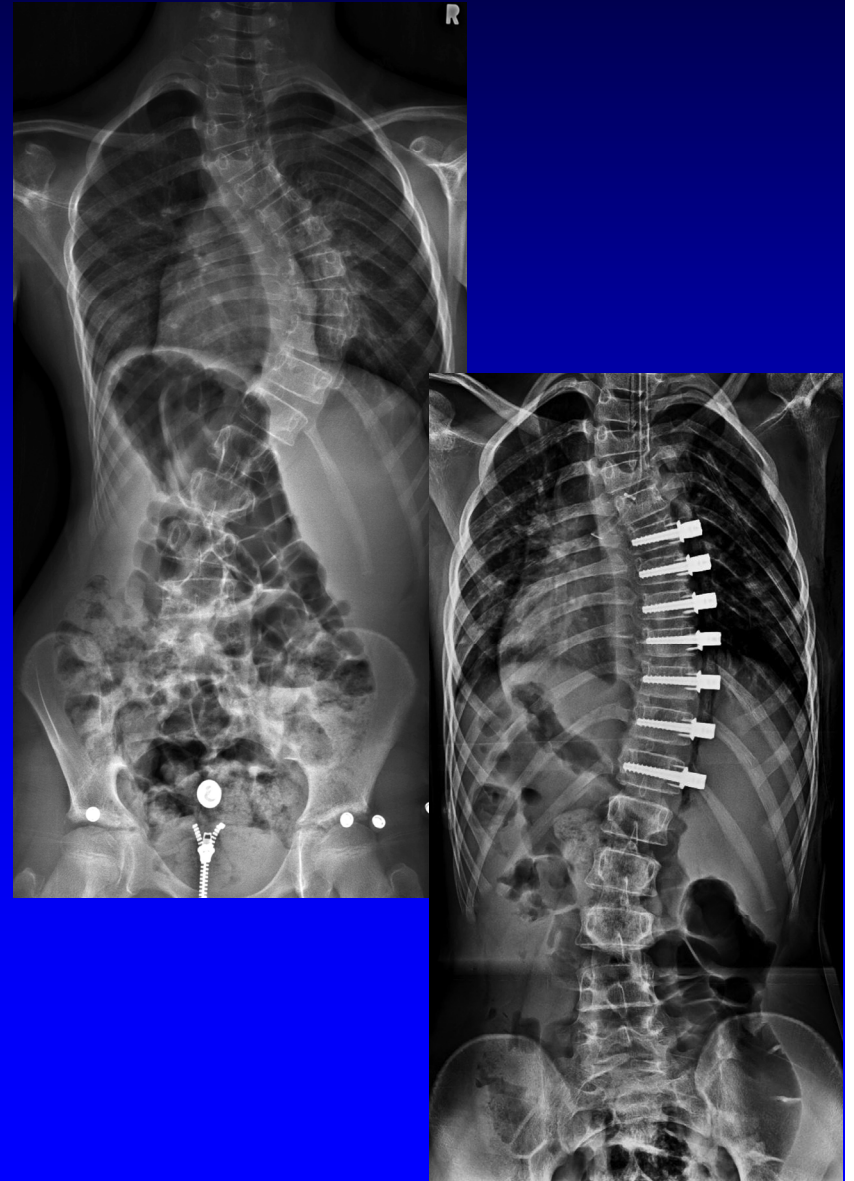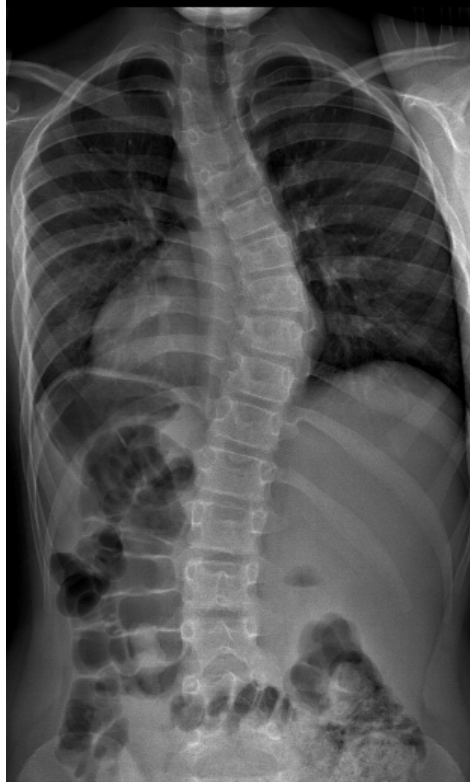






Tensioning

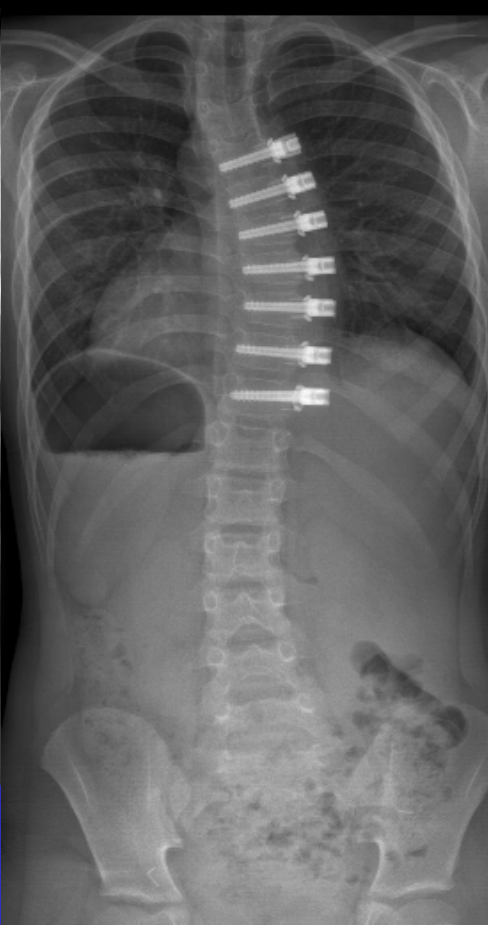
- **Less at the ends**
- **More at the apex**
- **Just to limit of disc motion**
- **Only the levels with vertebral wedging**



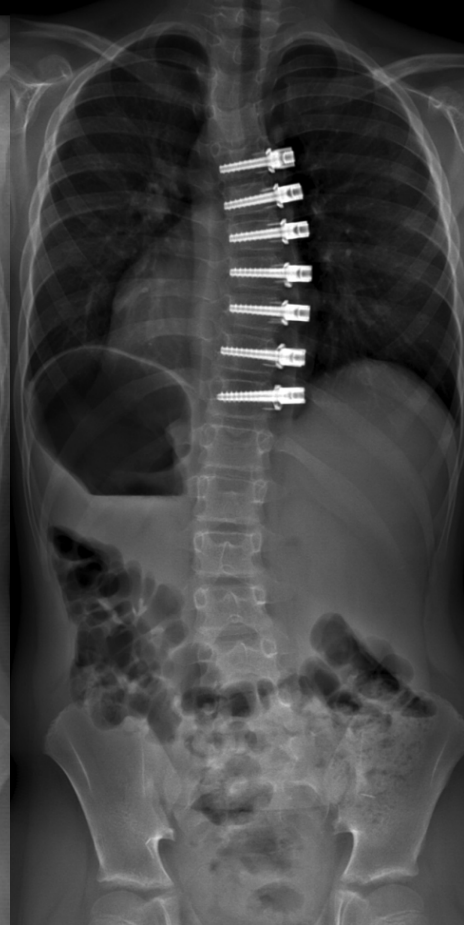Patient 1 PA Images 10 y/o male



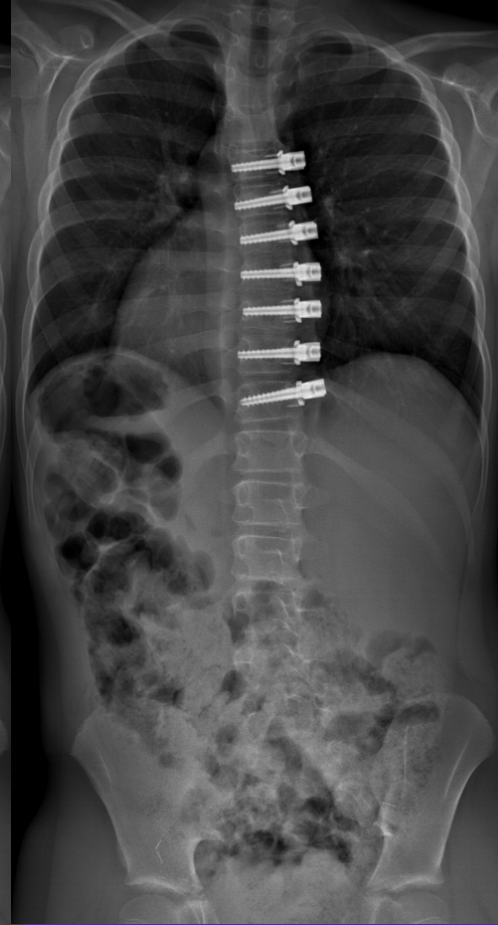
42°
Pre-op



28°
Post-op

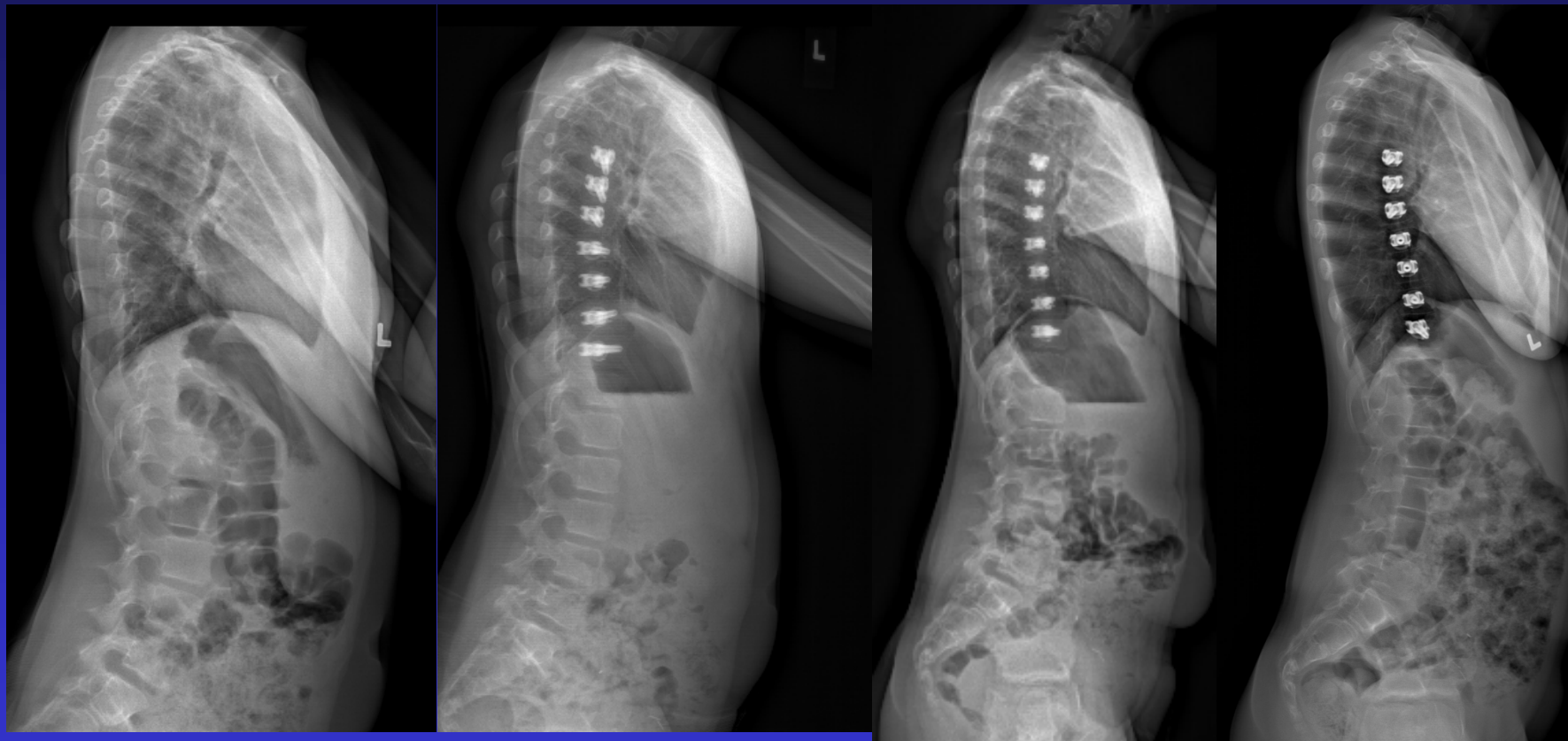


20°
12M

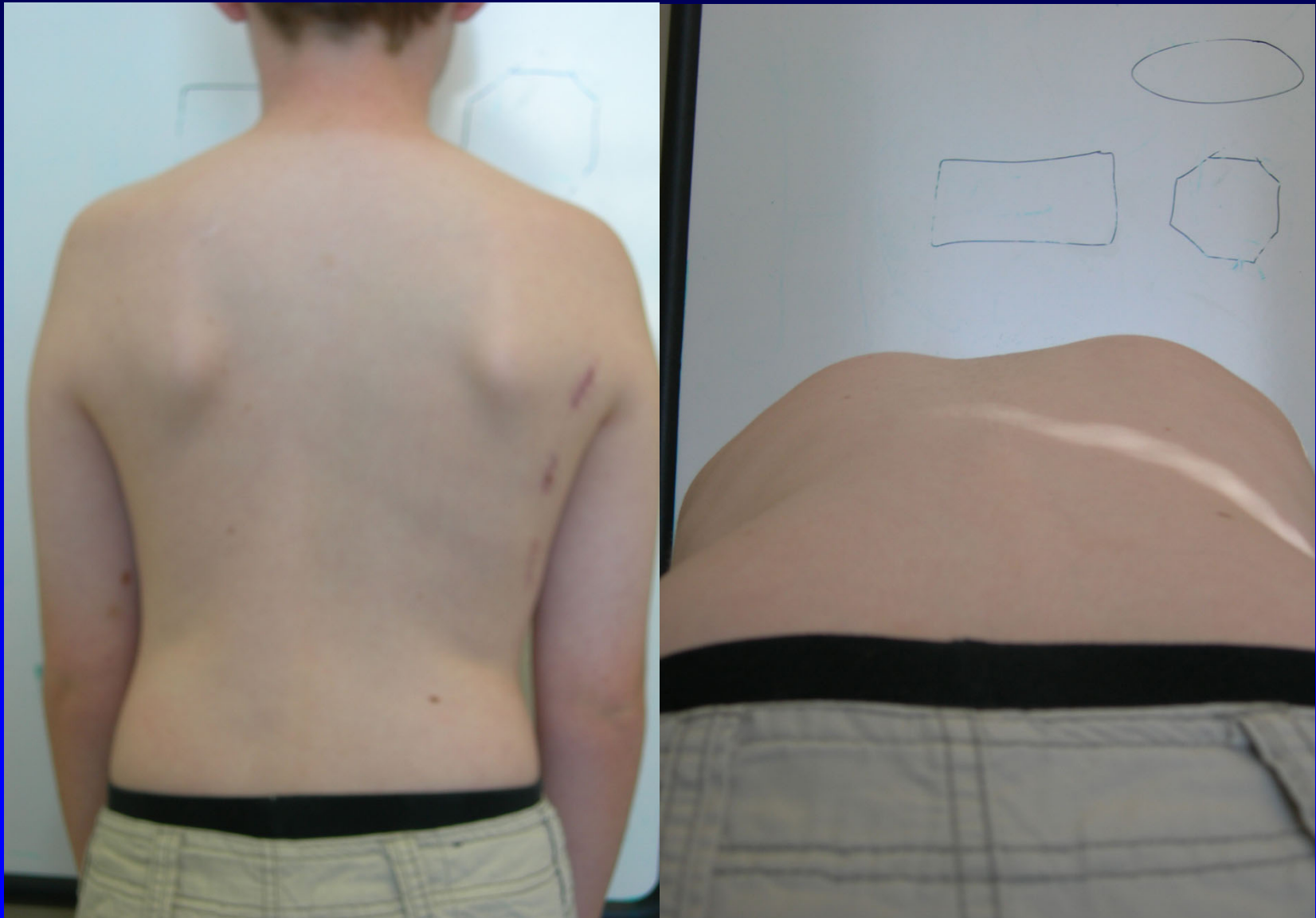


8°
24M

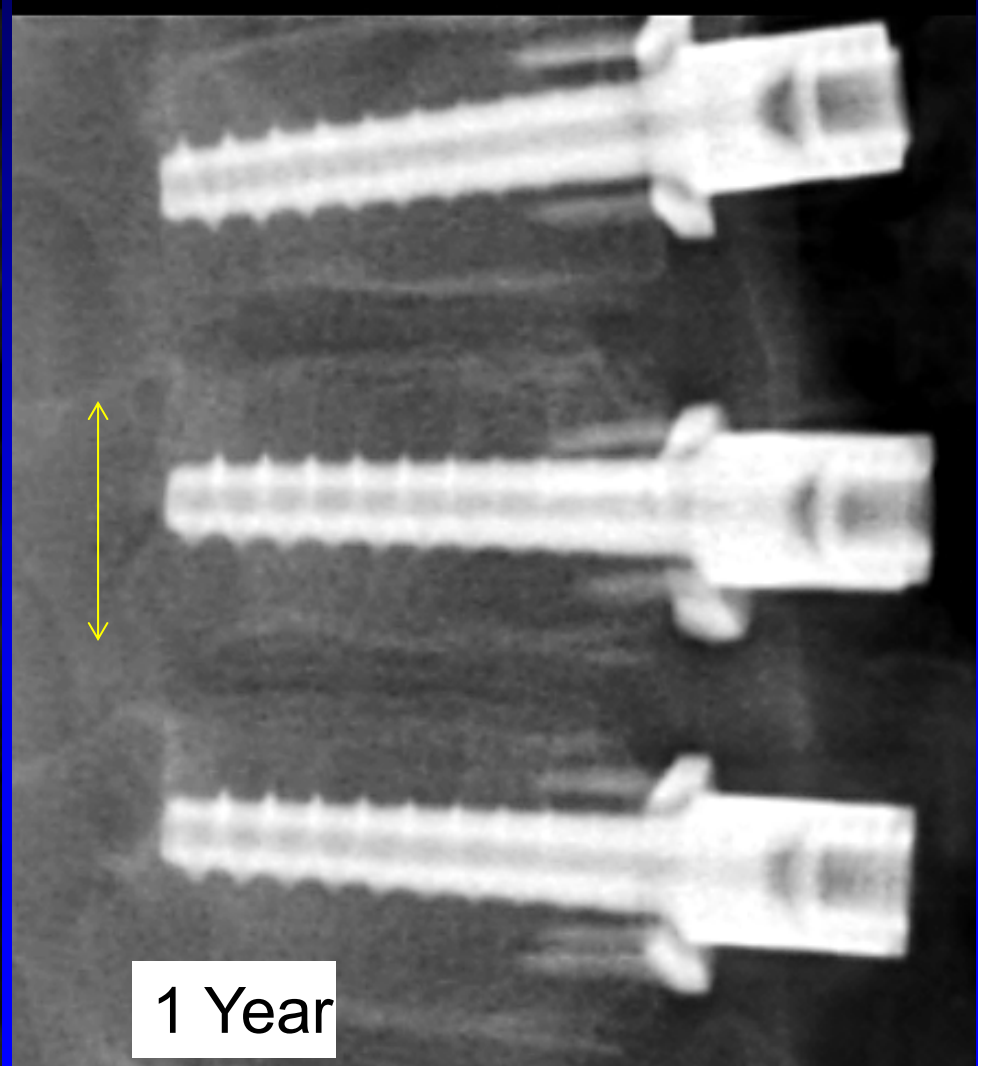
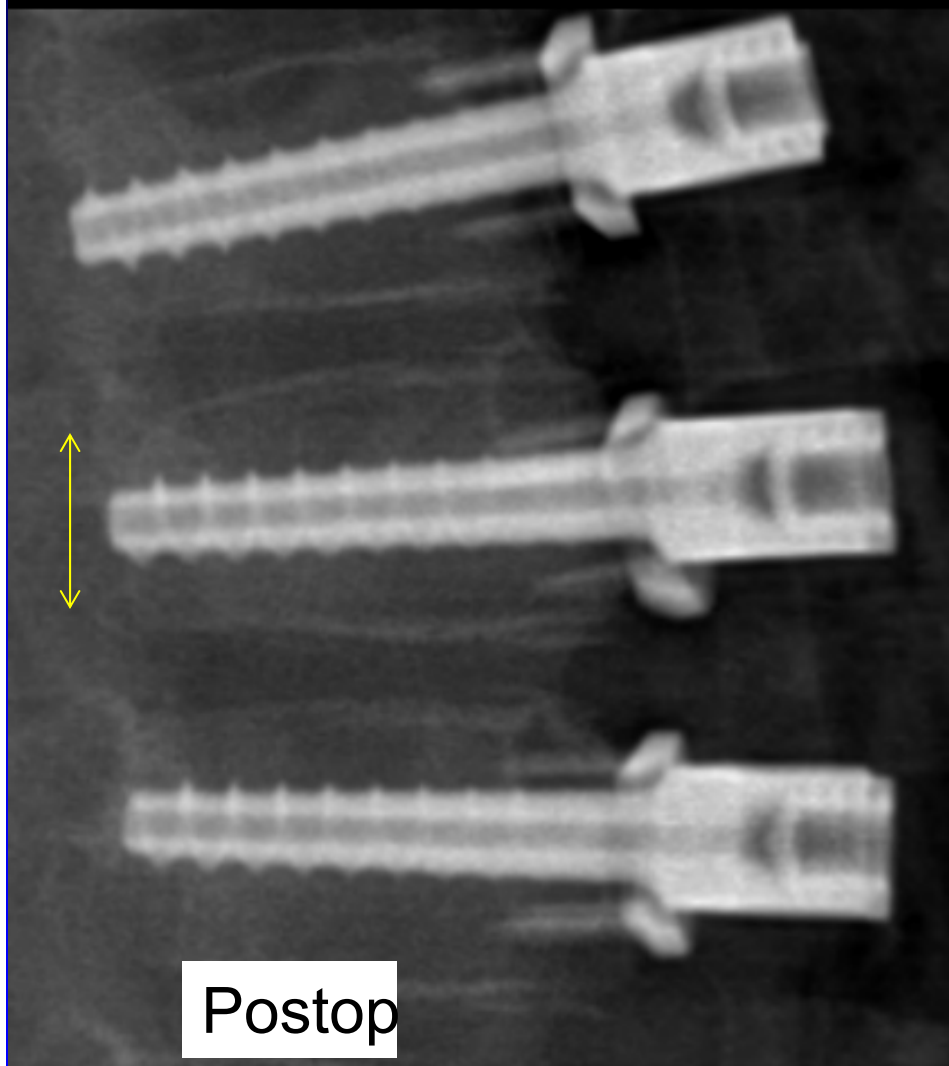
Sagittal Plane



1 year clinical photo

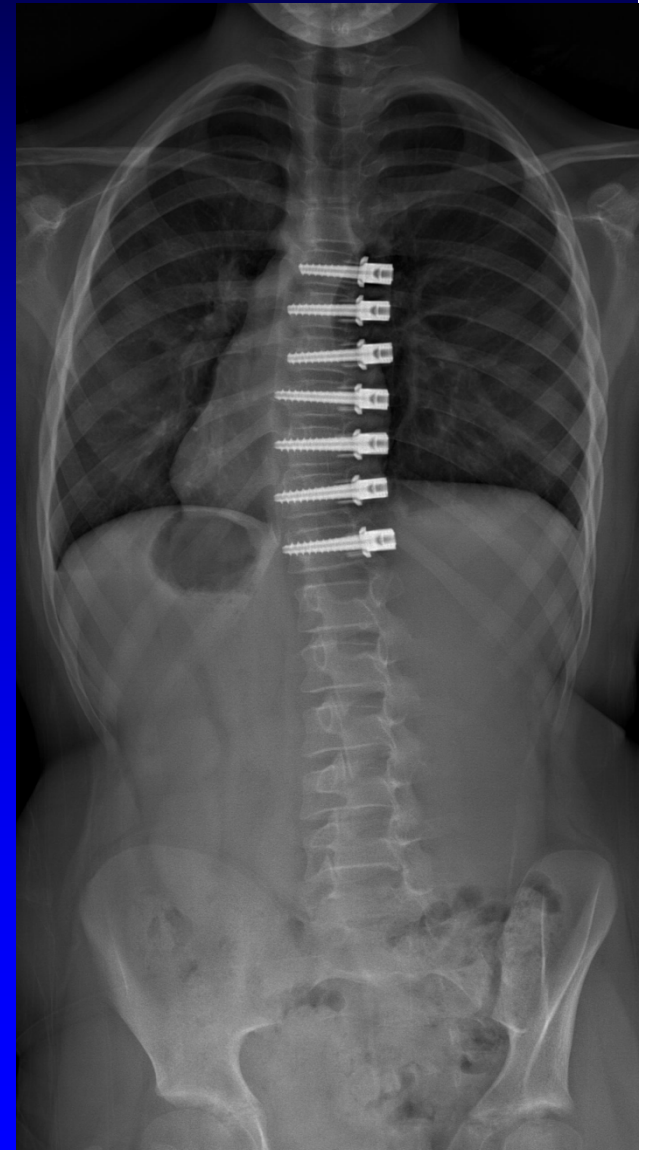

Vertebral Growth Modulation



Potential Issues

- **Thoracoscopic learning curve**
- **Secondary curve response?**
- **Managing Over Correction**
Loosen set screws?
- **Should tether be removed?**
- **Long term effects on discs**
- **Will back become painful?**



Goal: Eliminate Spinal Fusion

- **Thoracic curves**
- **High risk for progression**
- **2-3 years of growth remaining**
(open triradiate cartilage)
- **Curves 45-65 degrees**
- **Indicated for fusion, will to try non-fusion**



