



JOHNS HOPKINS
MEDICINE

Pelvic Anchor Outcomes in Growing Rod Constructs

**An Analysis of Patients with a Minimum of 4 Years of
Post-Operative Follow-Up**

Jaysson T. Brooks MD, Amit Jain MD, Francisco Sanchez Perez-Gruoso MD, David L. Skaggs MD

George H. Thompson MD, Behrooz A. Akbarnia MD, Paul D. Sponseller MD

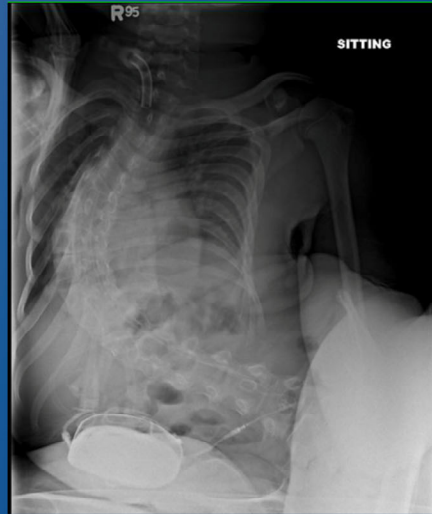May 3, 2021

1

Introduction

- It is well established that non-ambulatory patients with neuromuscular scoliosis require pelvic fixation to prevent distal curve progression
- Little is known about the long term outcomes of growing rod constructs with pelvic fixation in patients with early onset scoliosis

5/3/2024



2

Pelvic Fixation of Growing Rods

Comparison of Constructs

Paul D. Sponseller, MD,* Justin S. Yang, BS,* George H. Thompson, MD,†
Richard E. McCarthy, MD,‡ John B. Emans, MD,§ David L. Skaggs, MD,¶
Marc A. Asher, MD,|| Muharrem Yazici, MD,** Connie Poe-Kochert, CRNP,†
Pat Kostial, RN, BSN,†† and Behrooz A. Akbarnia, MD††

They found that:

- Iliac screws provided better correction of the Cobb angle than sacral fixation alone ($p = 0.04$)
- Iliac screws provided better improvement of pelvic obliquity than sacral anchors ($p = 0.001$)
- Dual rods provided better pelvic obliquity correction than unilateral rods ($p = 0.006$)
- Higher rate of iliac screw breakage as the only statistically significant complication ($p = 0.035$)

5/3/2021

3

In 2009 Sponseller et. al and the growing spine study group set out to answer this question by performing a retrospective analysis of 36 patients from the GSSG database that had growing rods anchored to the pelvis (SLIDE)

While this study showed promise for growing rod constructs anchored to the ilium, little was known about the outcomes on long term follow-up.

Purpose



- The purpose of this study was to evaluate which distal anchors provide the best correction of:
 - pelvic obliquity
 - sagittal balance
 - thoracic kyphosis
 - lumbar lordosis in patients with at least 4 years of post-operative follow-up.
- In addition long-term complications were evaluated based upon the type of distal pelvic fixation used.

Methods

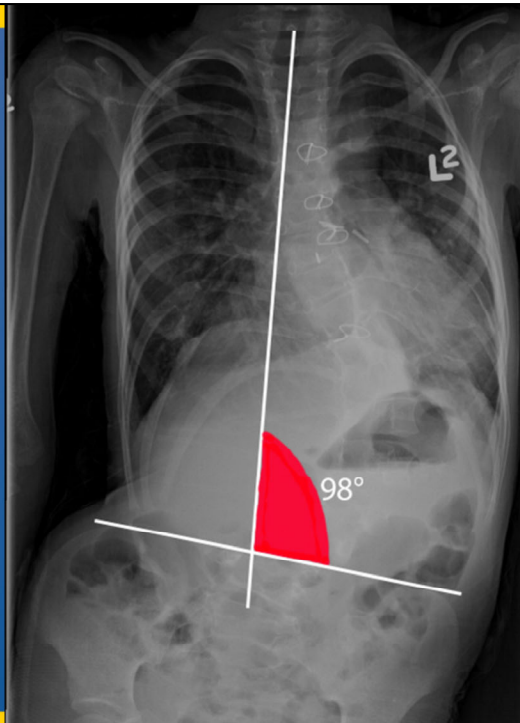


- We performed a retrospective review patients of in the Growing Spine Study Group database seen from 1990 to 2010
- Inclusion Criteria:
 - Posterior spinal fusion with a dual growing rod construct
 - Pelvic Fixation
 - Age 0-18 years old
 - Minimum 4 years of post-operative follow-up including radiographic data

Methods

Pelvic obliquity was defined as the angle formed by a line traversing the midpoint of T1 to S1 and a line that is tangential to the iliac crests, subtracted from 90°

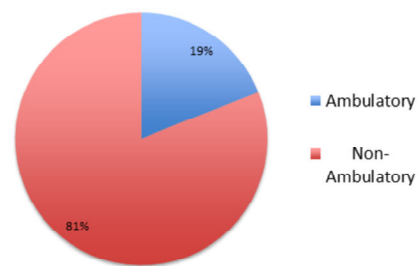
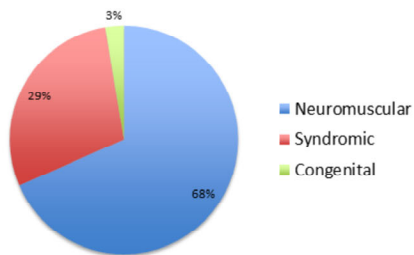
5/3/2021

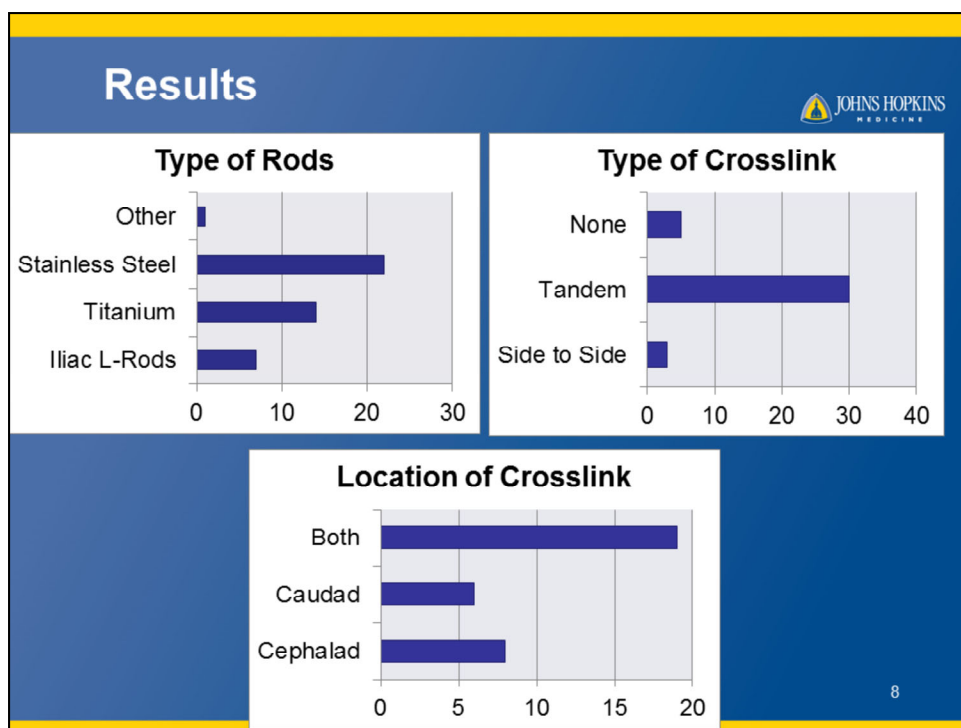


Results

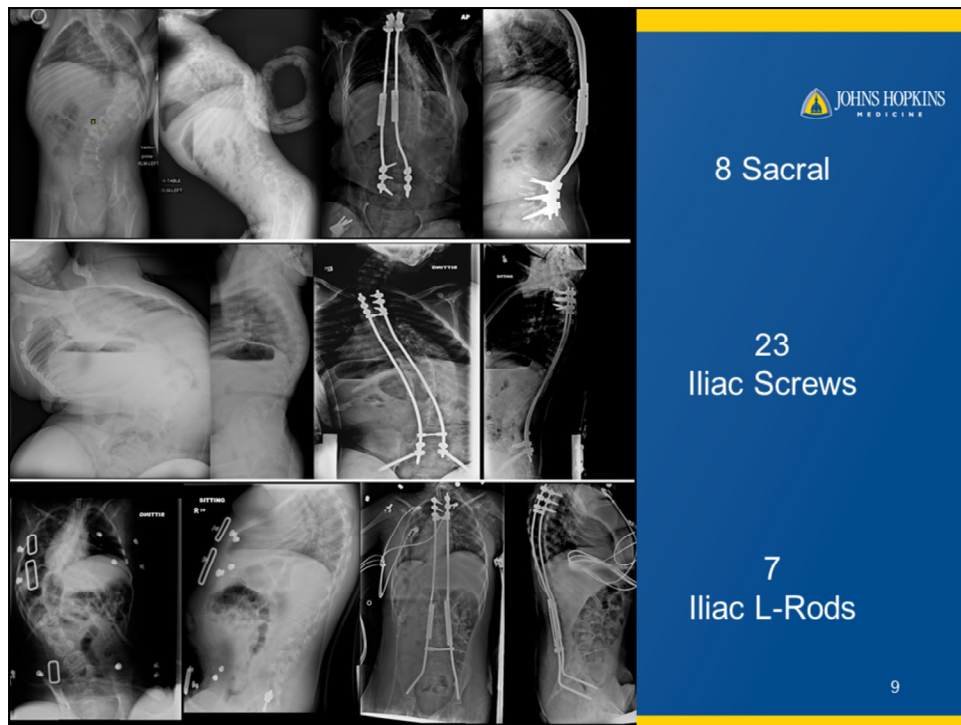


- 38 patients were identified from 7 major pediatric academic centers
- The majority of our patients were non-ambulatory with a diagnosis of neuromuscular scoliosis.
- The mean post-operative follow-up was 5.1 ± 1.7 years.





When looking at the construct demographics, the majority of our patients received stainless steel rods, with crosslinks placed in tandem, both in the cephalad and the caudad positions.

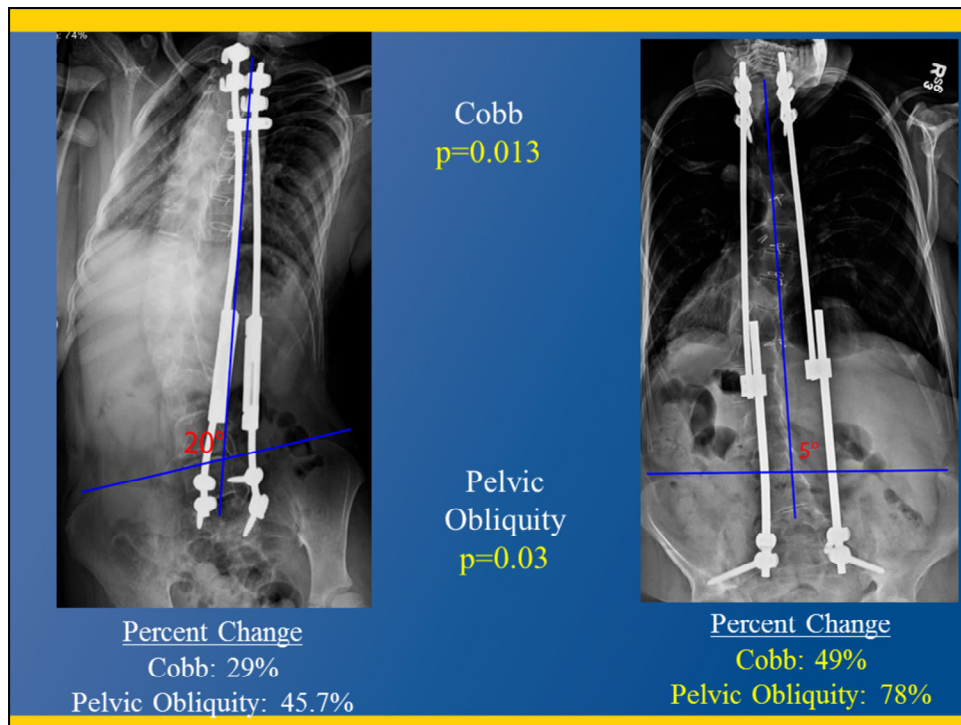


All patients received dual growing rod constructs, anchored to the pelvis. The constructs were composed of (SLIDE)

At final follow-up all but 1 of the iliac L-rods were converted over to iliac screws, and an intrasacral rod was converted over iliac screws with S1 fixation.

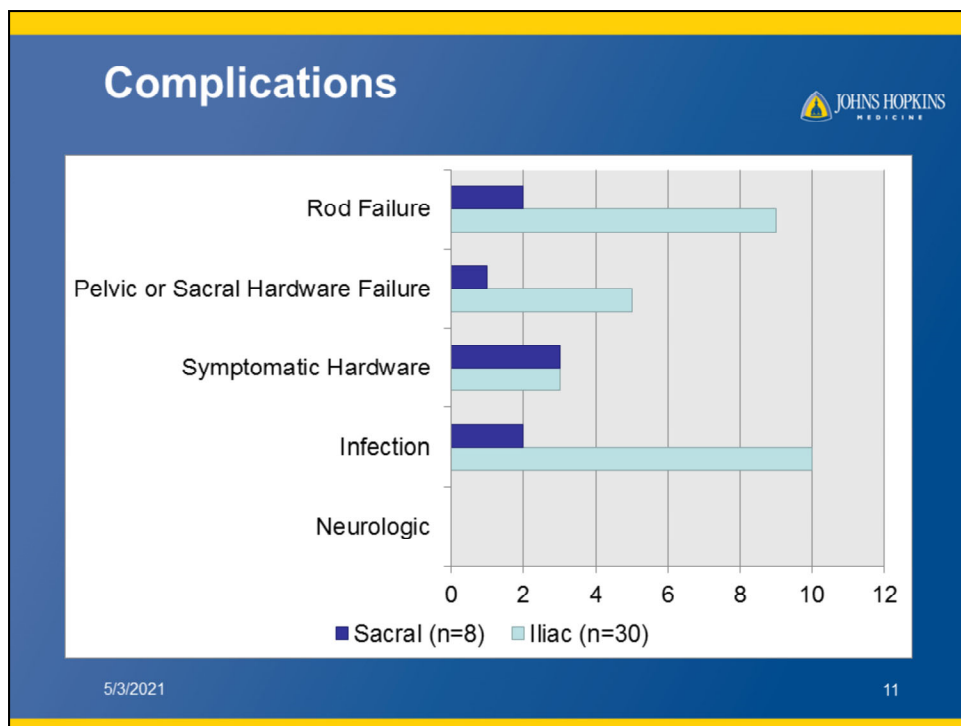
(The trend to patients being switched over to iliac screws could be secondary to surgeons preferring a more modular construct for their revision cases in case they have to revise the construct again.

If they ask: The mean lordosis at latest follow-up in patients with iliac fixation with S1 screws was $37.2^{\circ} \pm 18^{\circ}$ vs iliac fixation without S1 screws which was $-0.89^{\circ} \pm 49^{\circ}$ ($p=0.023$), with the negative prefix indicating a relative lumbar kyphosis.



The patients were divided into two groups, growing rod constructs with distal sacral fixation only and constructs with fixation to the ilium. We found that constructs anchored to the ilium with rods or screws produced a statistically greater decrease in pelvic obliquity at 78% and Cobb angle at 49% than constructs anchored to the sacrum only. We attempted to look at which iliac construct in particular resulted in a significant difference. We found that constructs involving iliac screws with S1 screws compared to constructs anchored to the sacrum alone had a significant difference in Cobb angle.

There was no statistically significant difference in the percent change between the two groups in regards to T1S1 length, kyphosis, lordosis, or sagittal balance.



Of the 38 patients, 22 (or 58%) total had at least 1 complication. Deep wound infections were the most common complication which is not surprising as the majority of our patients had early onset NEUROMUSCULAR scoliosis.

When complications were compared between sacral and iliac pelvic fixation or within the iliac fixation subtypes, there was no statistically significant difference in the rate of complications.

When looking at distal anchor failure; for the sacral fixation group, the mechanisms failure were an S1 foramen fracture and screw pull out. For the iliac fixation group, the mechanisms of distal anchor failure were 3 anchor pull outs, 1 broken iliac screw, and 1 case of anchor plowing.

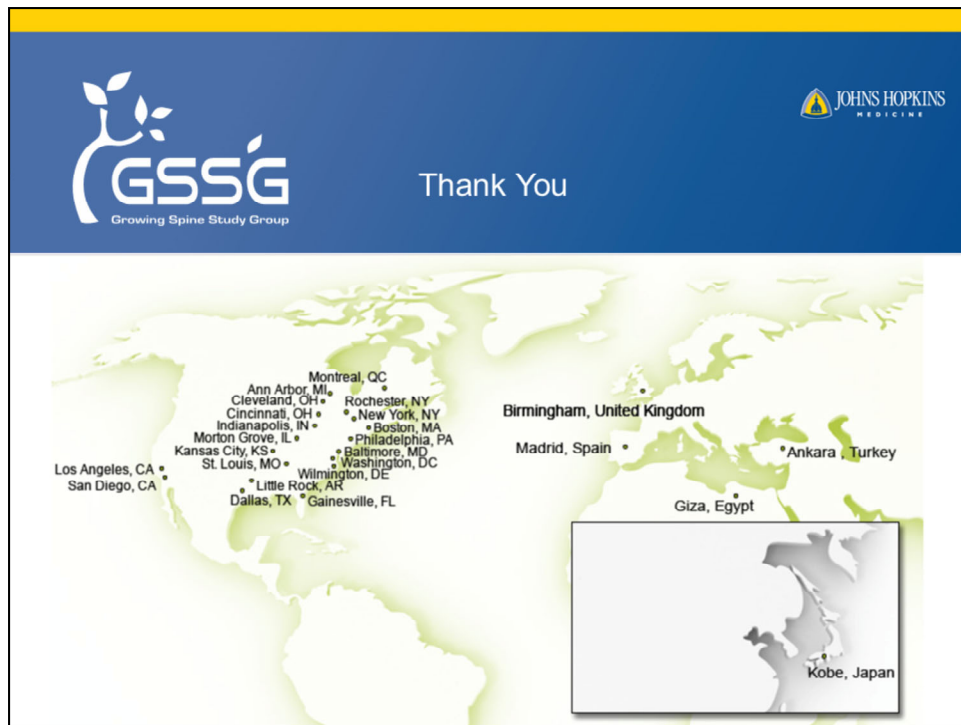Conclusions



- At ≥ 4 years of follow-up, growing rod constructs anchored to the ilium with rods or screws provide a better correction of major Cobb angle and pelvic obliquity in patients with early onset scoliosis
- There is an increasing trend in patients with EOS to use iliac screws as the distal anchor in growing rod constructs
- At ≥ 4 years of follow-up, there is no difference in the rate of complications between growing rod constructs with pelvic fixation using the sacrum only, iliac screws, or iliac rods.

12

Our study is the largest and first of its kind to look at the outcomes of growing rods constructs anchored to the pelvis in patients with a minimum of 4 years of follow-up.



I would like to thank Anna, Jeff, and Craig, and the many members of the Growing Spine Study Group for their guidance and support throughout this project. Thank you.