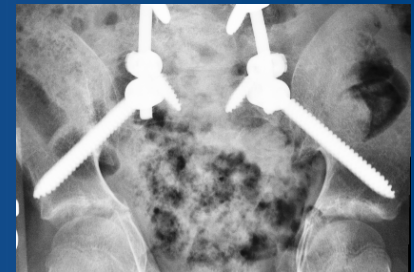




JOHNS HOPKINS
MEDICINE

Master's Technique: Pelvic Screws in Why, When, and How?

Paul D Sponseller MD



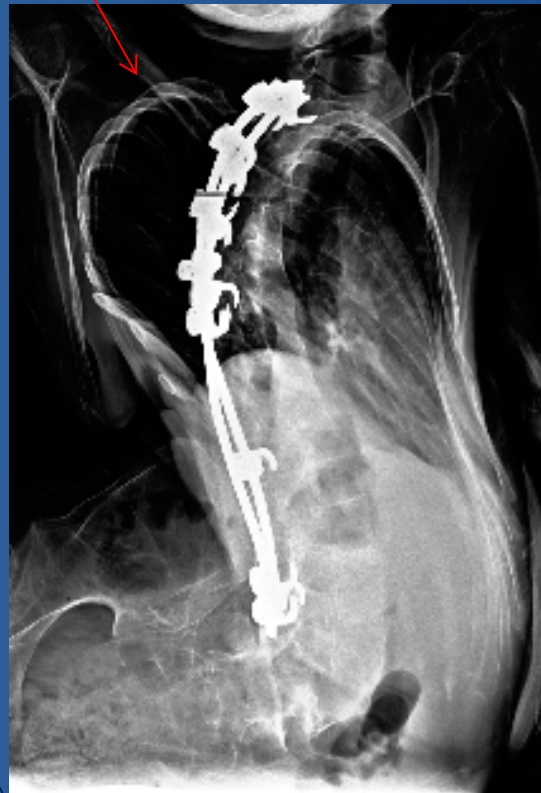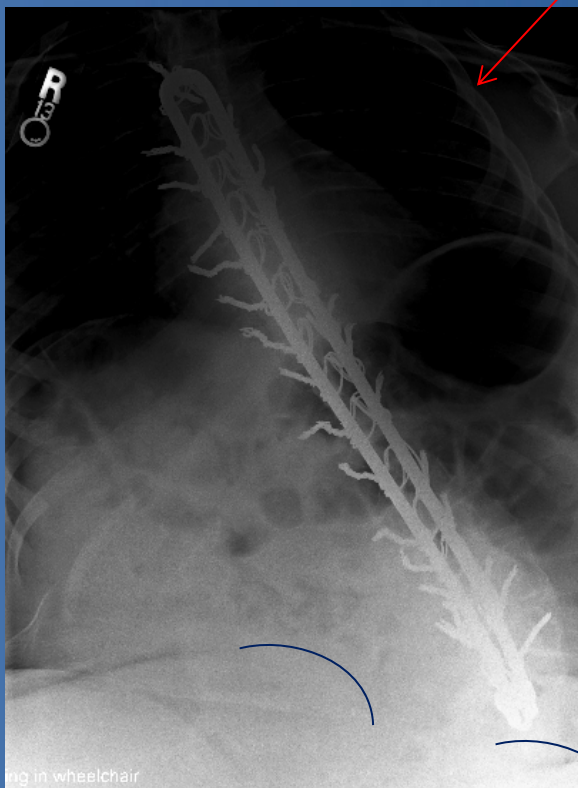
When:

Indications for fusing to pelvis

- Low lumbar apex
- *Plus*
- Poor balance (NM)
 - CP
 - SMA
 - Myelomeningocele
- Structural Deficits
 - Connective tissue disorder

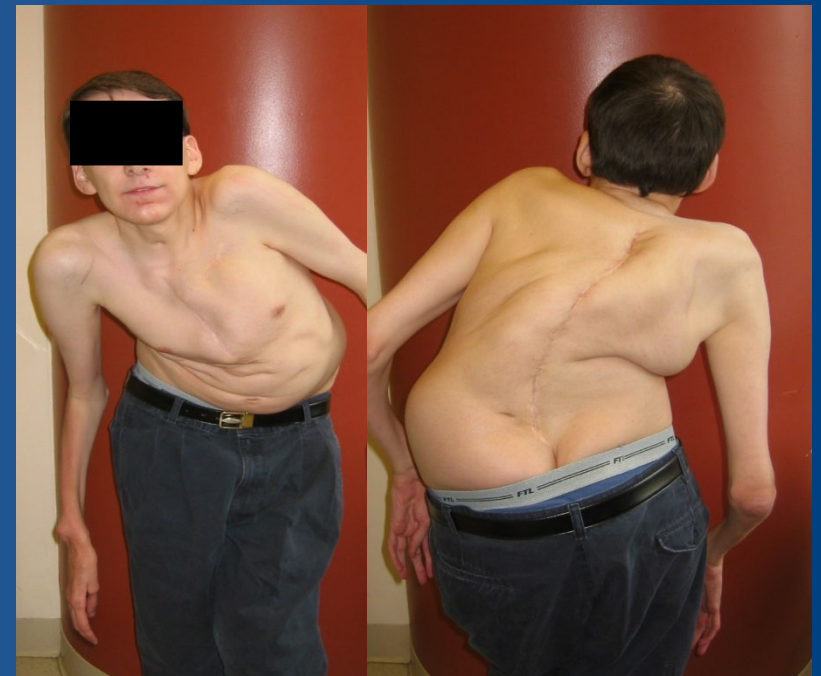Why: Pelvic Fixation

- Best deformity control
- Sparing levels = adding on later!!



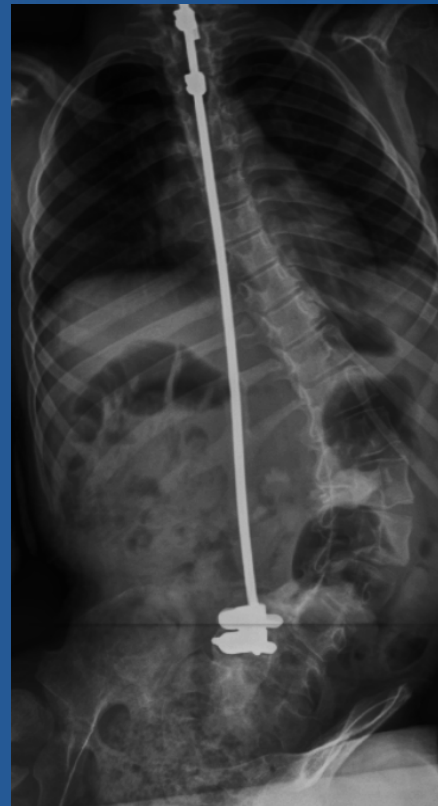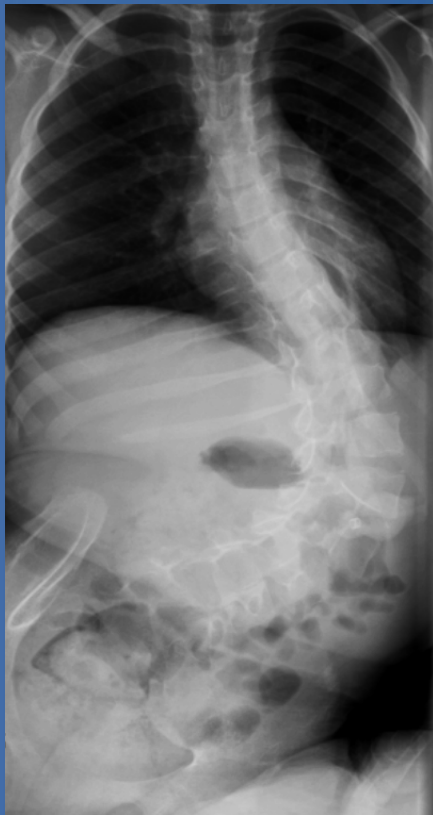Example: Previous Treatments

- Bracing
- Moe Rods
- Luque trolley (non-pelvic)



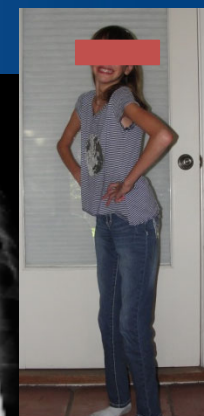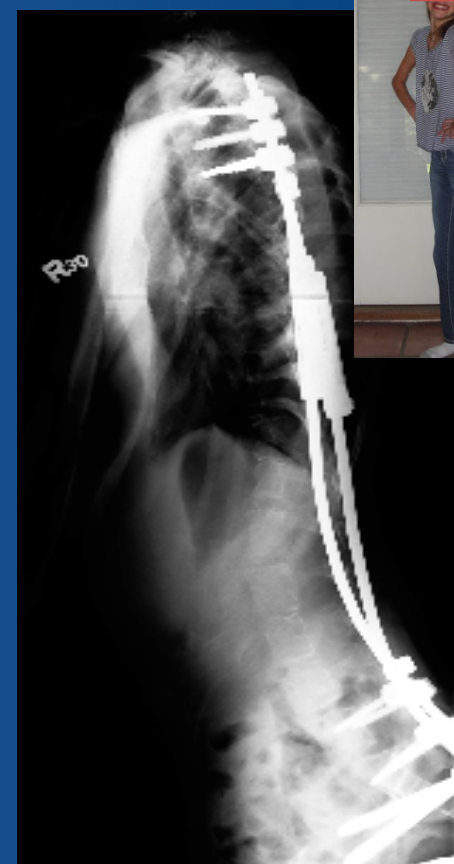
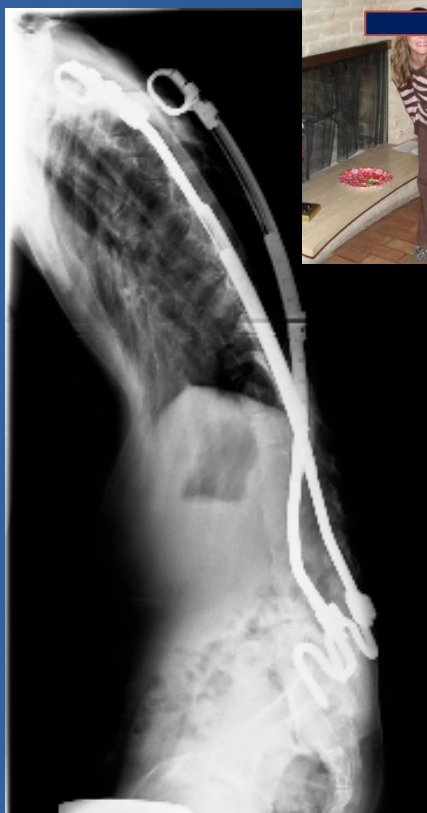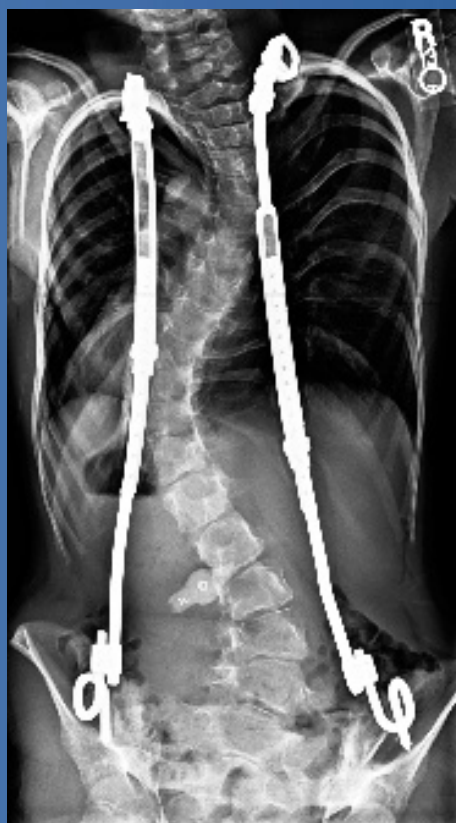How: Technique of pelvic fixation

- Need dual rods to control pelvis



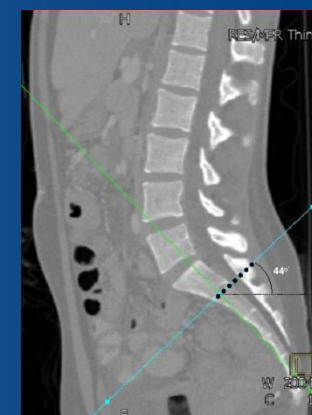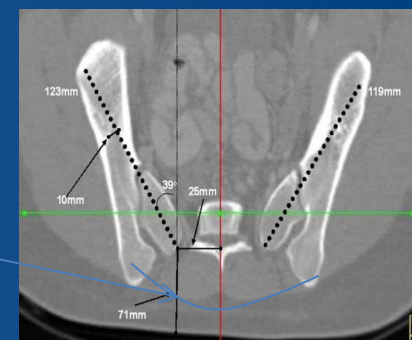
S-hooks

- Pure distraction
- Forward lean progresses



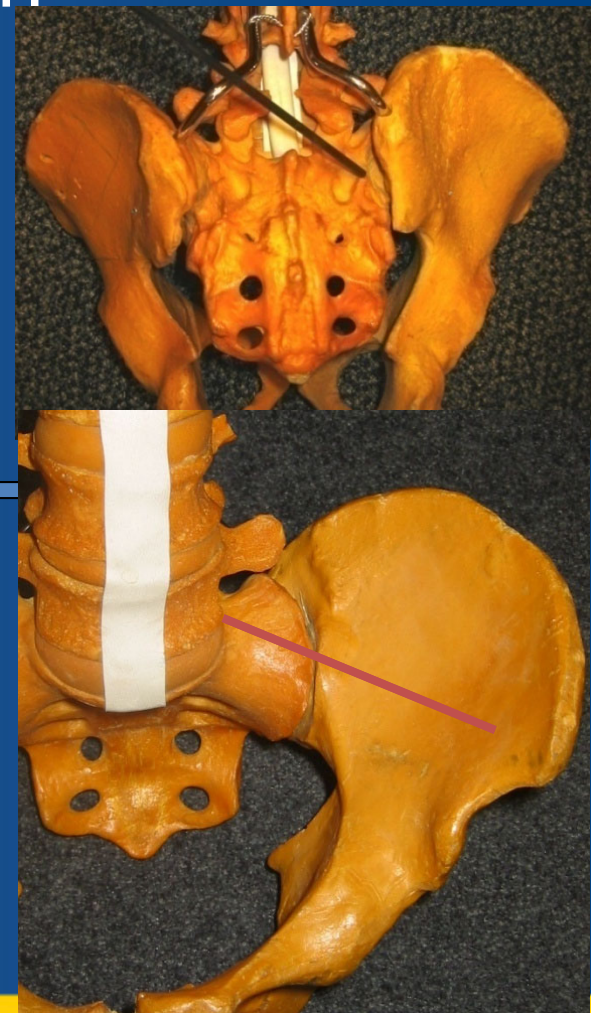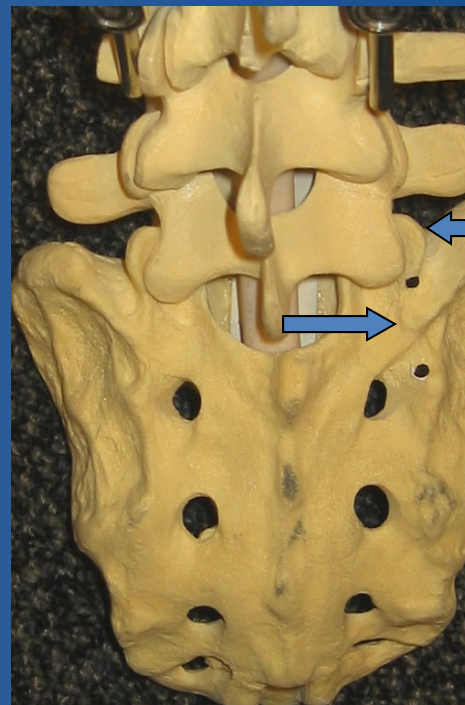
Sacral Alar-Iliac (SAI) fixation

- Iliac Fixation
 - Starting on sacral ala
 - Deeper, within muscle envelope
 - In line with spinal anchors
 - Ideal for pelvic obliquity correction mechanics



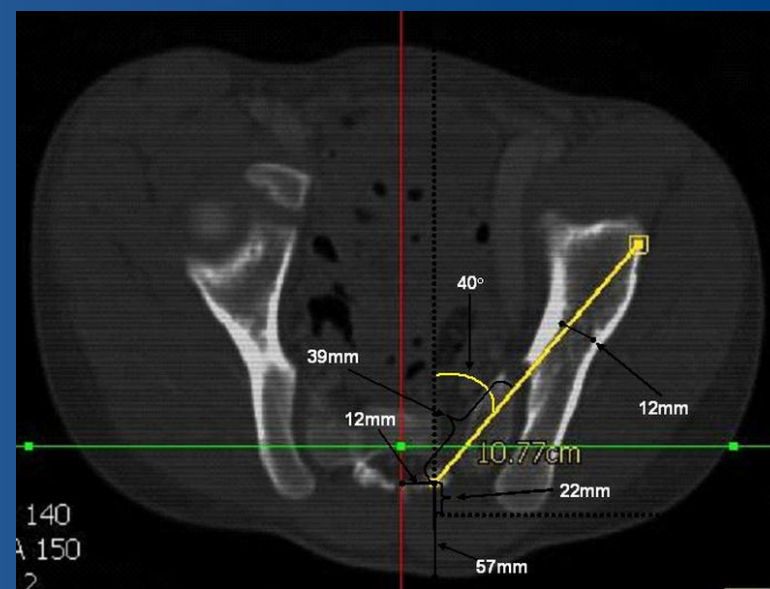Technique: SAI Starting Point

- Fluoro finds major Alar projection
- Angle varies w. pathology!
- Pass just above notch
- Aim for AIIS



Angulation

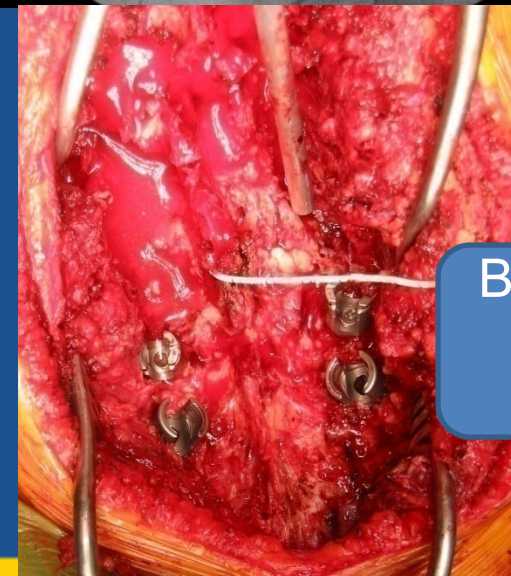
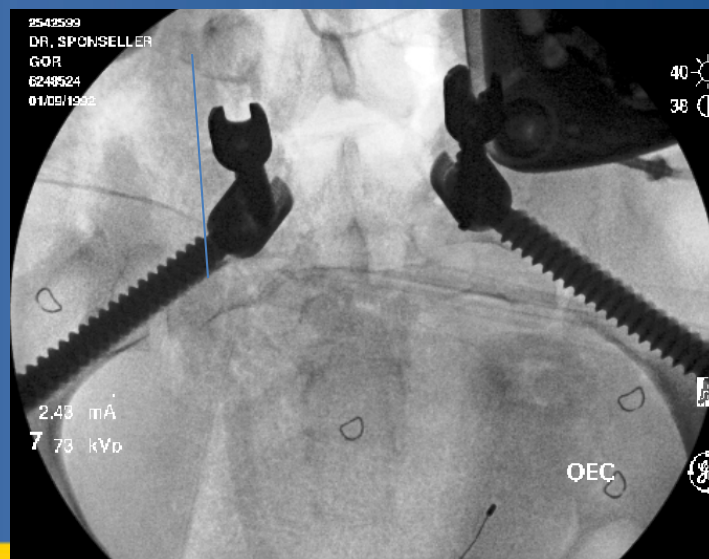
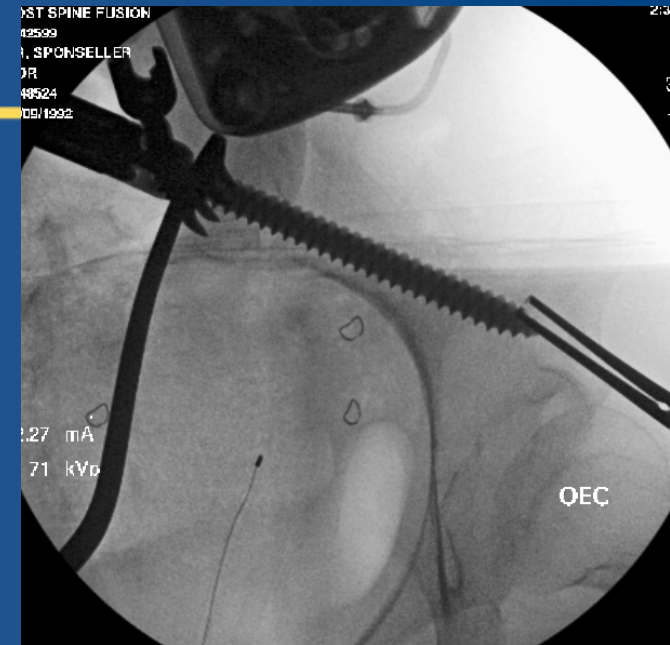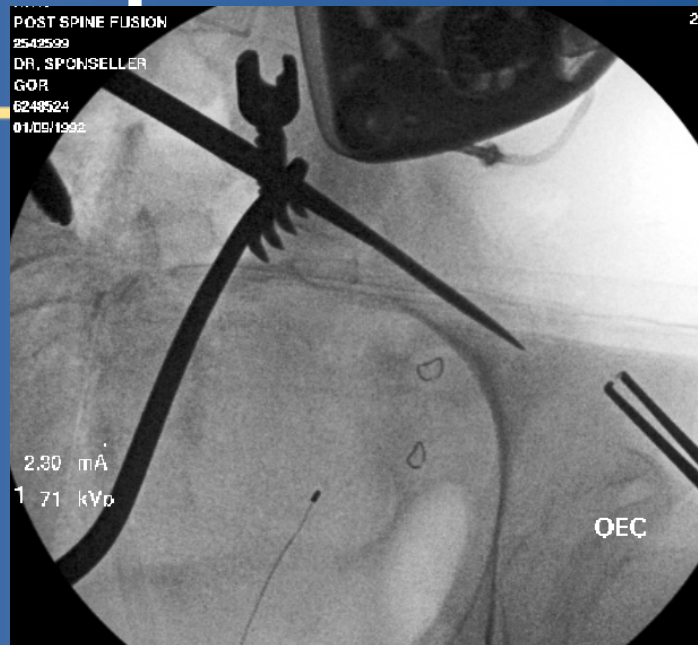- Mean Angulation
 - SAI = 40° caudally, laterally
 - PSIS = 21° laterally; 31° caudally
 - $P < 0.05$
 - More “straight-ahead”
 - More backout?



Technique

- Resistance increases at SI joint
- Awl vs. drill
- Continue till lateral cortex
 - -Cannulated options
- Insertional torque is proof of location

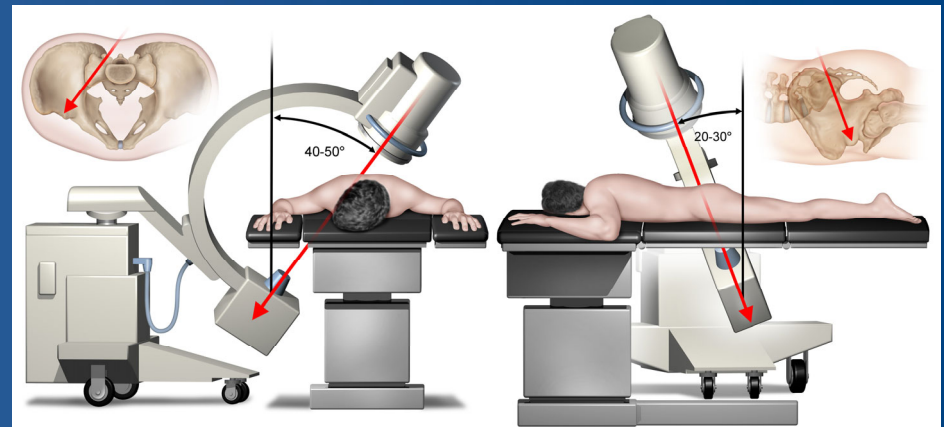
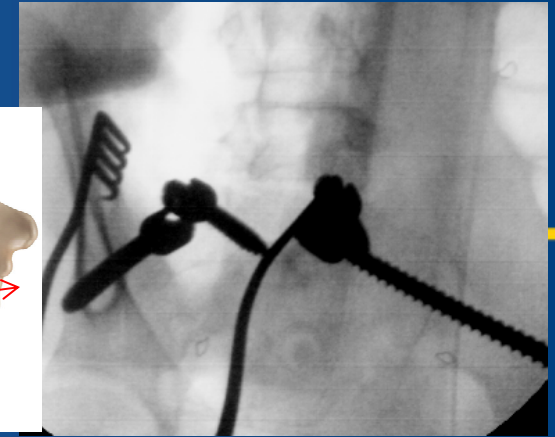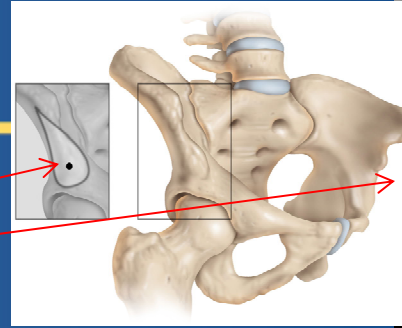
Technique



Baclofen
pump
intact

Technique

- Check “teardrop” if ?
- (Obturator oblique)
 - Start more laterally if “vertical” hemipelvis
 - Seat screw heads at same depth as & in-line with S1 screws
 - Drive partly into bone

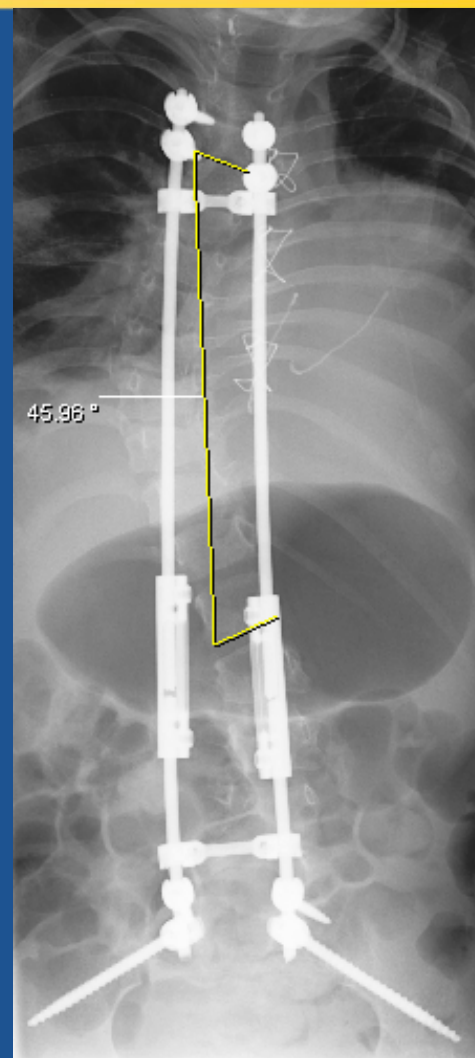
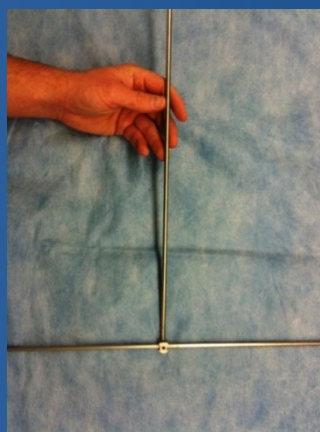
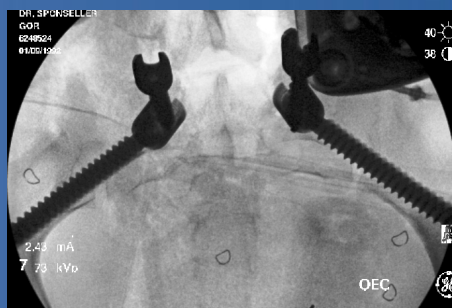
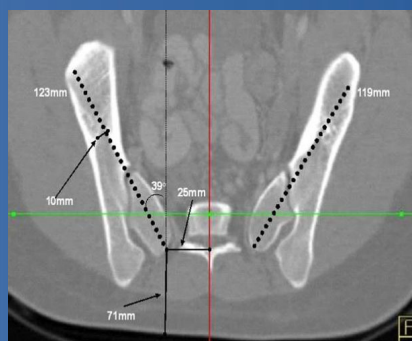


Screw size

- Feel walls, measure depth
- Bigger= less loosening, pull-out
- Prefer 7-8mm x 80 mm
- Even in young NM patients

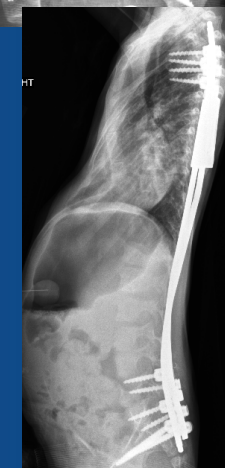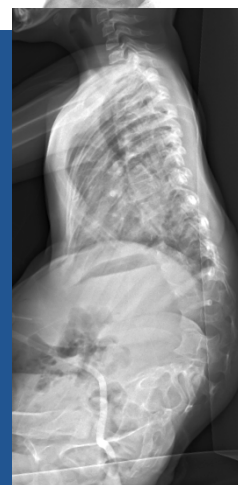
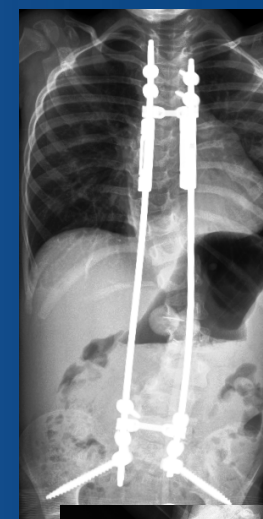
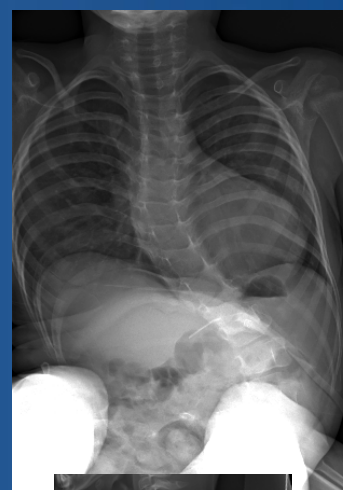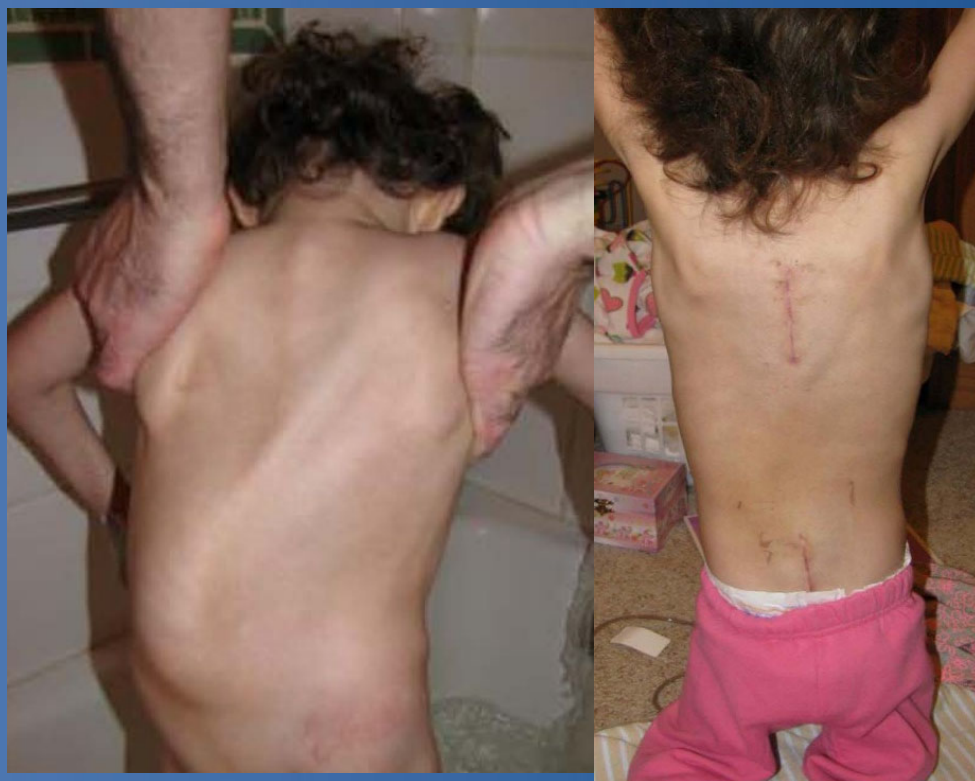Current preferred construct

- Screws in S1 medially
- Long SAI screws



Infantile Marfan Syndrome


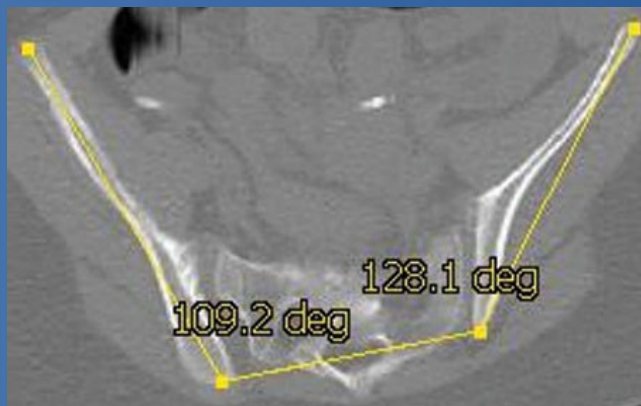
- 2.5 yr old
- 3 heart valves



FAQ / Pitfalls

- Are S1 screws necessary?
 - Yes, if osteoporosis present
 - I prefer polyaxial heads here
 - L5 is a substitute (Skaggs)

Transverse-plane pelvic asymmetry



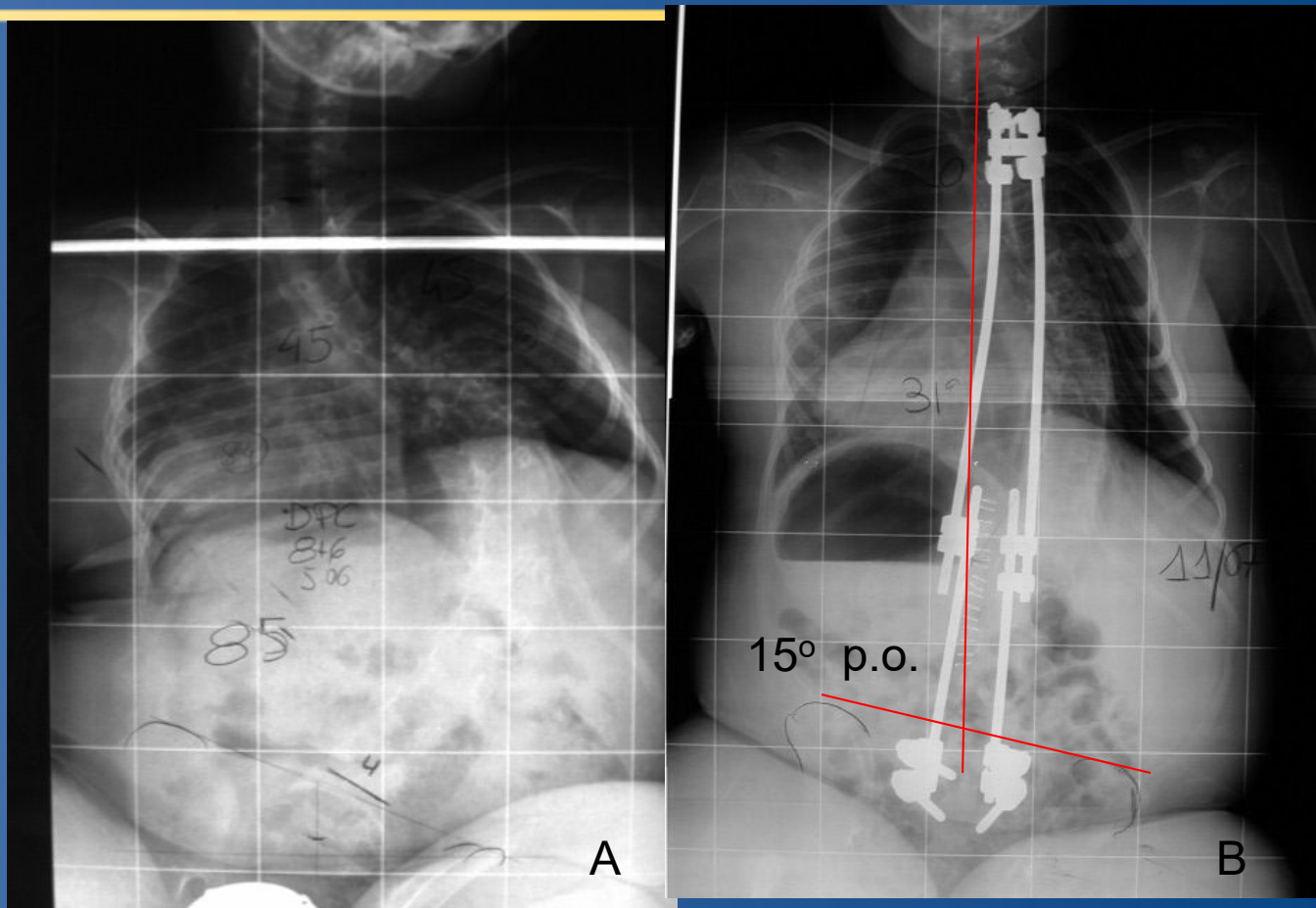
Tips for lateral abutment

- Get angle more “vertical”
- Starting point more laterally
 - Sometimes PSIS
- Use curved awl
- Stay close to notch
 - Where bone is thickest

Thank you

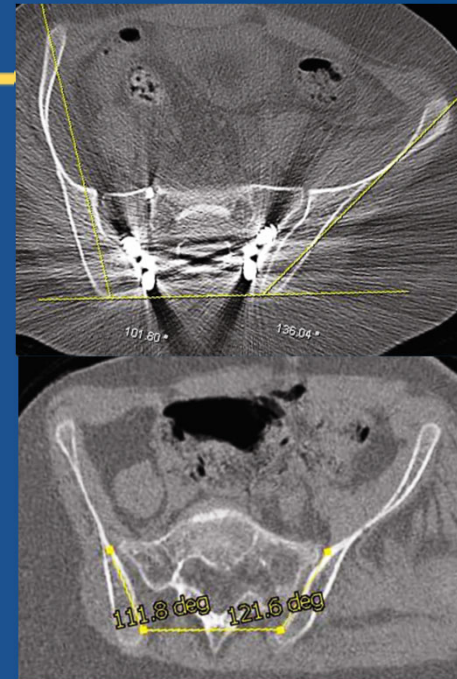


Dual sacral screws



FAQ-pitfalls

- Can you use in difficult CP?
 - Pelvis asymmetrical
 - Use teardrop view to line up
 - Navigation?
- Make sure 1cm rod left distally when tight

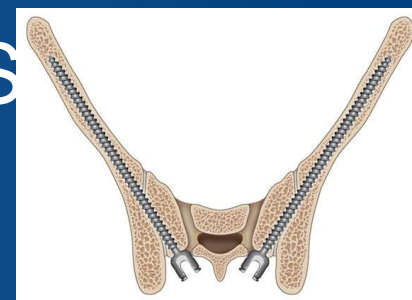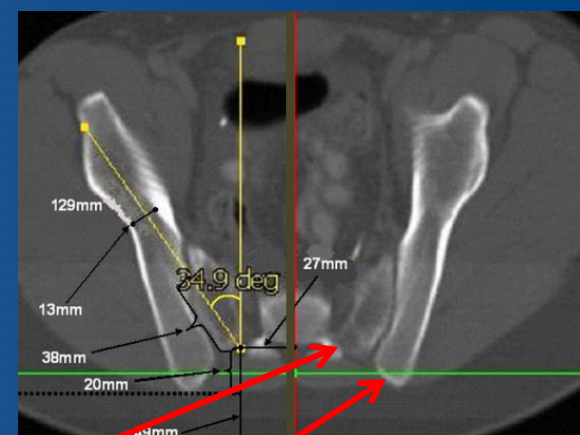


FAQ/Pitfalls

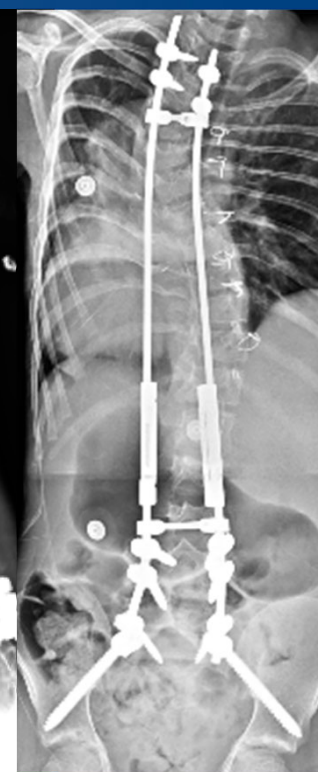
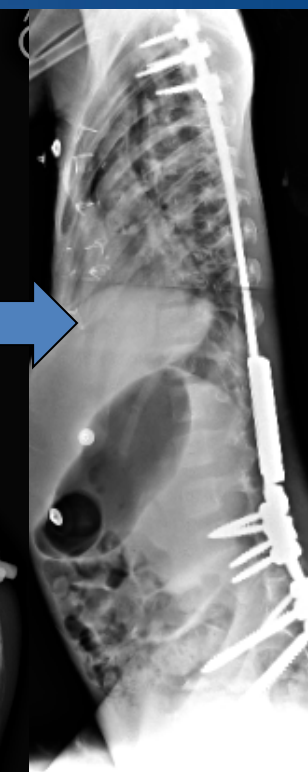
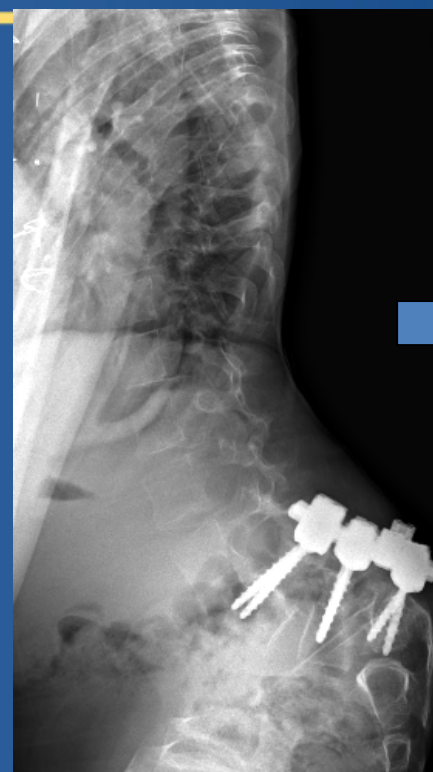
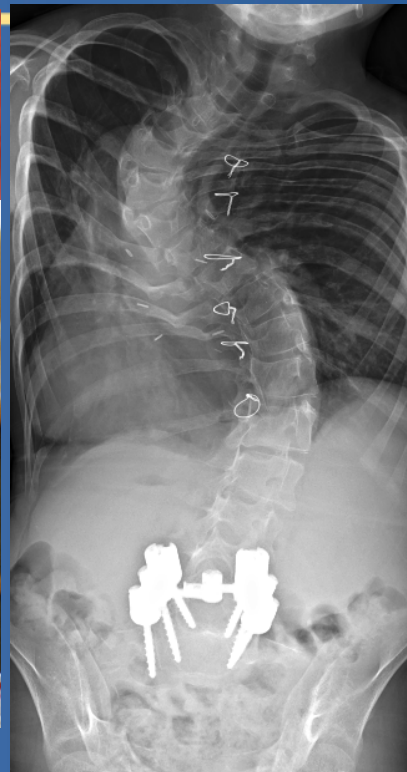- “Stuck” / won’t pass far in ilium
 - Usually abuts lateral cortex
 - Suspect this if ilium seen en face

Anatomic trajectory

- 11mm width
- 105mm length
 - 1/3 in ala, 2/3mm in ilium
- 1.5 cm deeper below skin than PSIS



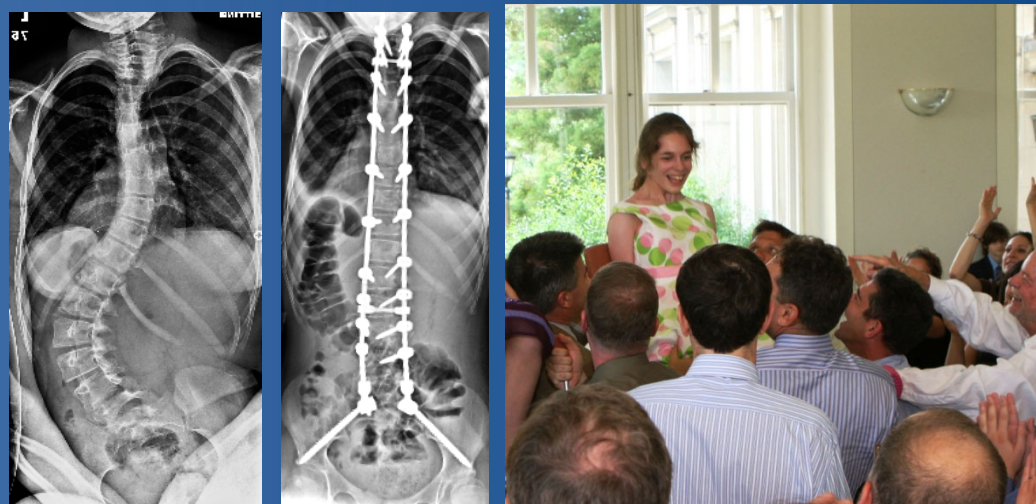
6 y F w. LDS: Spondy + Scoli



Conclusion

- Dual Iliac fixation facilitates correction of pelvic obliquity

-



SMA 5 yrs

- 5 distractions
- Now age 16
- Risser 4

