

# Salvage of Catastrophic Failure of Distraction Based Growing Systems


David L. Skaggs, MD

Professor and Chief

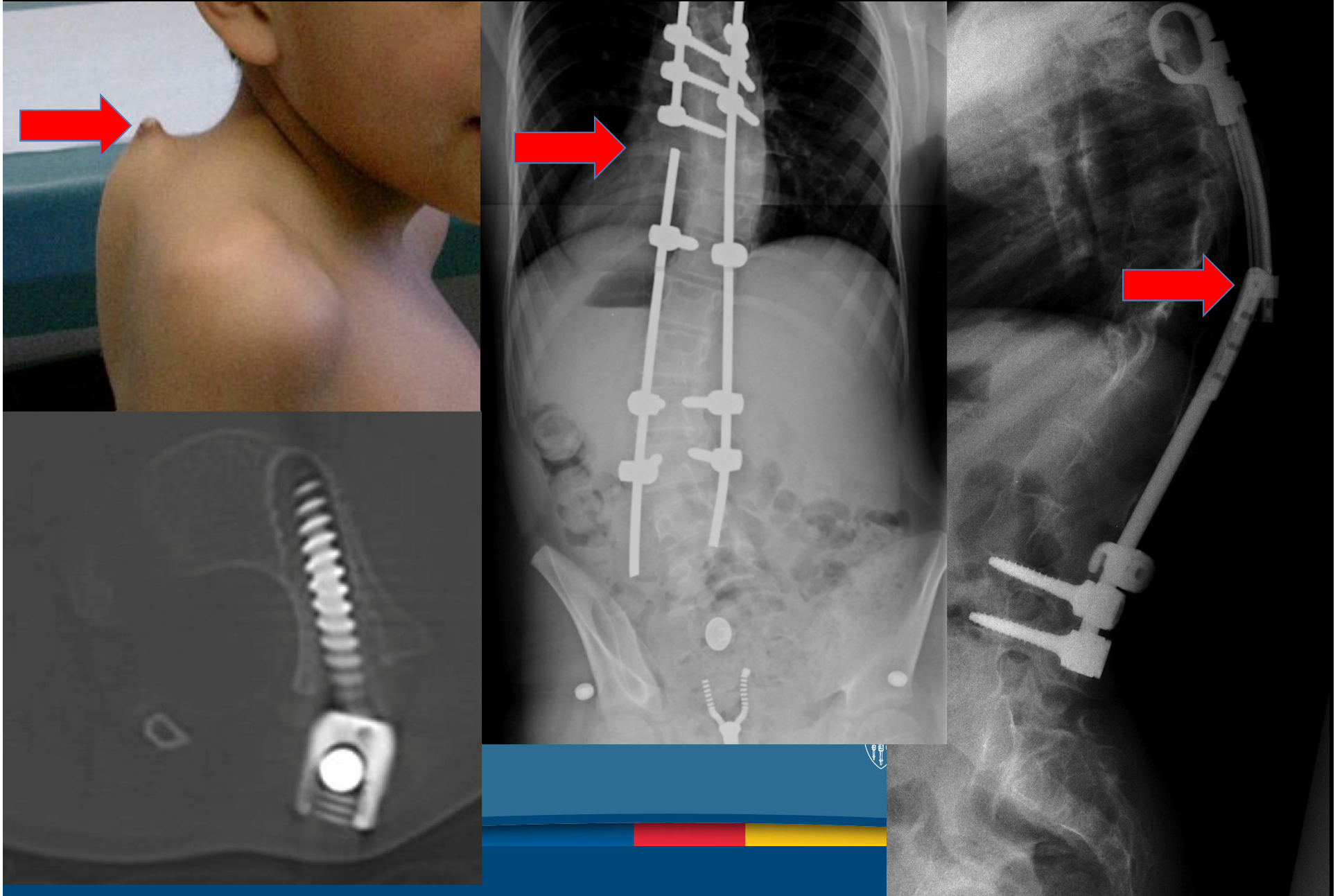
Endowed Chair of Pediatric  
Spinal Disorders

Children's Hospital  
Los Angeles

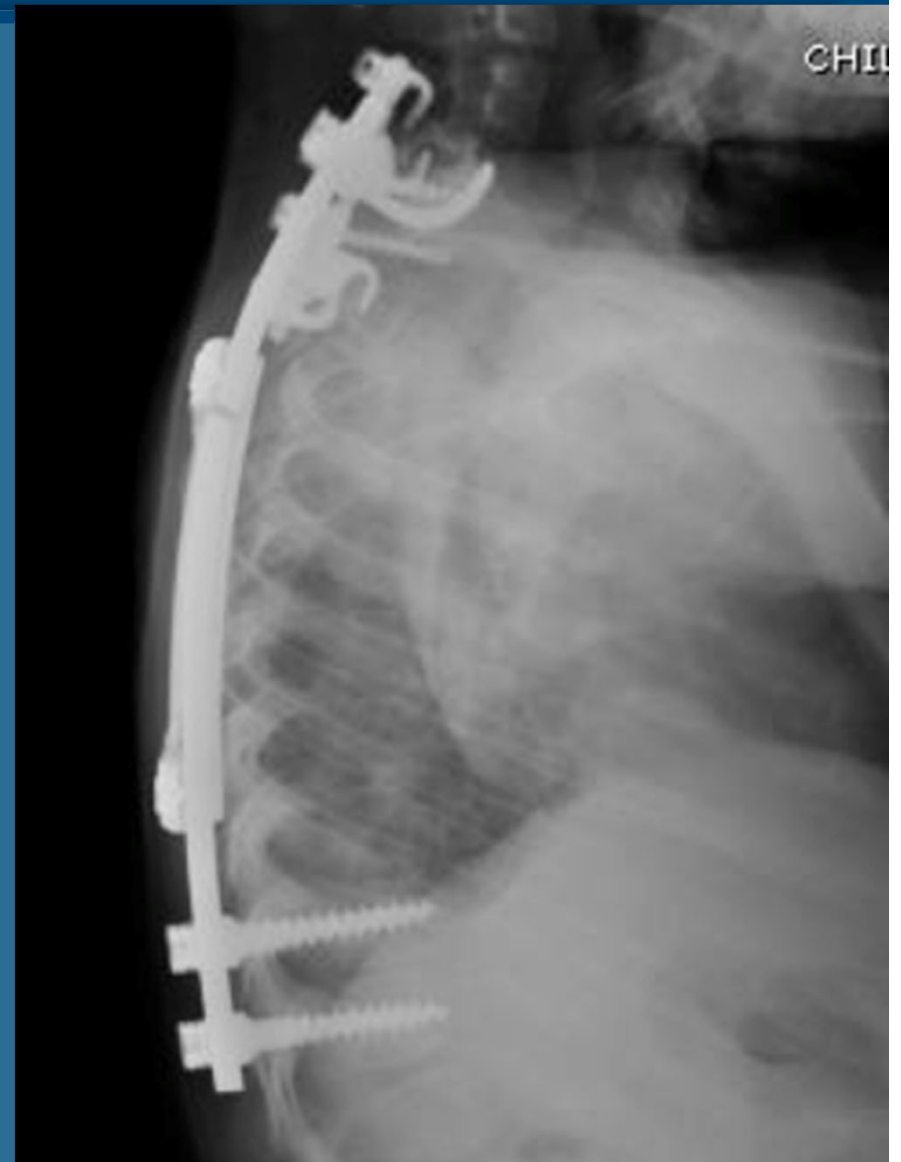University of  
Southern California



# Expect Implant Failures in Non-Fusion Construct

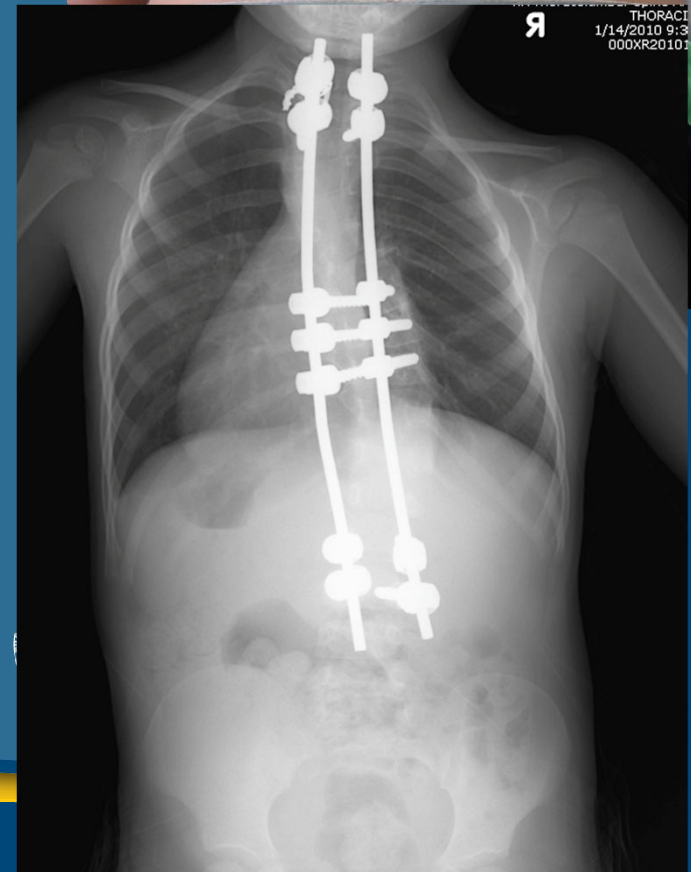
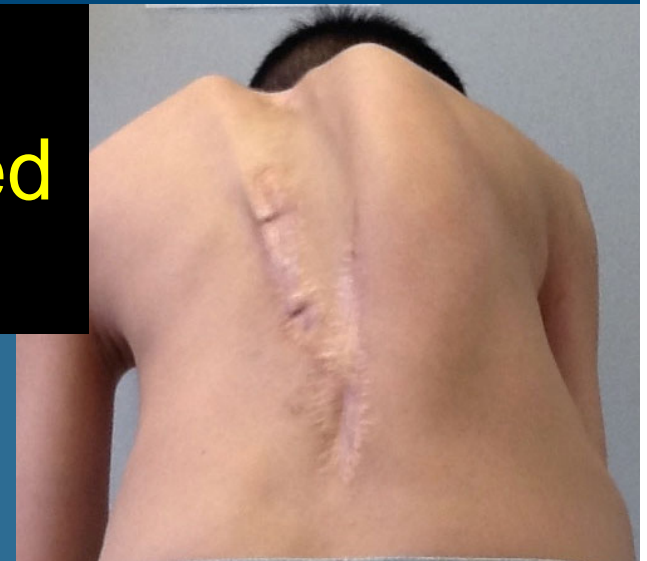

# Ribs Hypertrophy Big Hooks



# Failure: Worsening Crankshaft – Unsolved Pulmonary Sequelae

- May be b/c of posterior autofusion/scarring/tether
- Are dual rods better than single?
  - Does Shilla solve this?
- Tough to measure - metal in way



# Failure: Inhibiting Growth by Non-Growing Rods

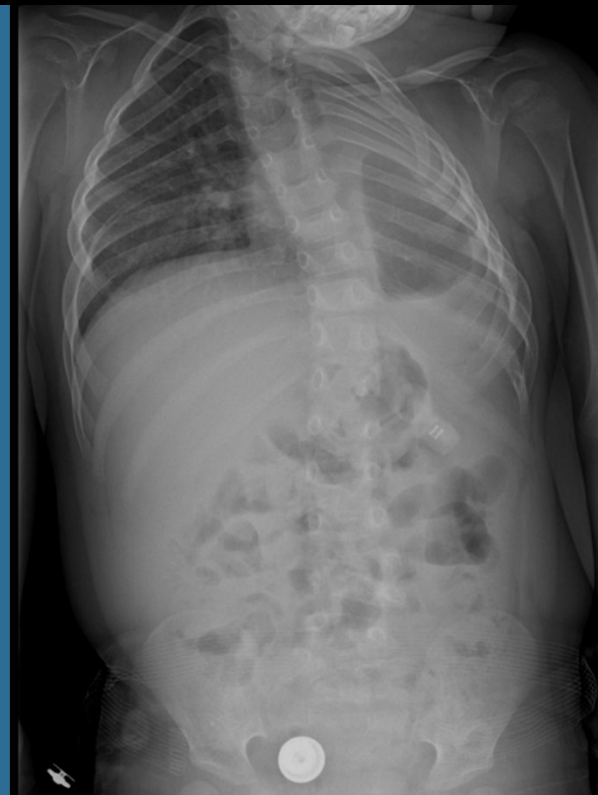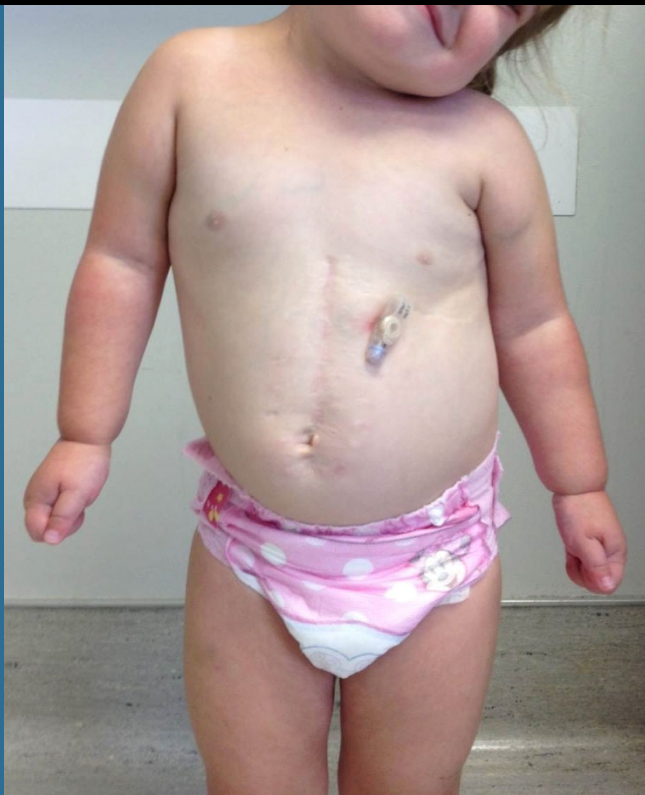Paper #22 presented today  
MCGRs Minimum 5 year f/u

- 3 years (treatment years 2-5) total 11mm of T1-S1 gain
  - Included un-instrumented vertebrae
  - Less than expected growth

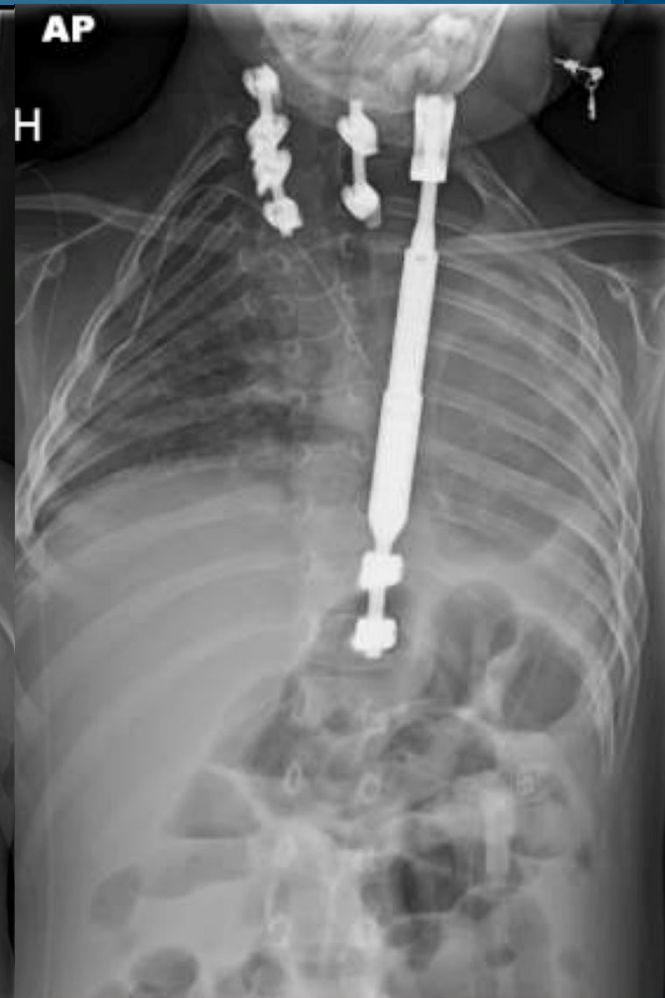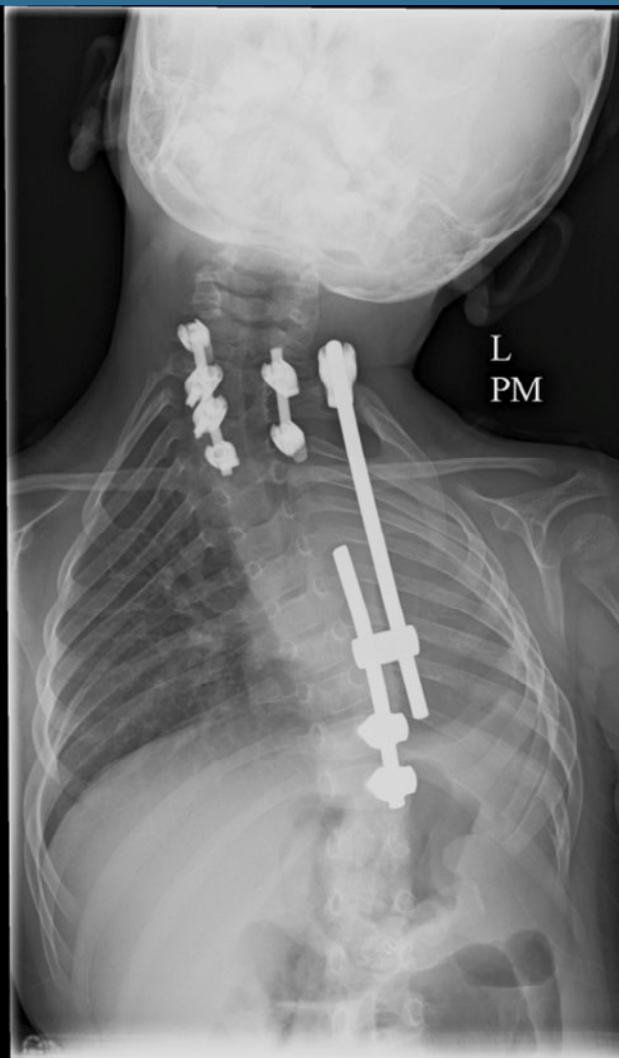
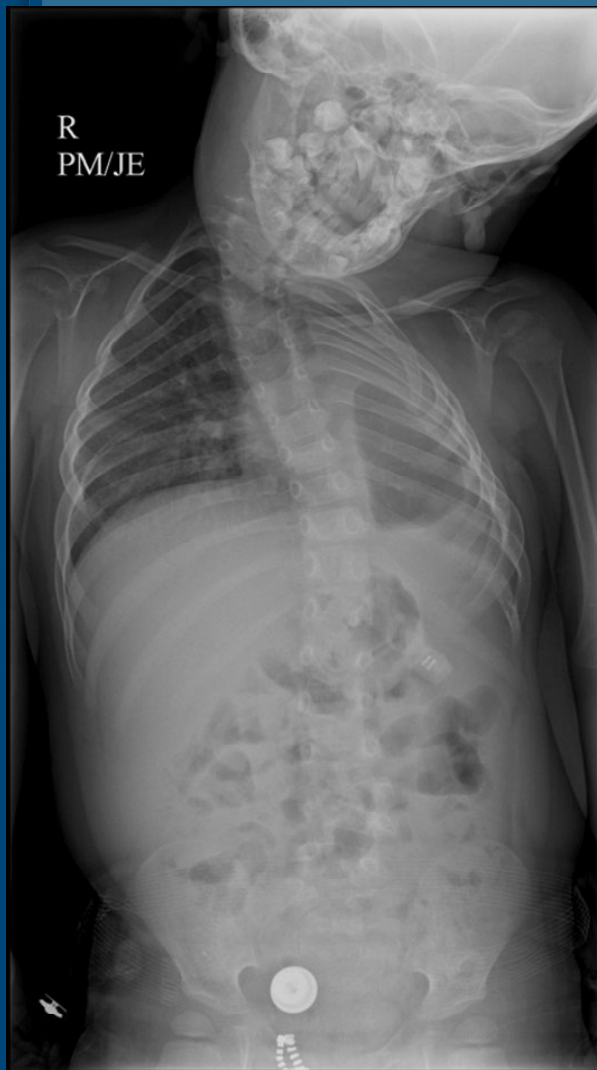Catastrophic failure:

Surgeon Judgment

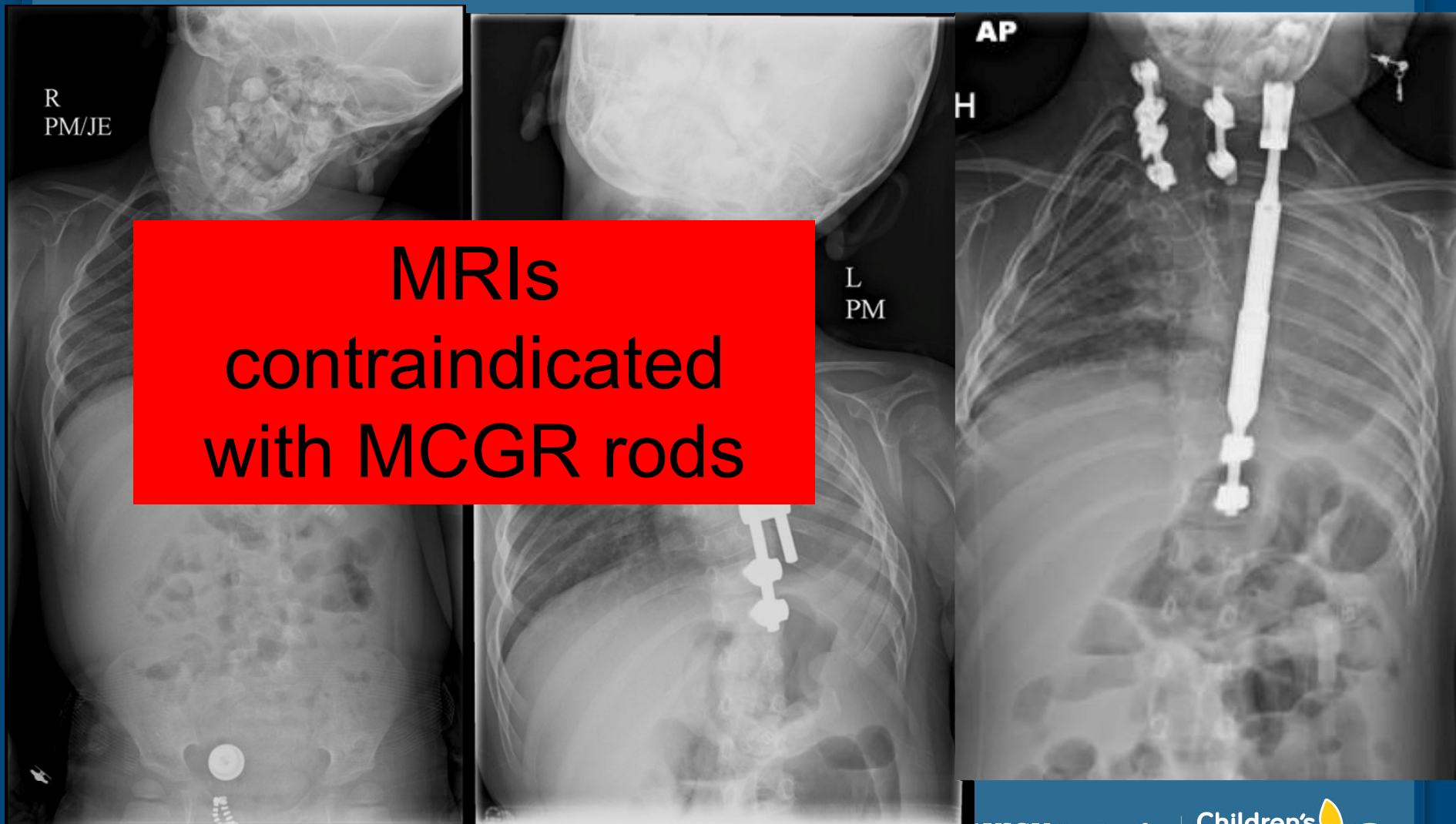
Implant Removal 2 weeks after surgery



# Exchanged to MCGR rod



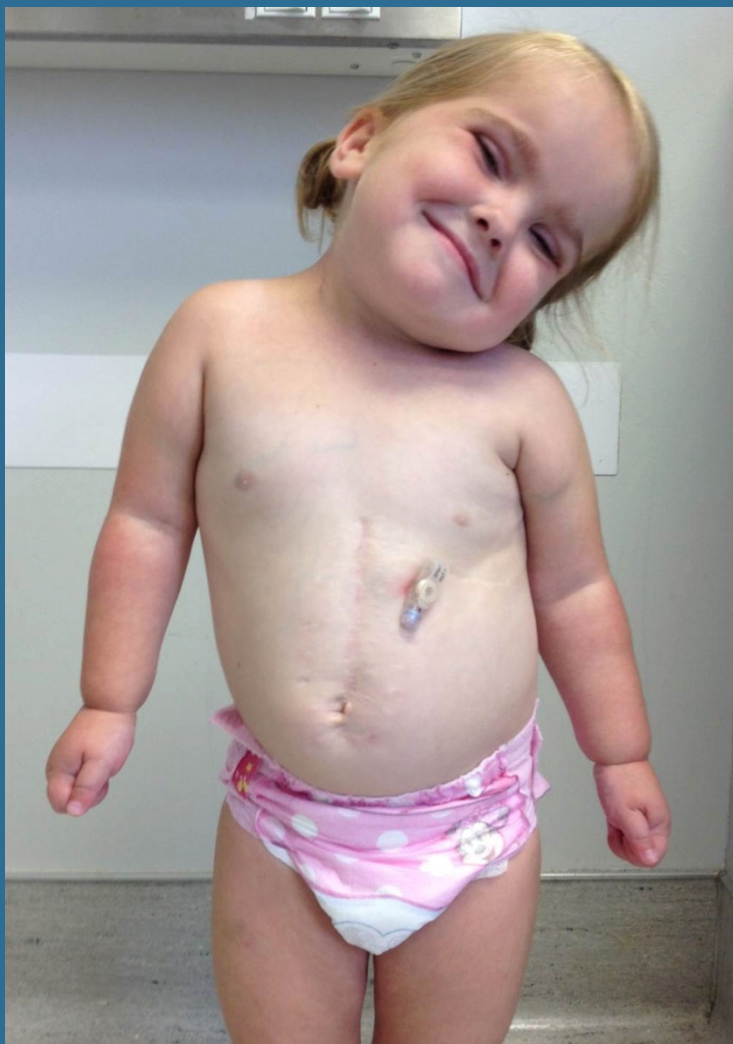## Exchanged to MCGR rod



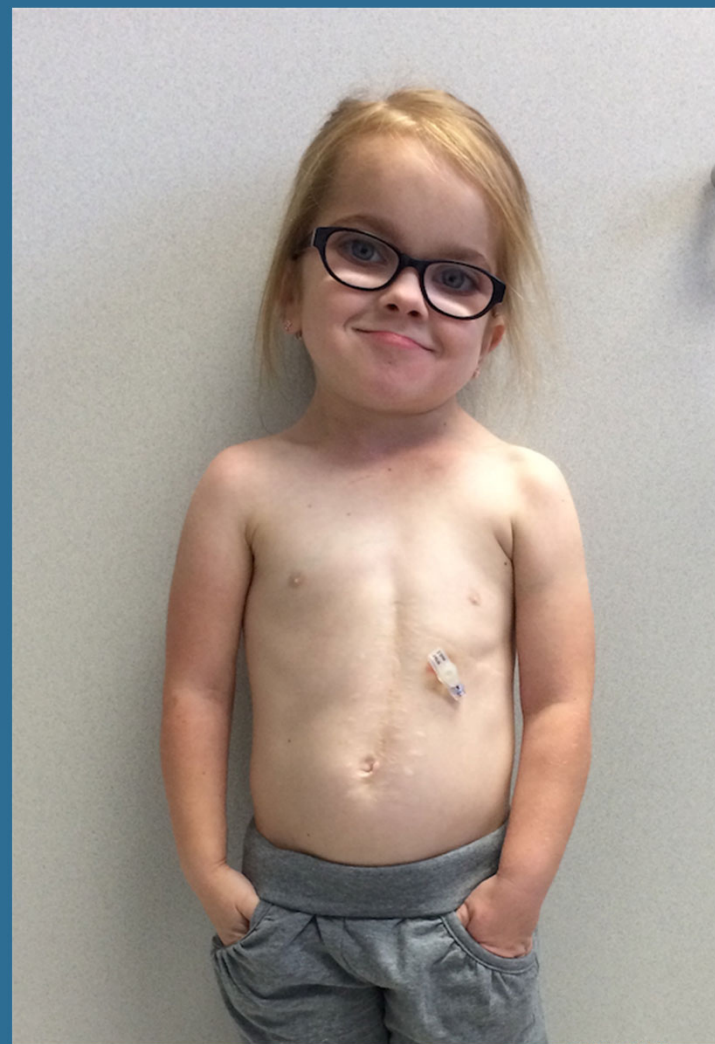USC University of  
Southern California

Children's  
Hospital  
LOS ANGELES  
CHILDREN'S  
ORTHOPAEDIC CENTER

## 4yo Pre-OP

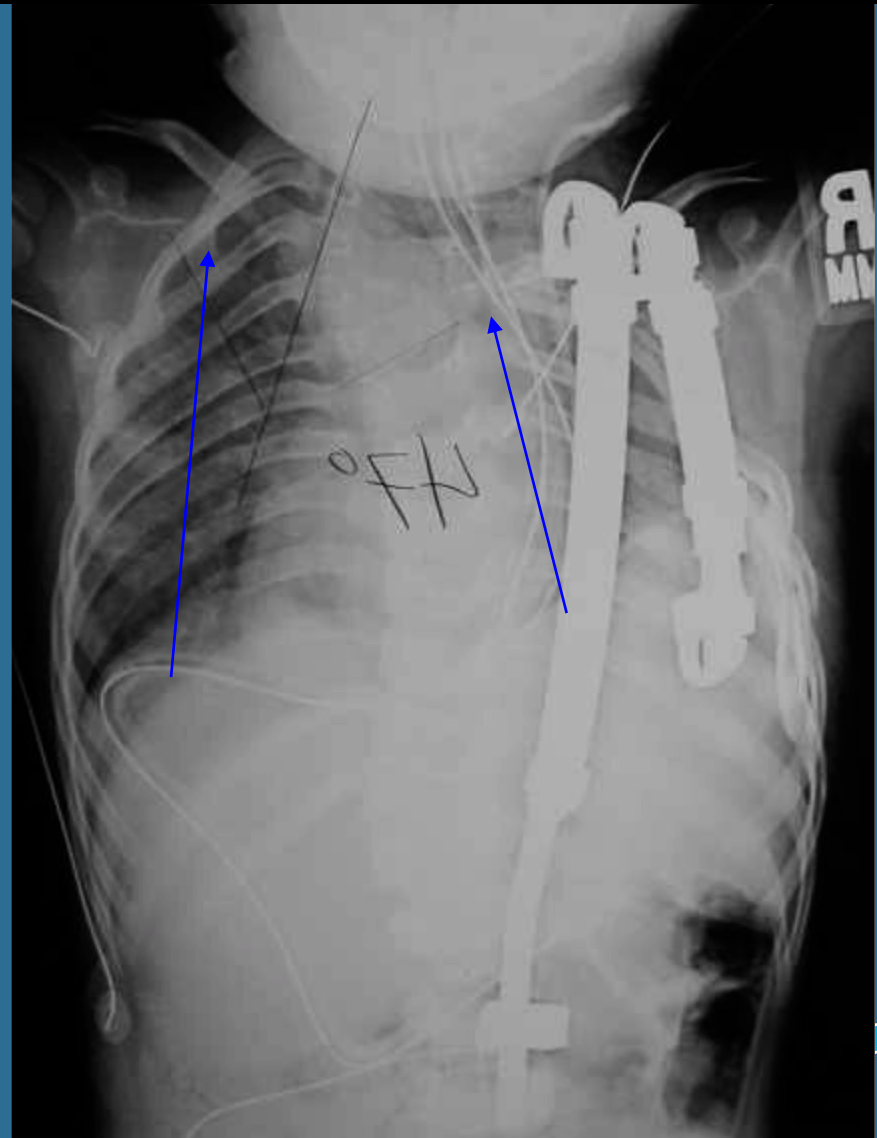
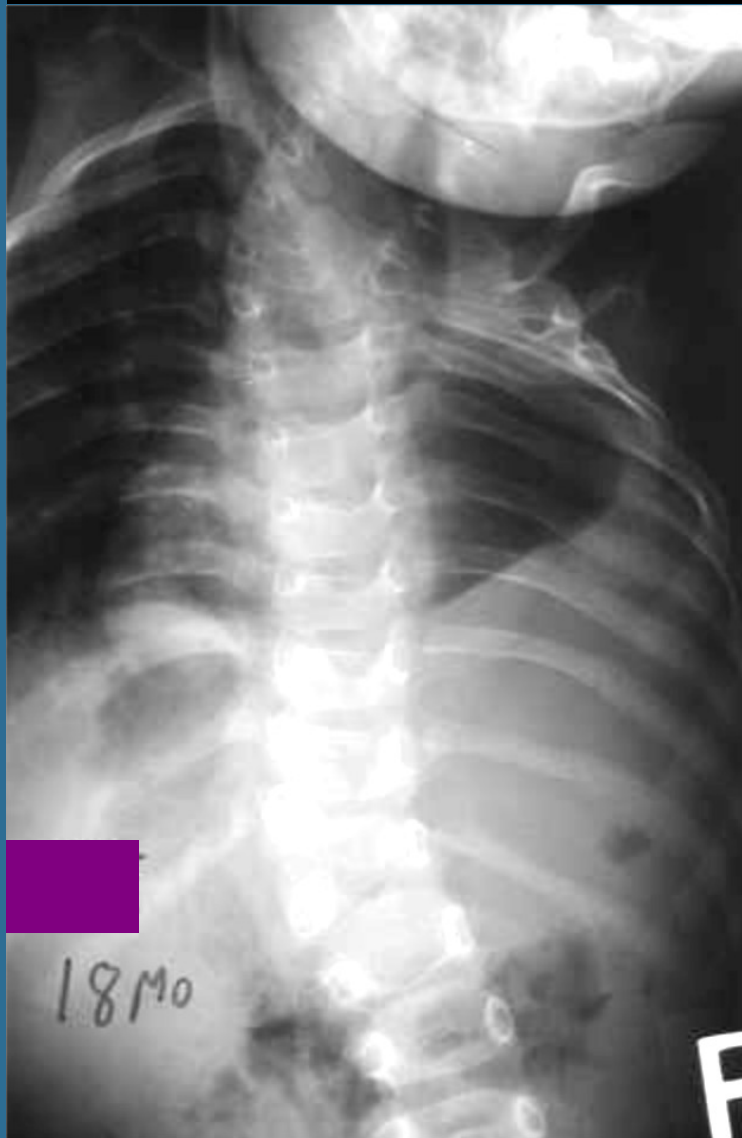

## 7yo Post-op

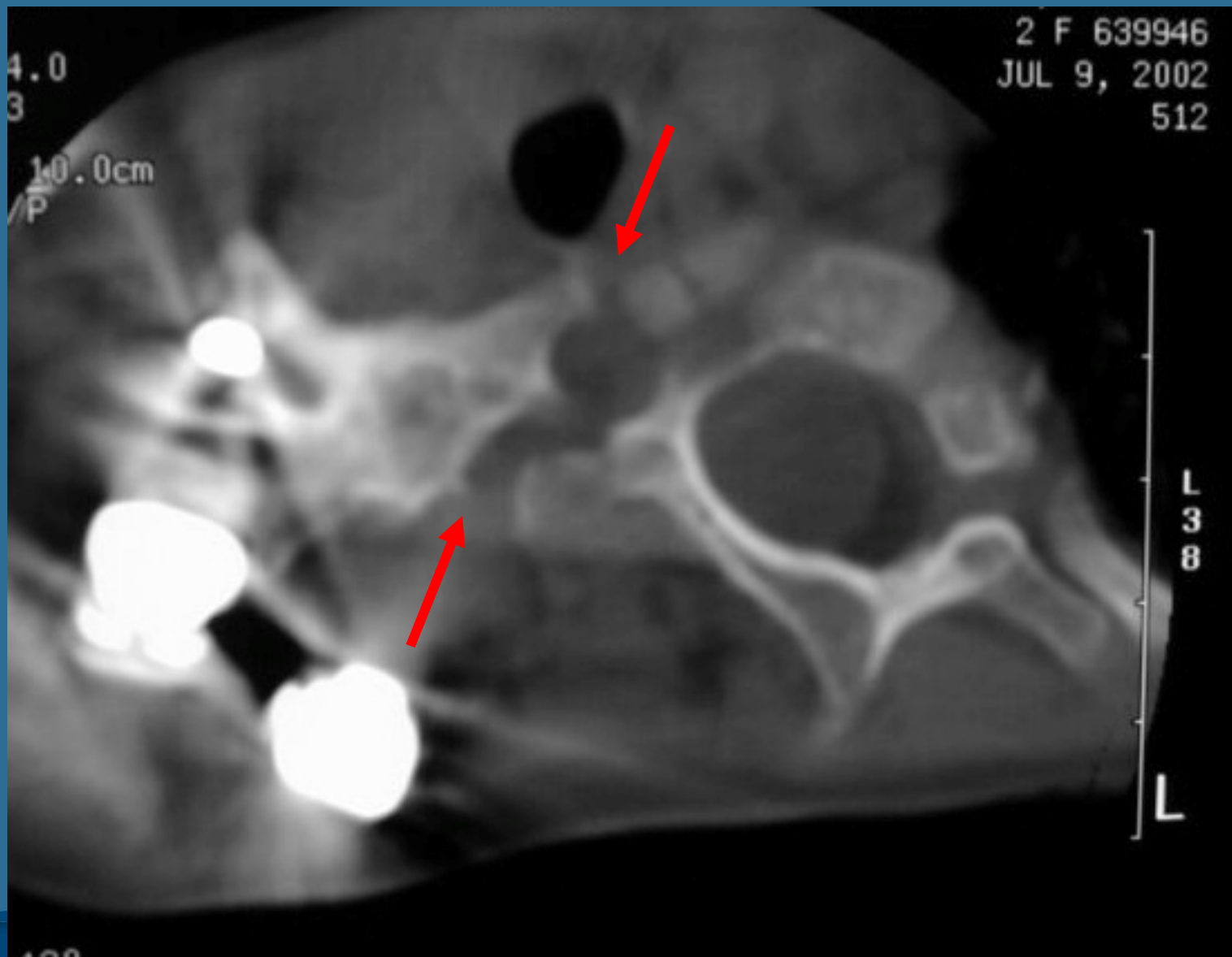


CHILDREN'S  
ORTHOPAEDIC CENTER

## Catastrophic failure: Avulsion of Rib Mass

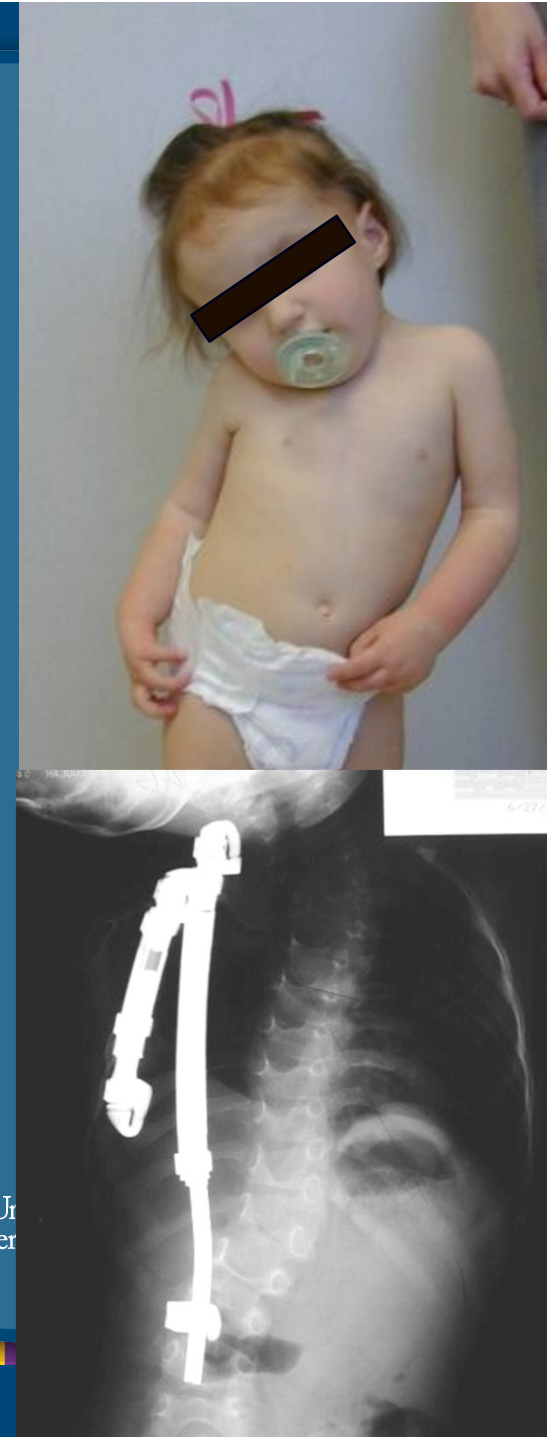


# Rib Mass Avulsion



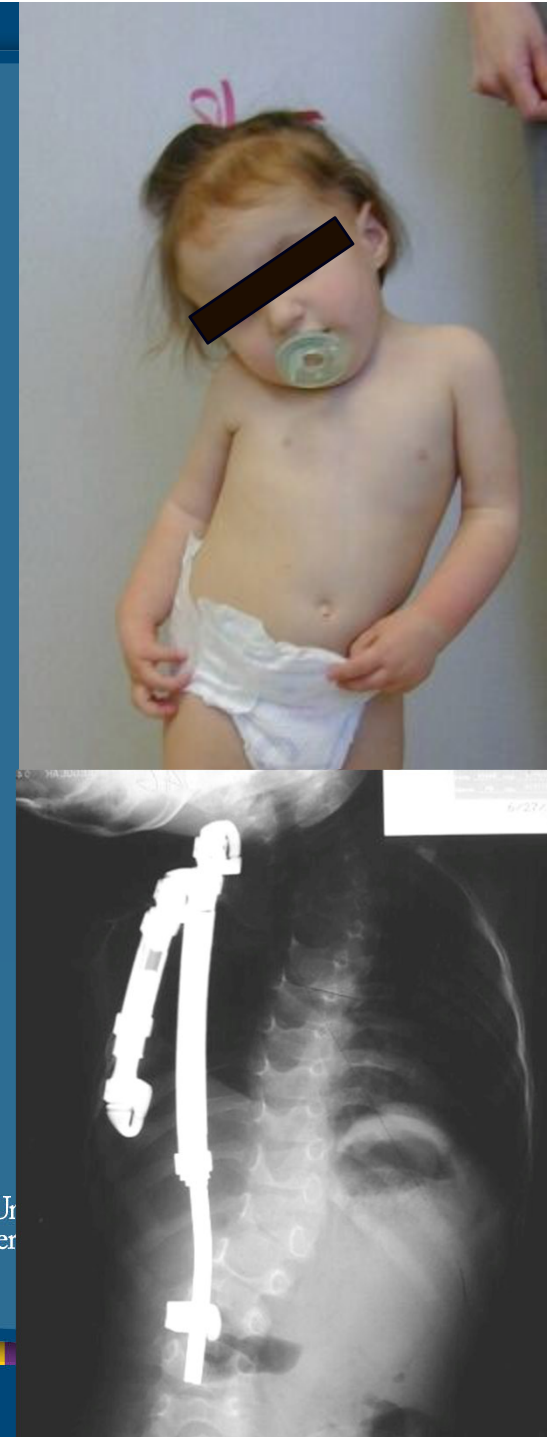
# Rib Avulsion: Salvage

- Step 1
  - Remove Devices
  - Fuse Avulsed ribs to spine



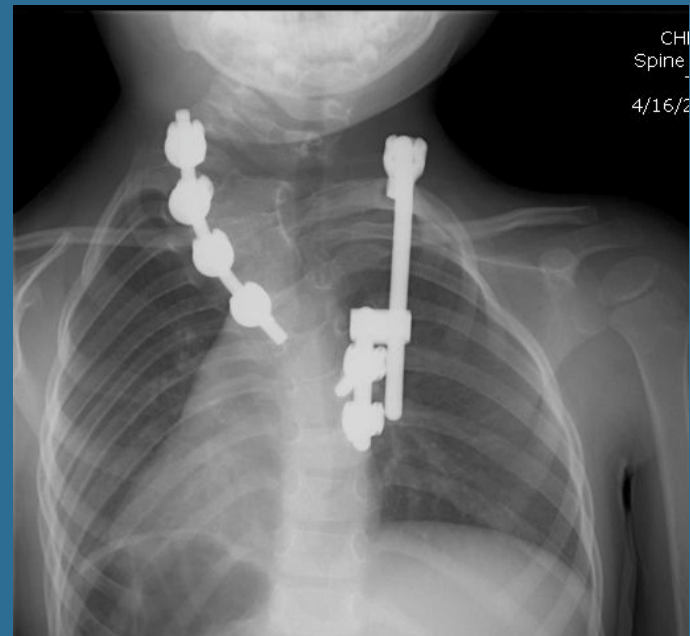
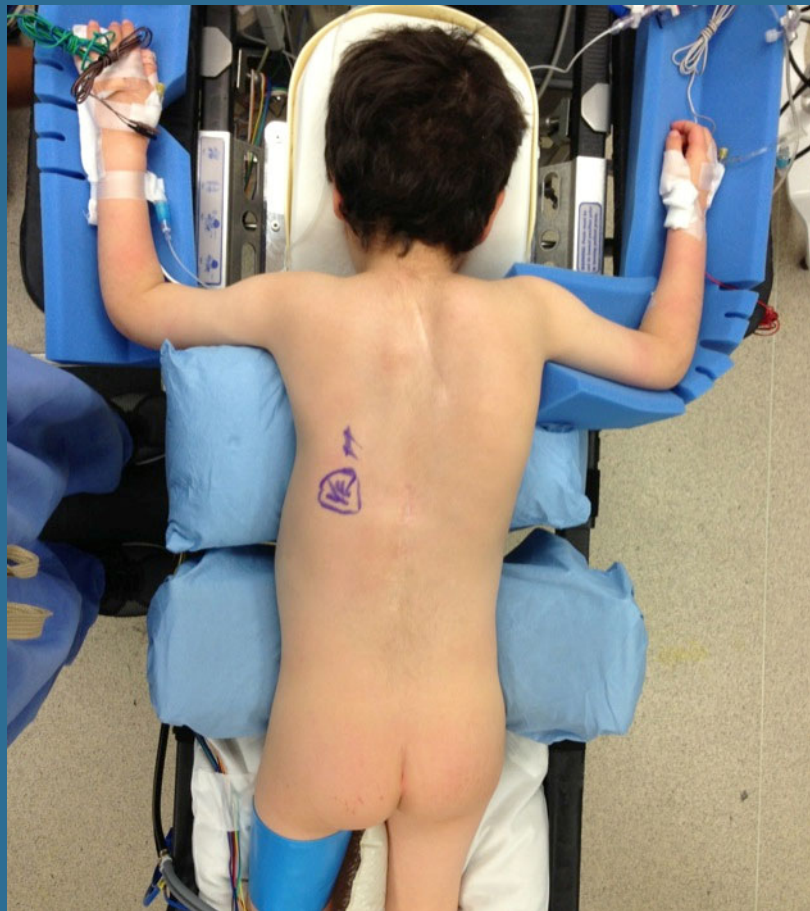# Rib Avulsion: Salvage

- Step 1
  - Remove Devices
  - Fuse Avulsed ribs to spine
- Step 2 (4-6 months)
  - Replace Device
  - Modest Distraction



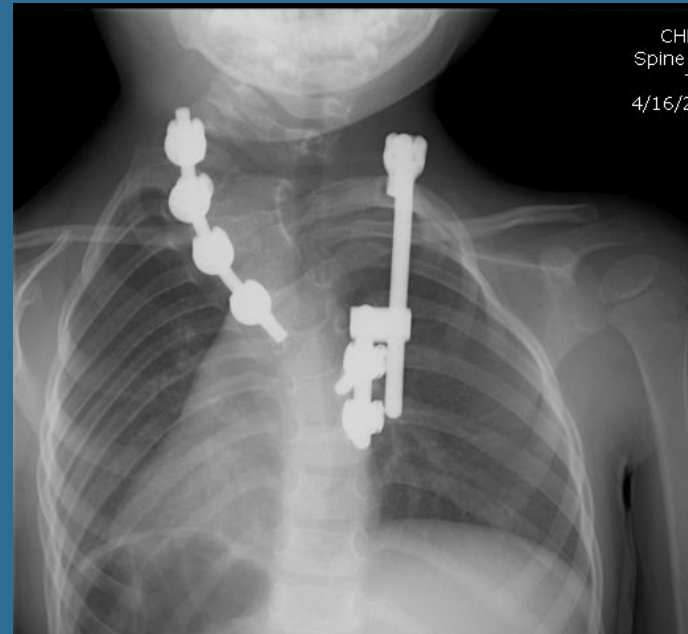
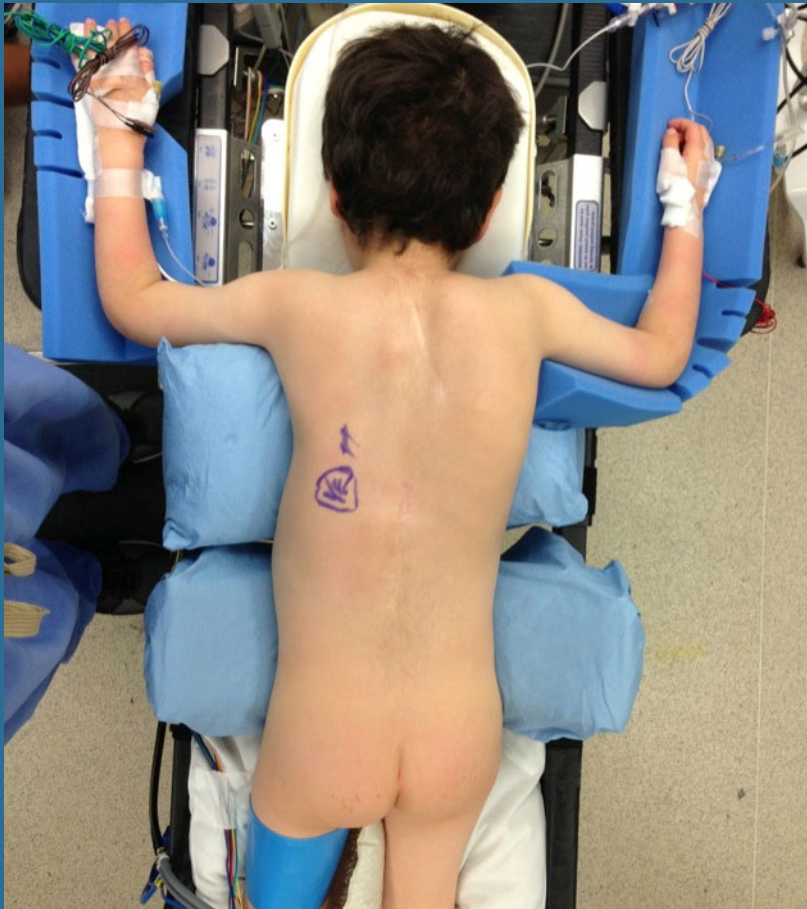# Lengthening complication

- Monitoring normal intra-op



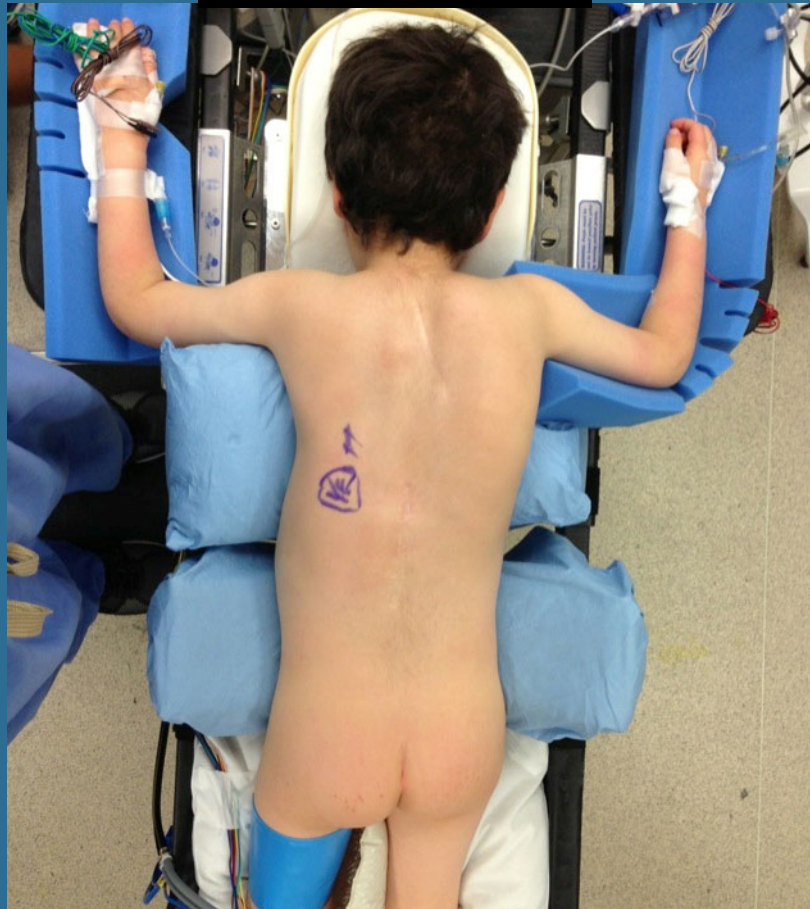# Lengthening complication

- Monitoring normal intra-op
- Arm pain post op when arm at side

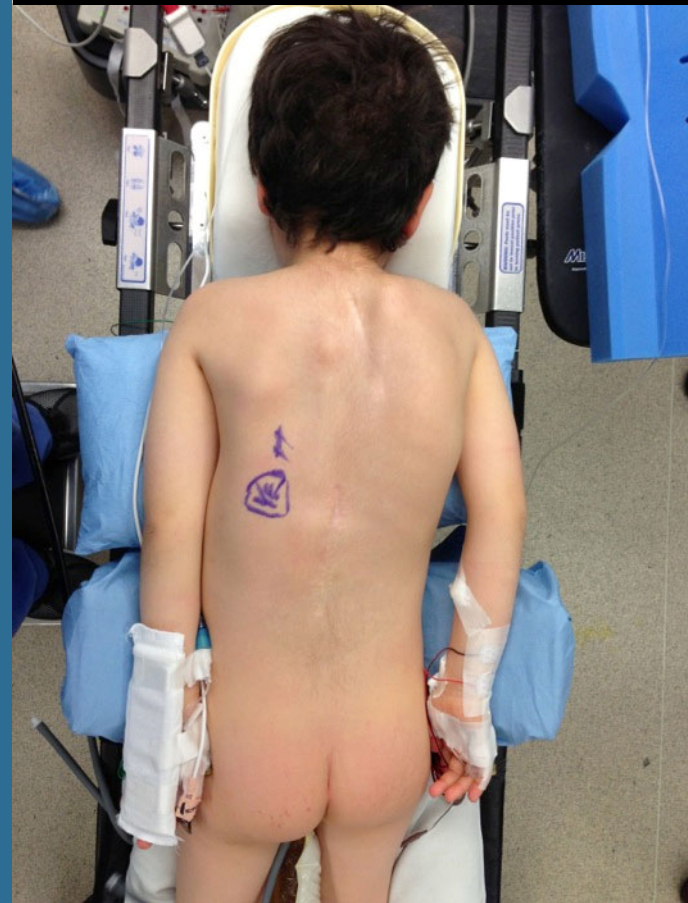

## Return to OR 3 days later

MEPs  
Normal

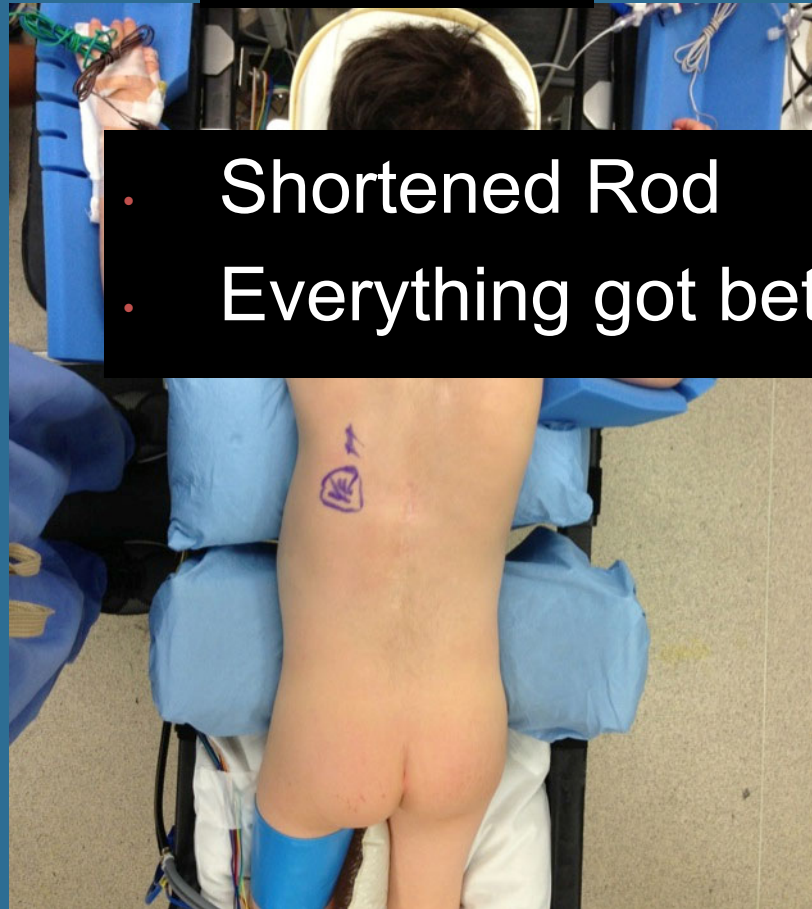

MEPs  
50% Diminished

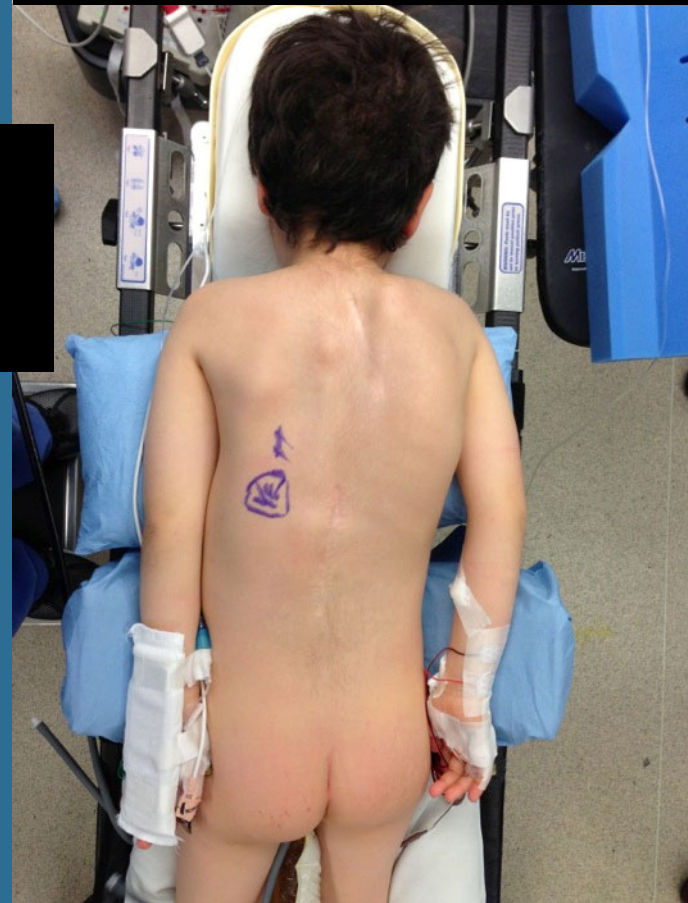

# Lesson: Lengthen with arms at side when on top rib

MEPs  
Normal

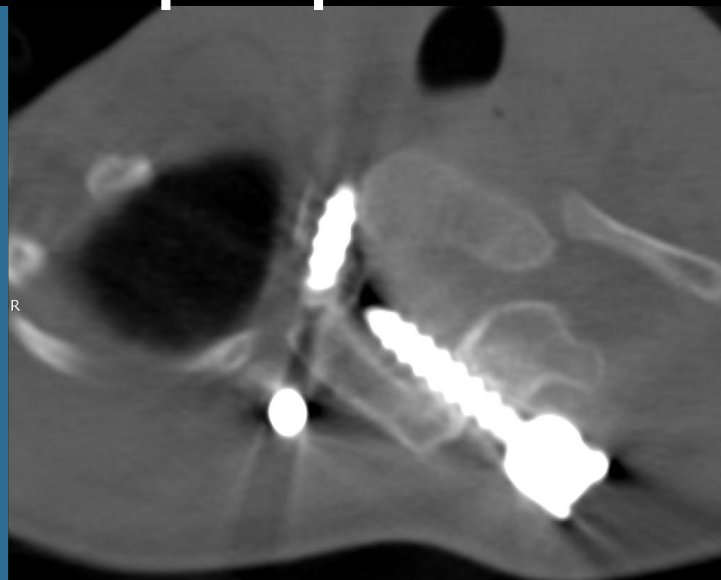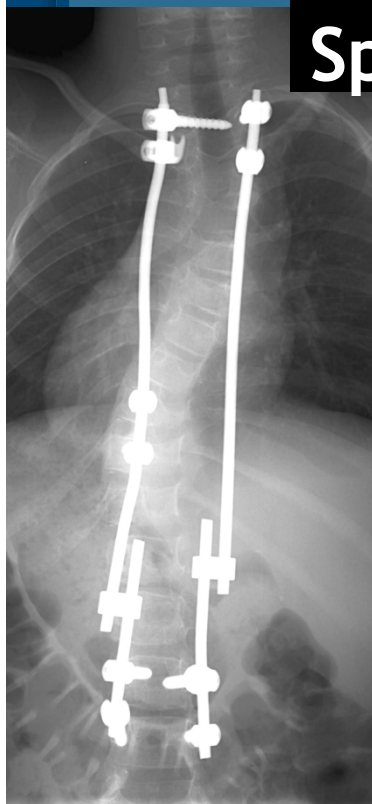


MEPs  
50% Diminished



# Catastrophic failure: Spinal Cord Injury Implant Migration

2 years after implant  
Spastic paraparesis



Kira Skaggs, JPO, 2013



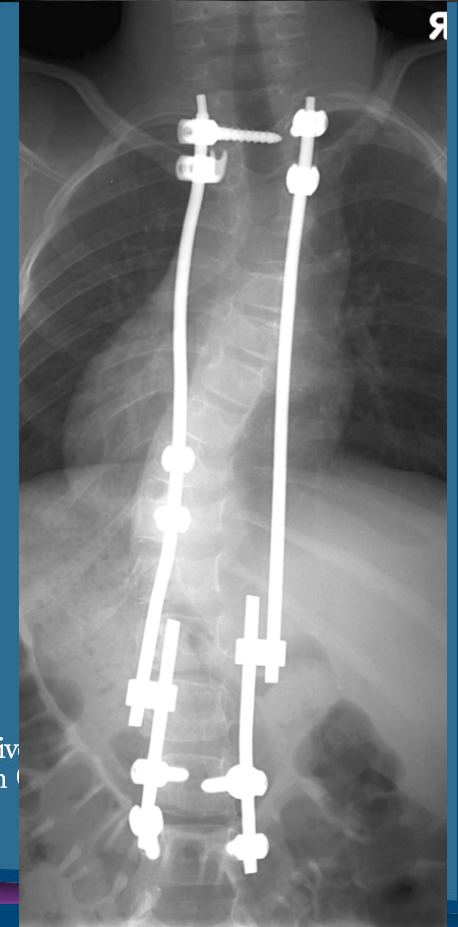
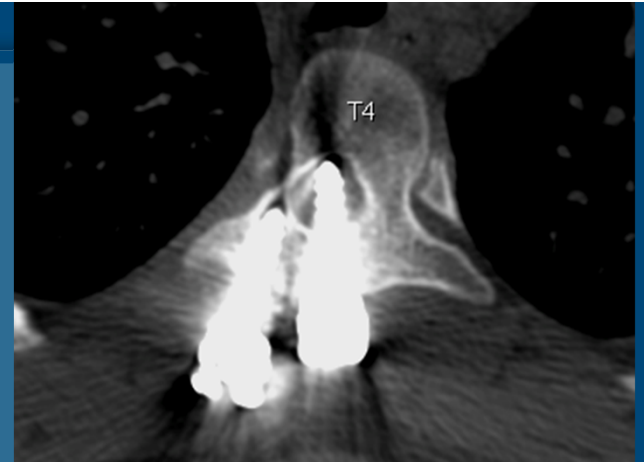
USC University of  
Southern California

Children's  
Hospital  
LOS ANGELES  
CHILDREN'S  
ORTHOPAEDIC CENTER

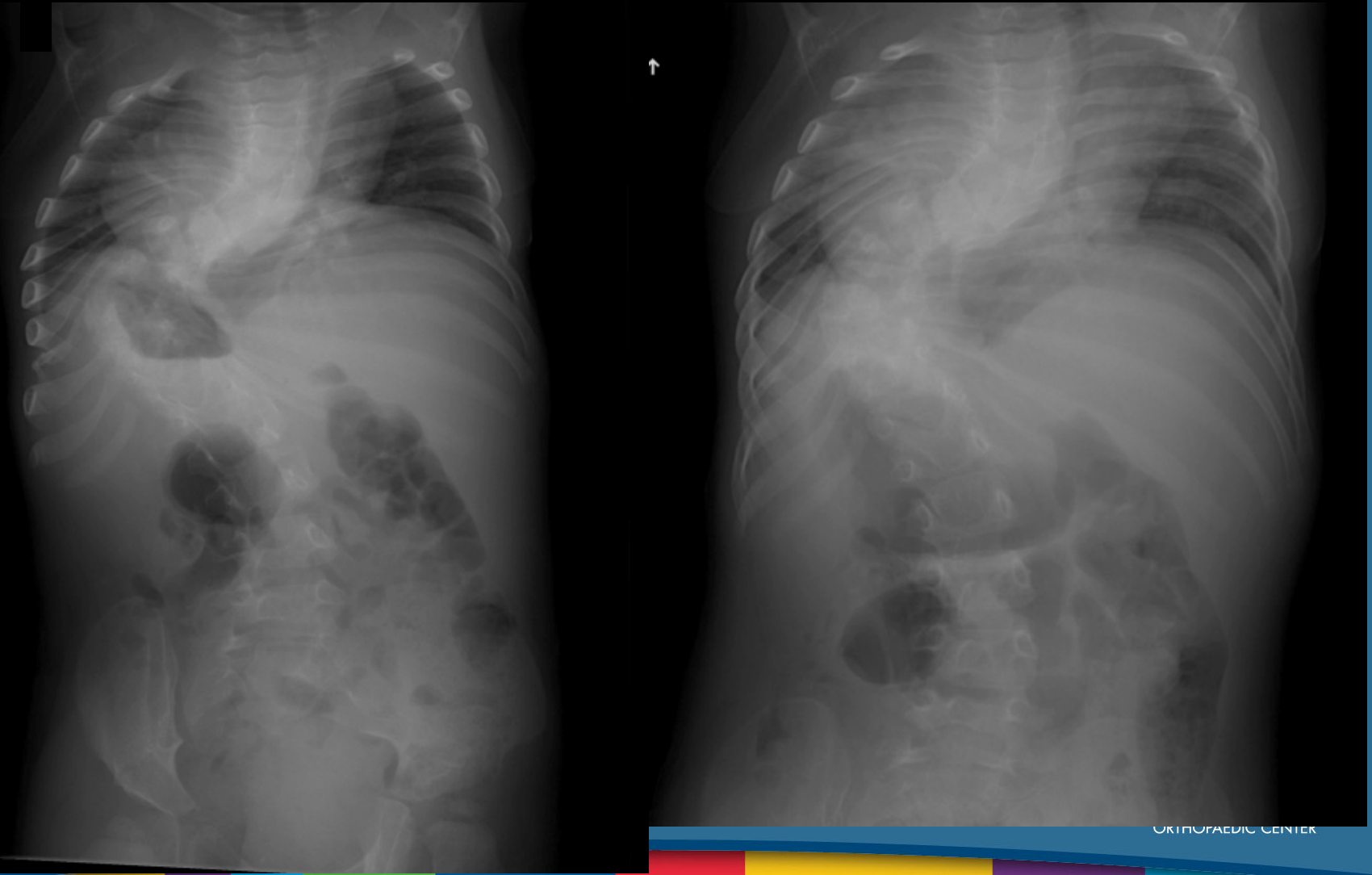
## 4 Cases Common Findings

- 1-2 pedicle screws at top
- > 5 vertebrae below top screws without other screws

**Lesson - if using screws at the top use at least 4 (then rods break)**

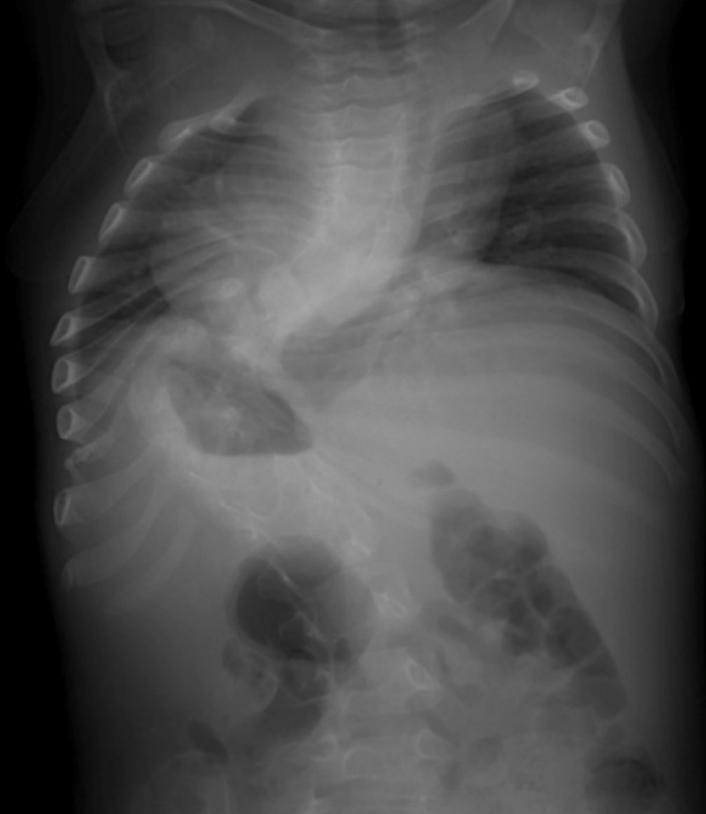

# Catastrophic failure: Death - Abdomen Compartment Syndrome

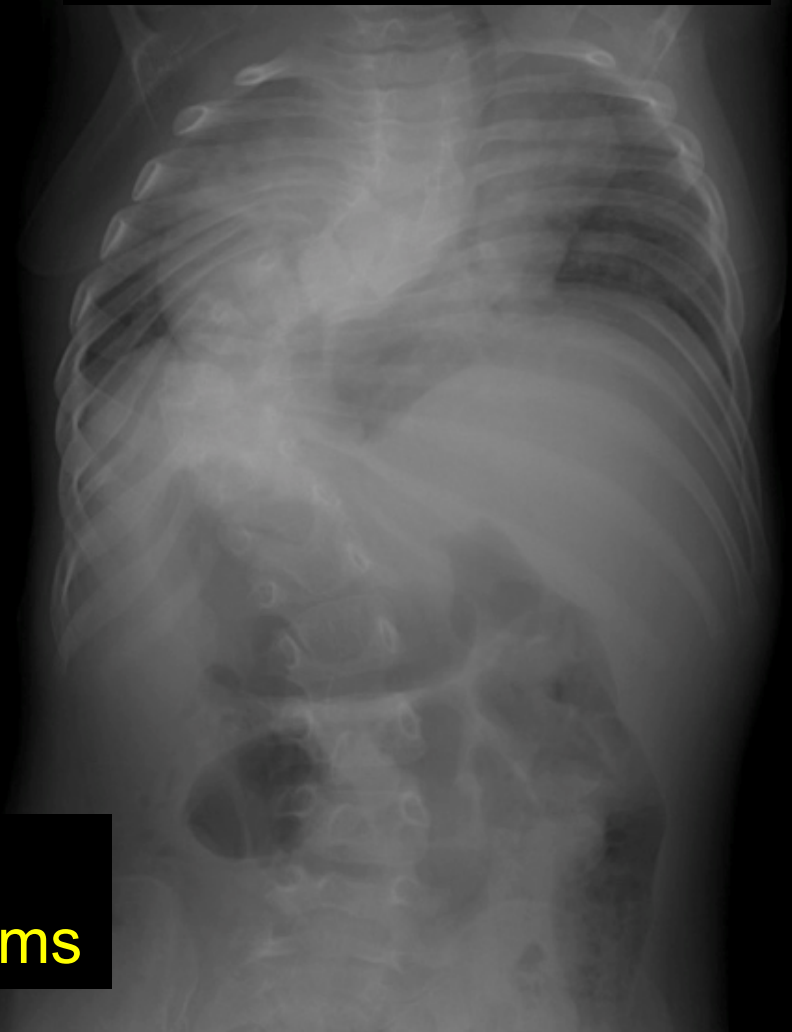

# 24 month old Progressive Rigid Kyphoscoliosis

Pre-op 114° scoliosis



Traction Film - 91°

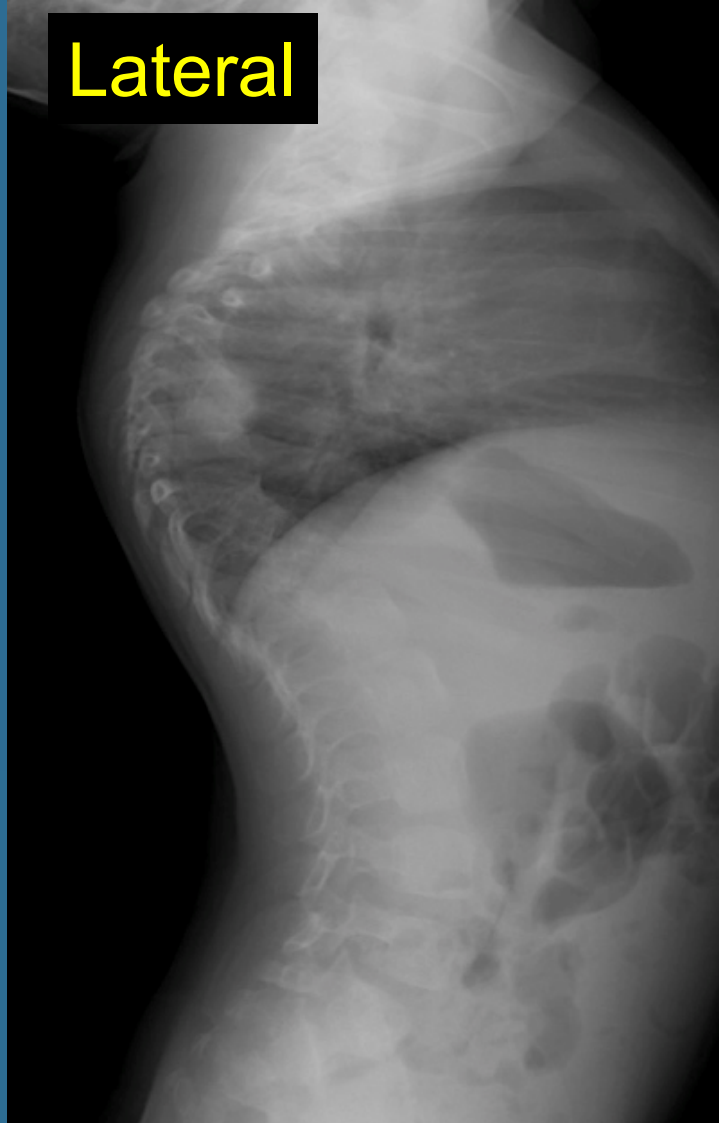


MRI negative  
No clear cardiopulmonary problems

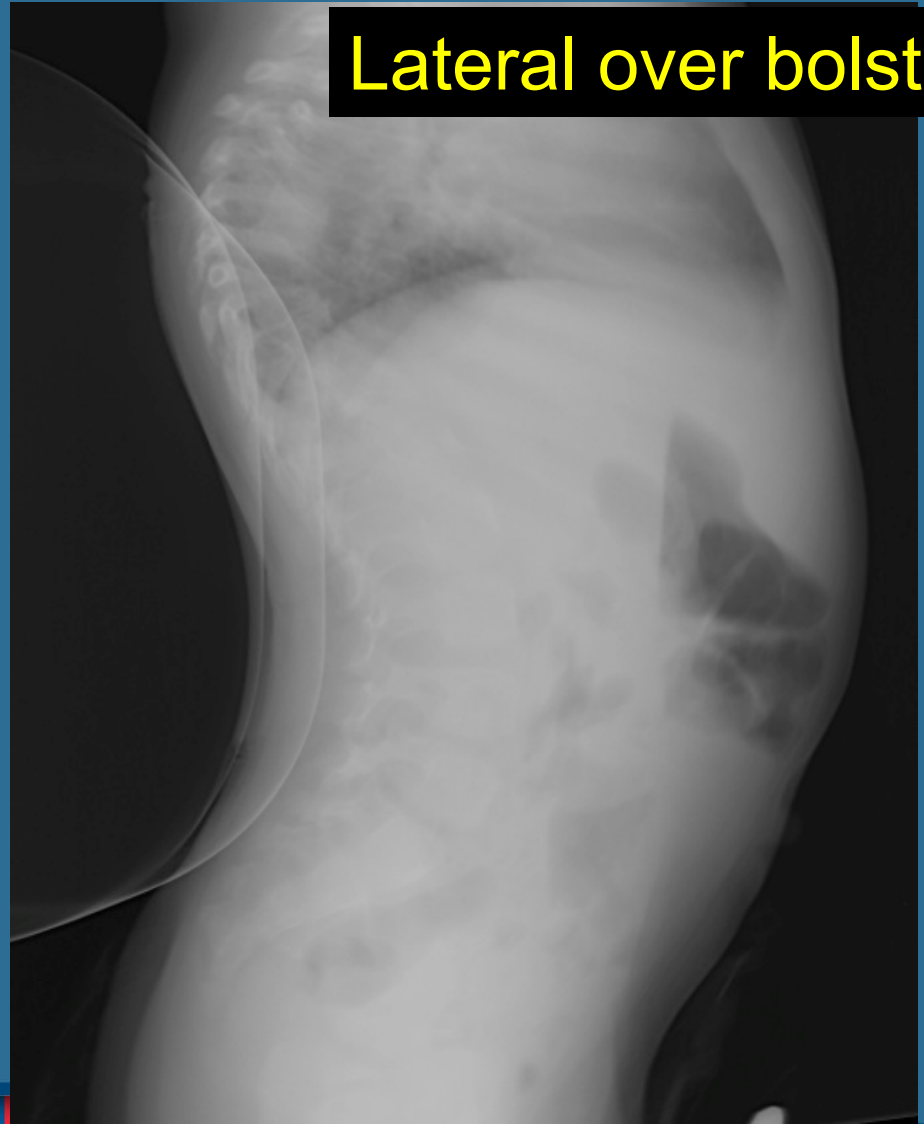ORTHOPAEDIC CENTER

# Rigid Kyphosis

Lateral



Lateral over bolster



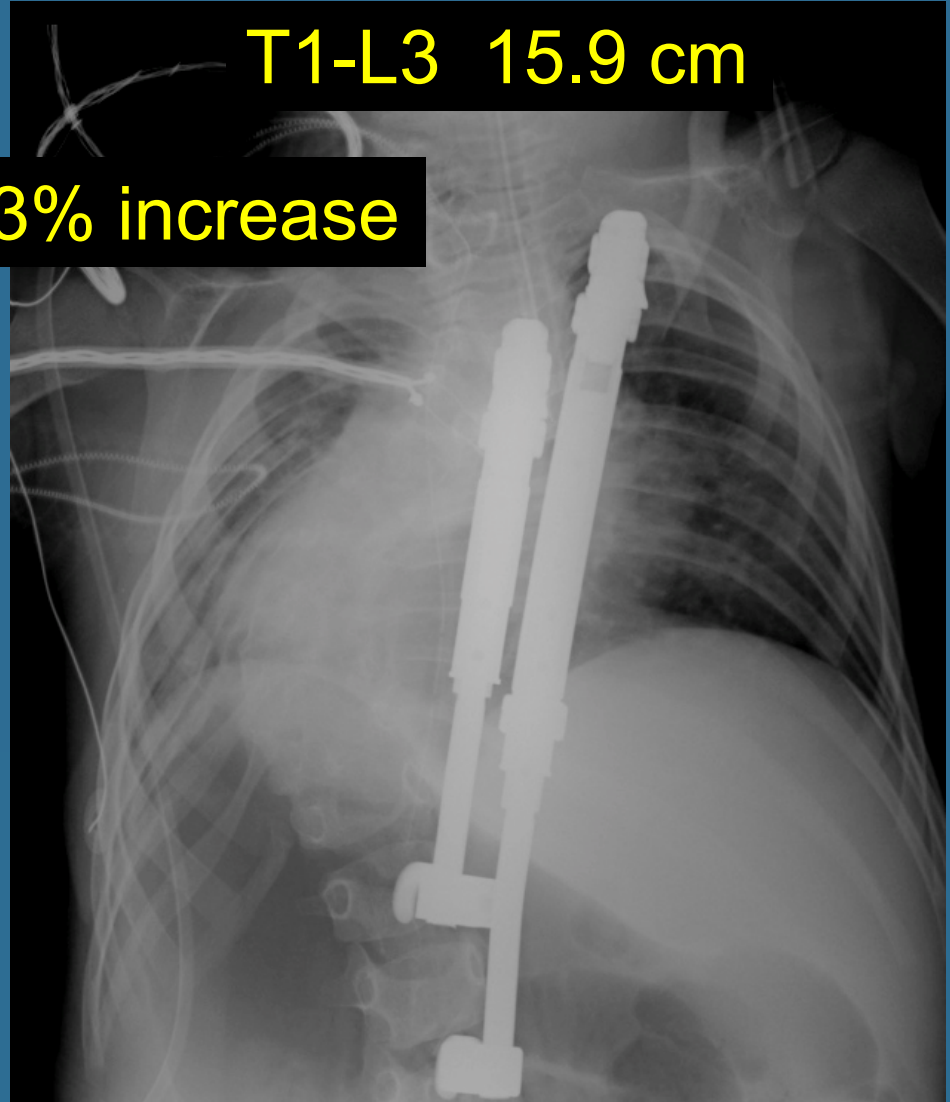
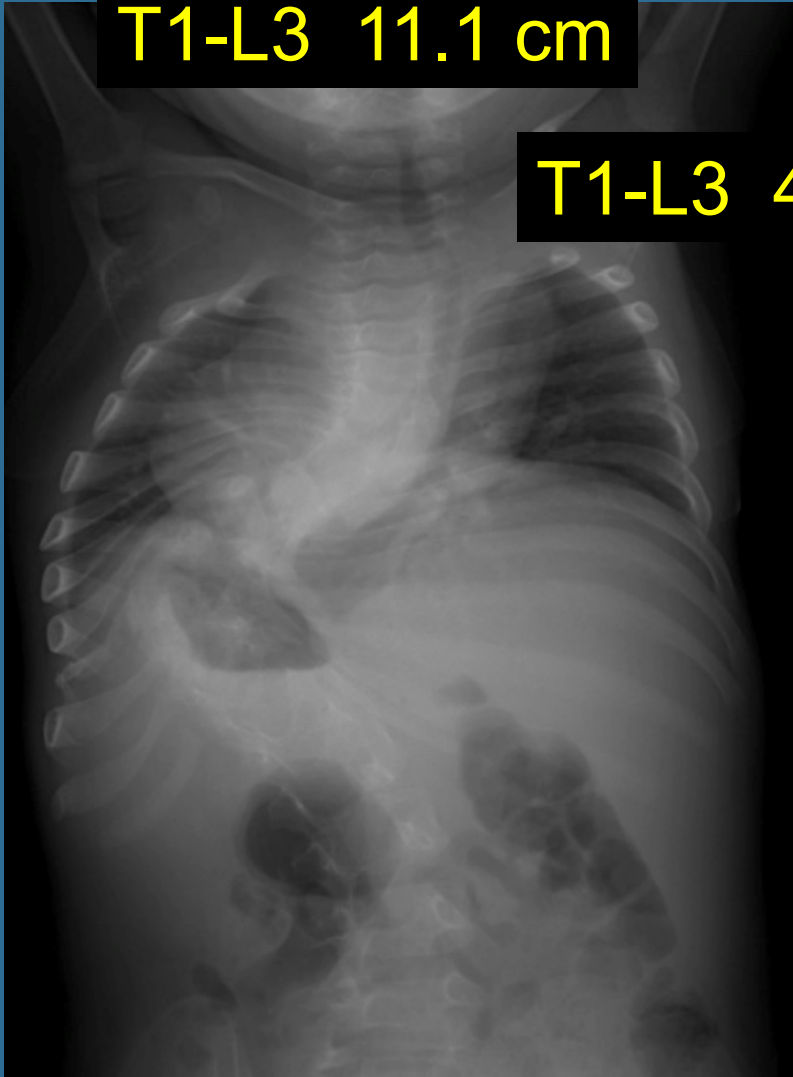
# VEPTR placed without complication

114° → 67°

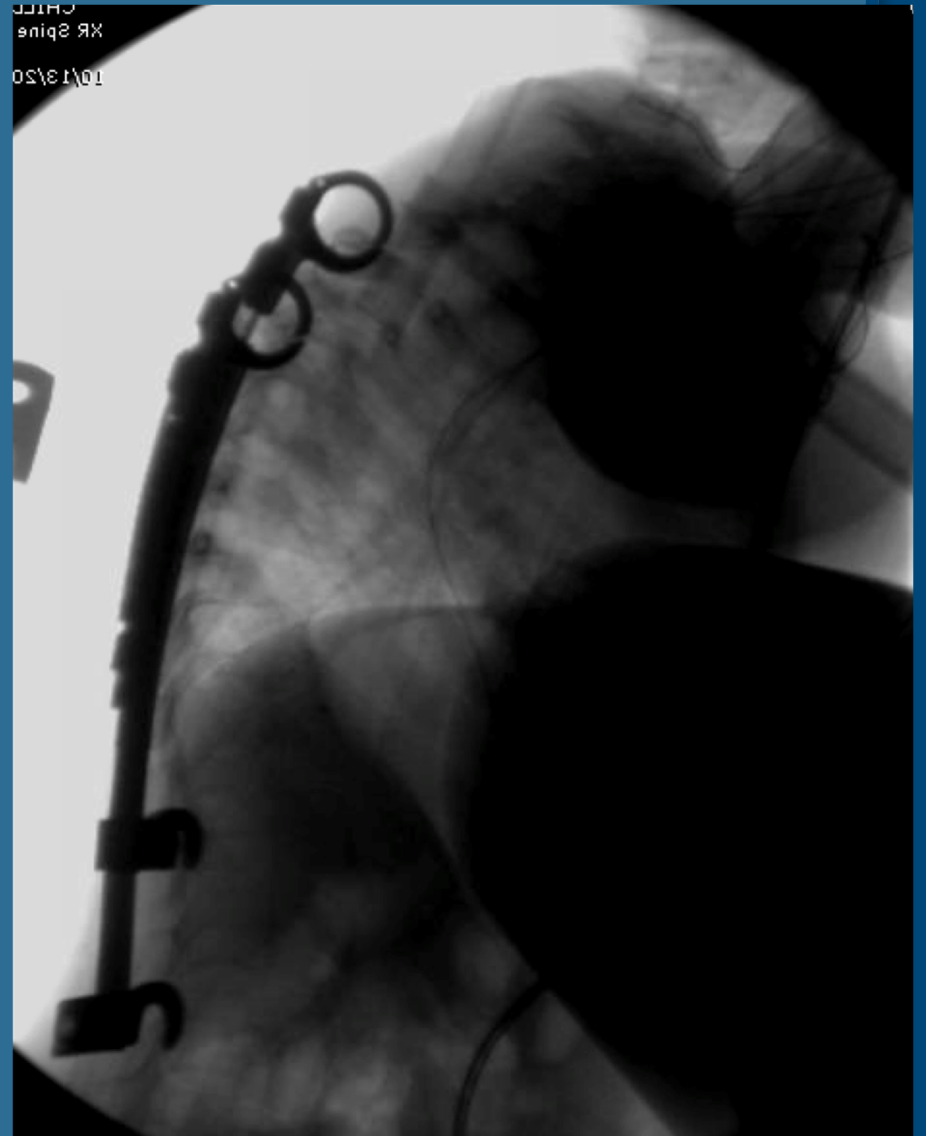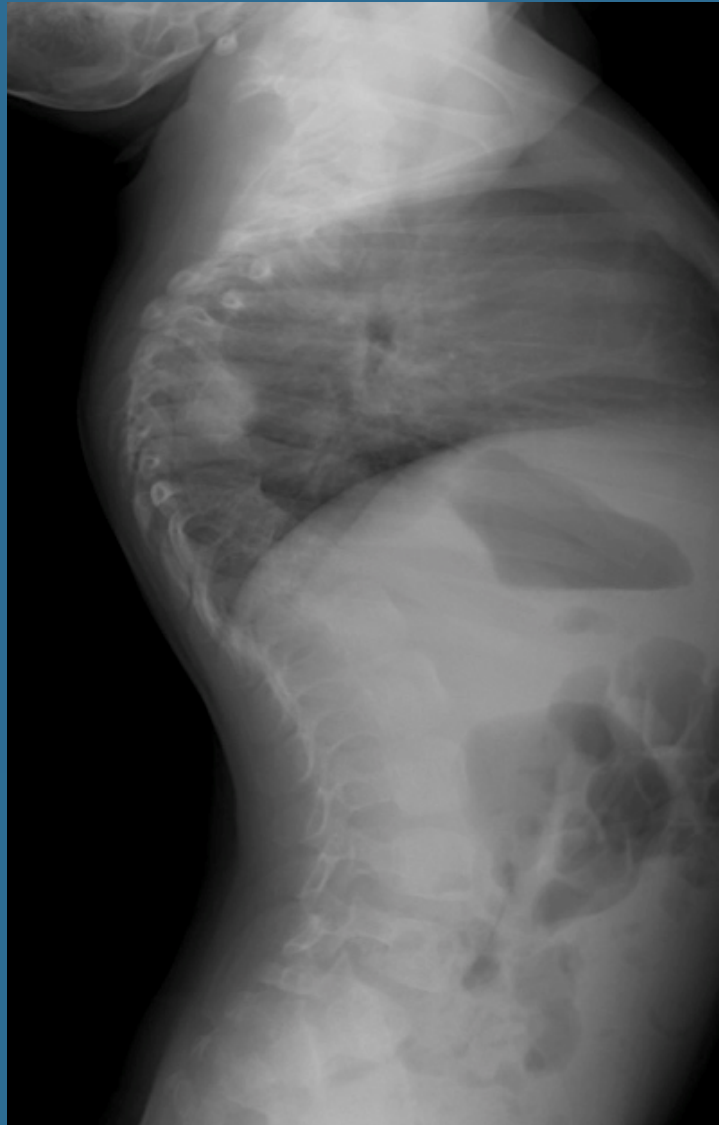
T1-L3 11.1 cm

T1-L3 15.9 cm

T1-L3 43% increase

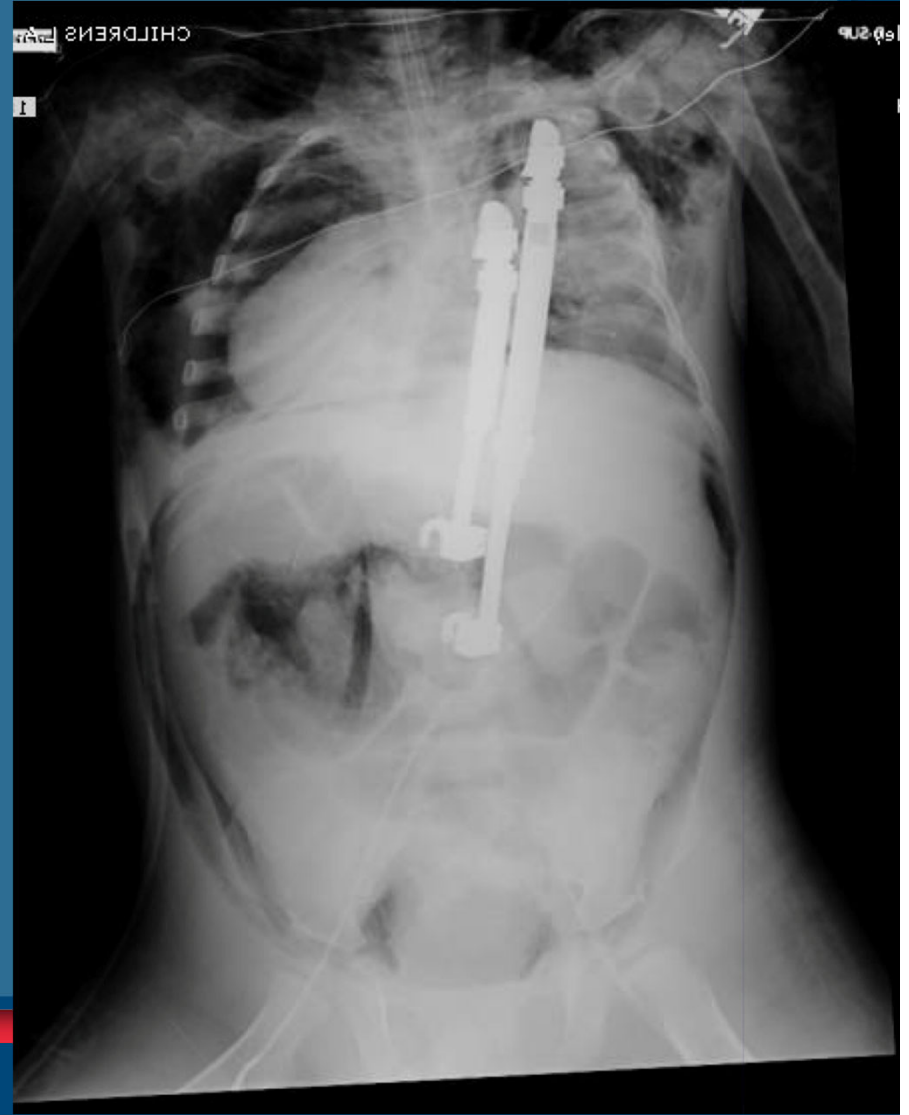
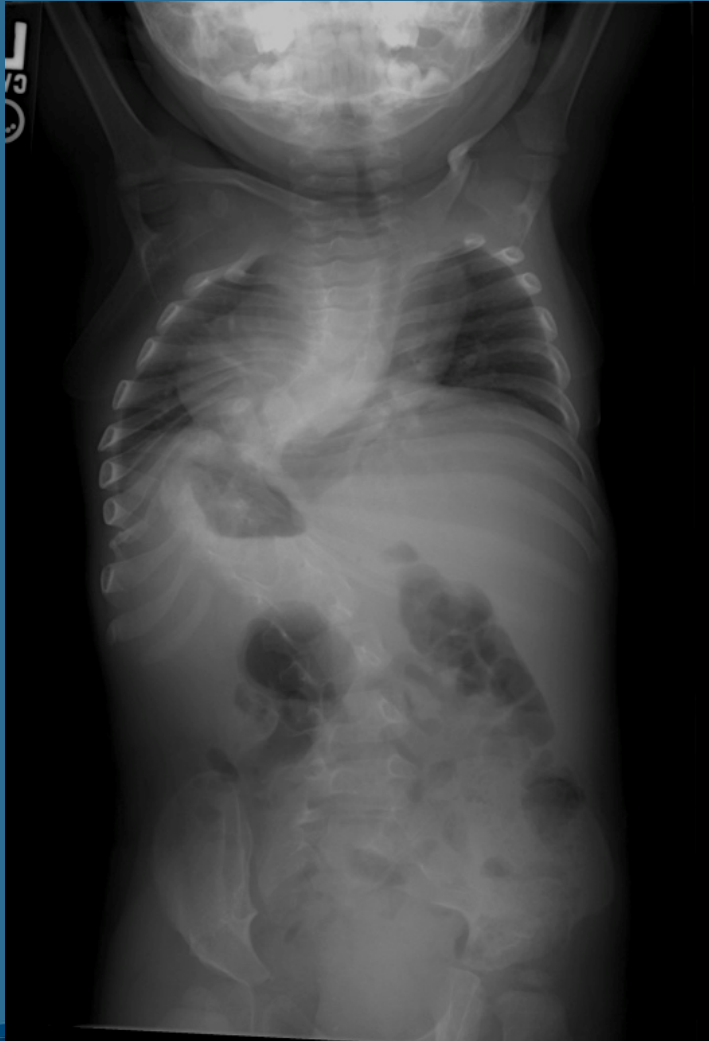

# Kyphosis Improved



**POD 1-5**

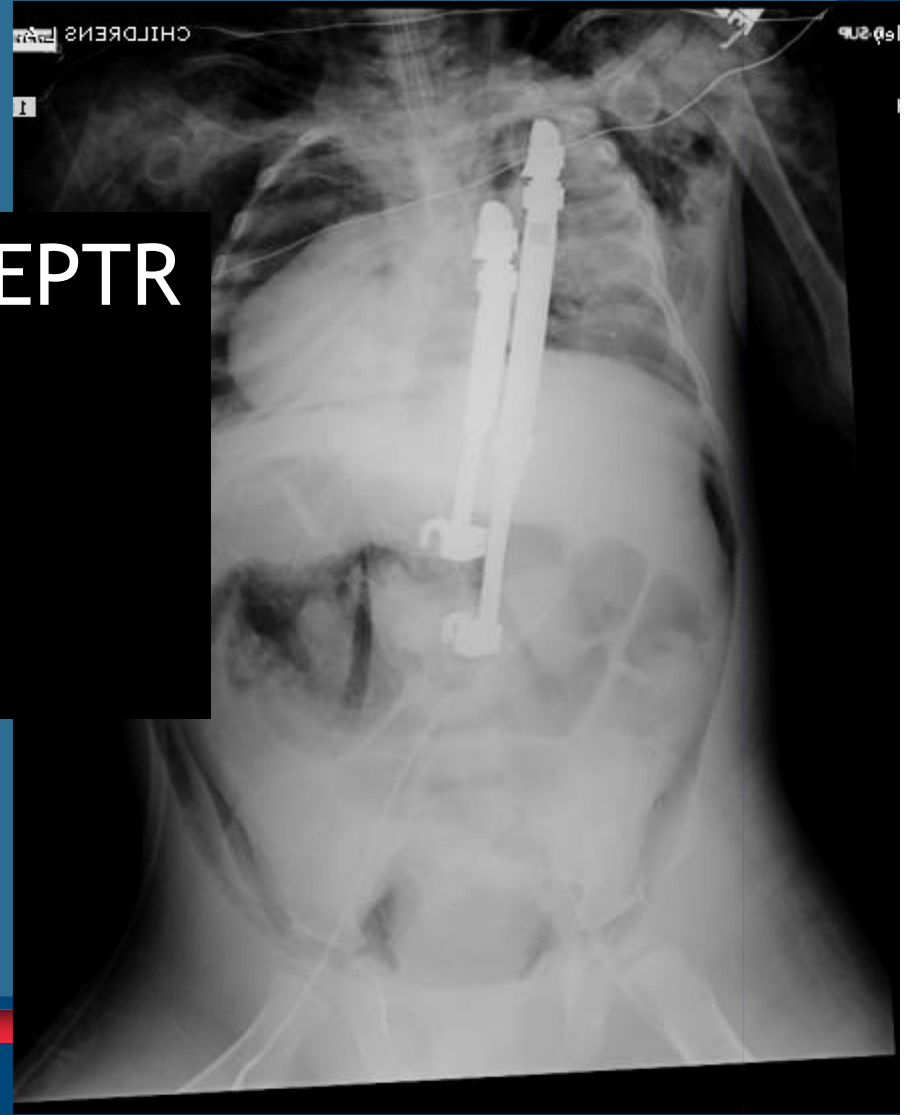
**distended rigid abdomen, LE swelling,  
decreased cardiopulmonary function,**



## POD 1-5

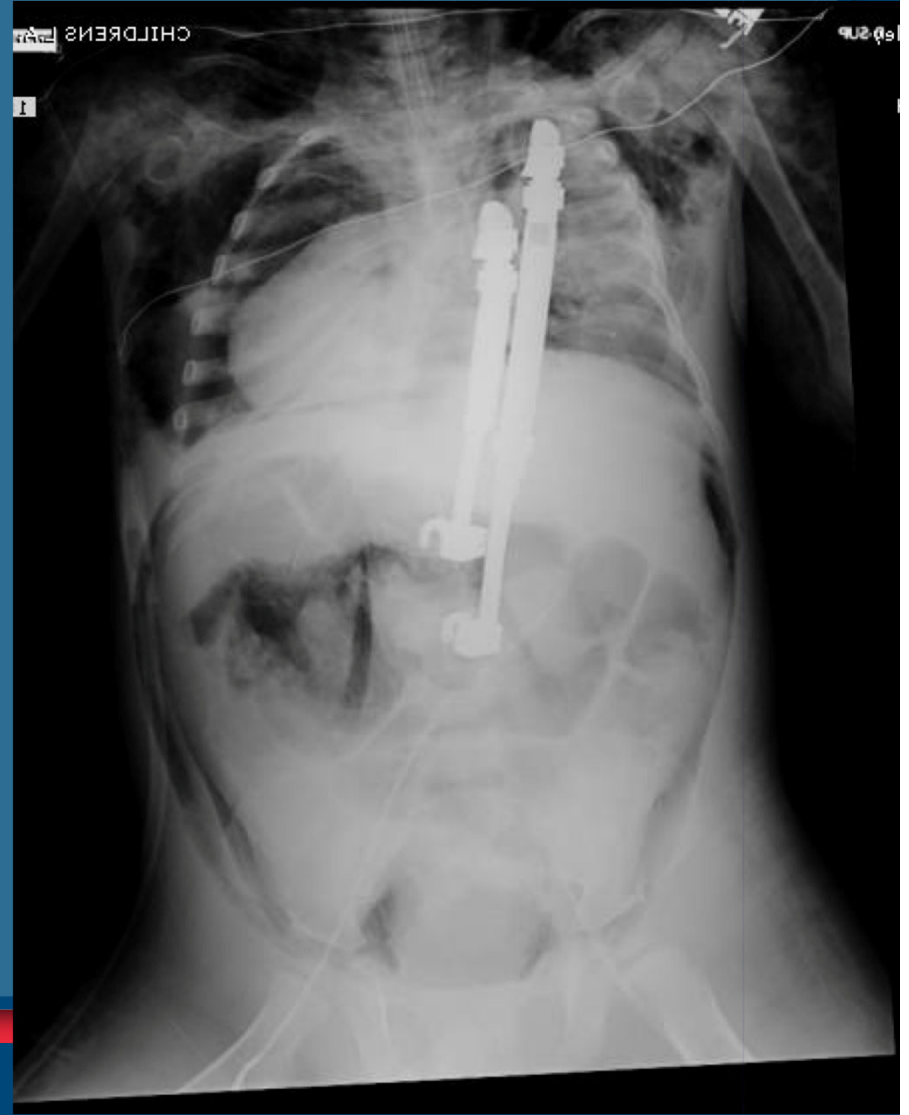
distended rigid abdomen, LE swelling,  
decreased cardiopulmonary function,

- I wanted to remove VEPTR
- Consensus  
“Too sick for surgery”



# Abdominal Compartment Syndrome

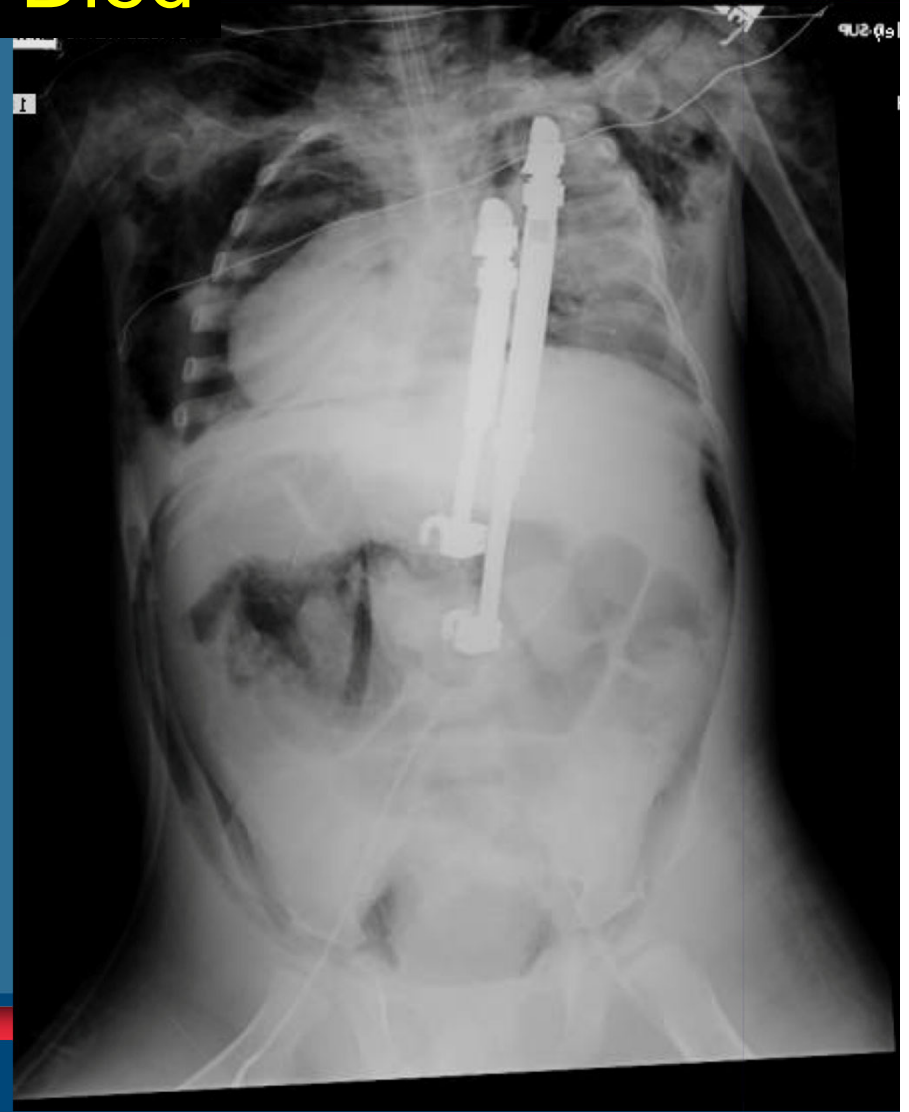
- Intra-abdominal hypertension
- ↓ tidal volume
- ↓ urine output from  
↓ renal perfusion → renal failure
- ↓ cardiac output



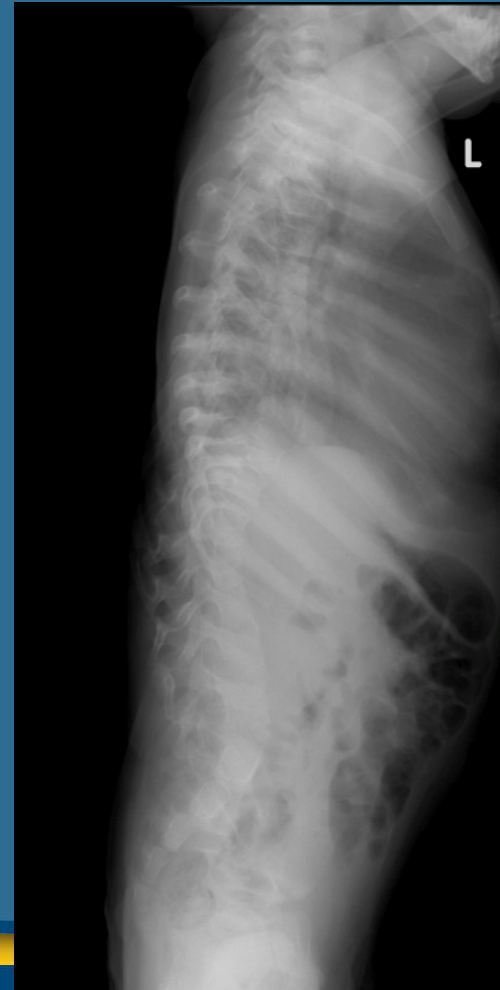
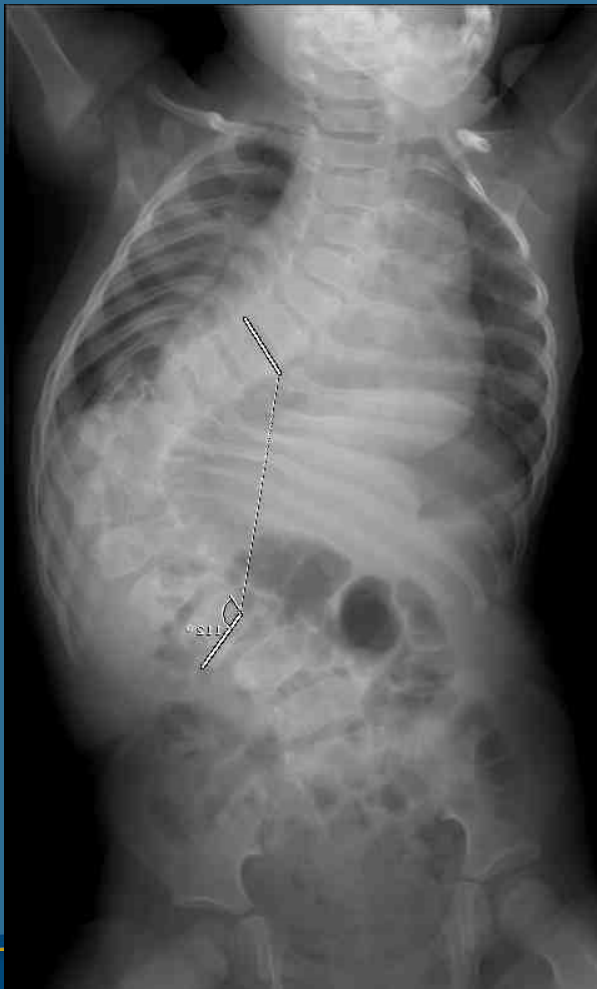
# Abdominal Compartment Syndrome

**Patient Died**

- Intra-abdominal hypertension
- ↓ tidal volume
- ↓ urine output from  
↓ renal perfusion → renal failure
- ↓ cardiac output

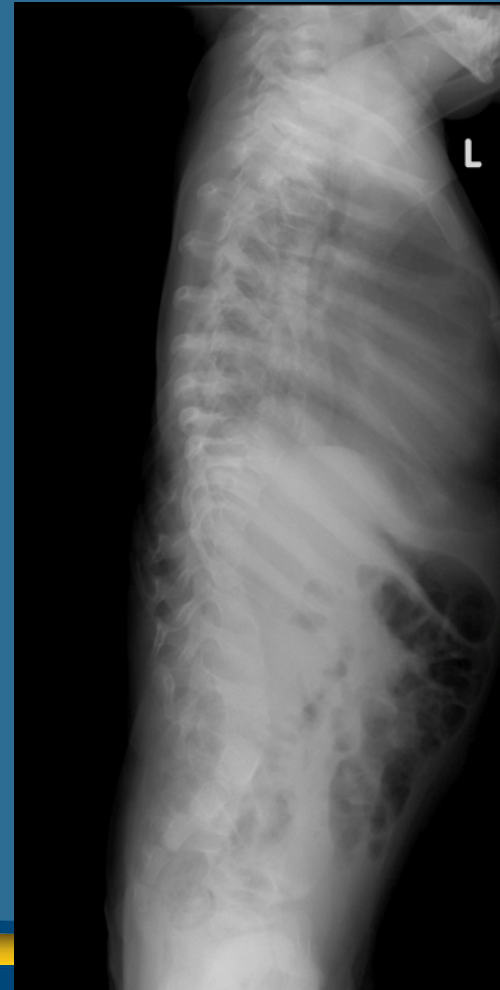
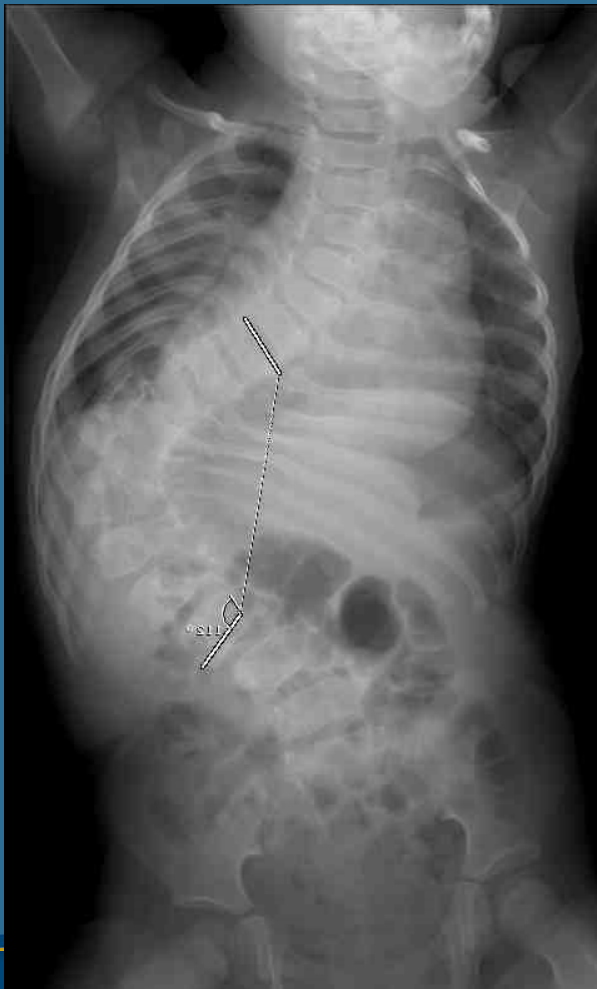


# Catastrophic failure: Myocardial Infarction



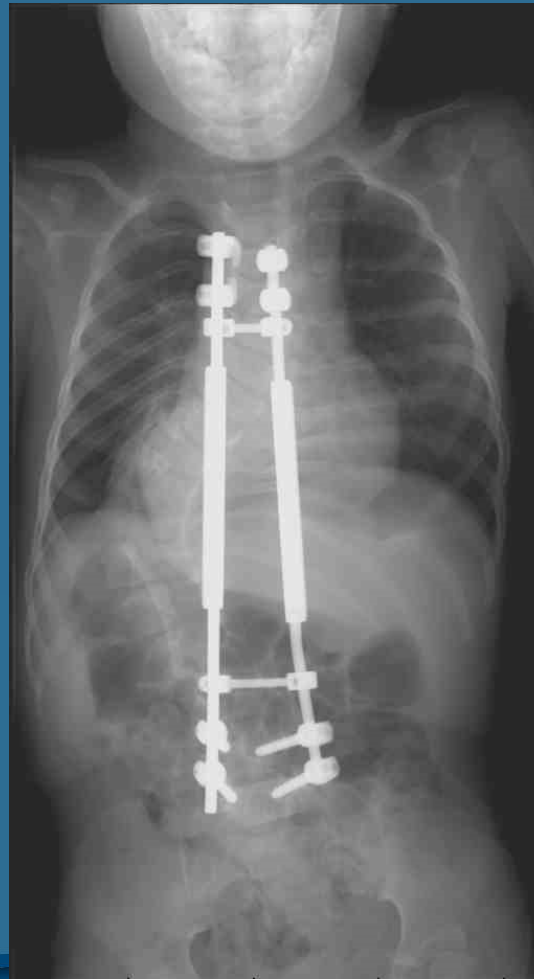
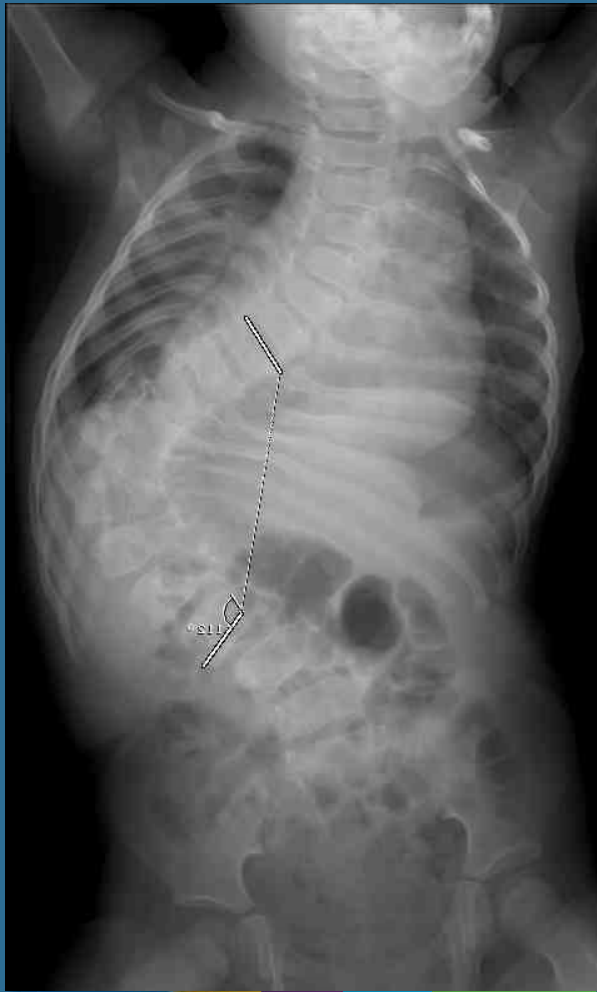
# 16 mo old girl Marfans

## 111 deg progressive scoliosis



112°

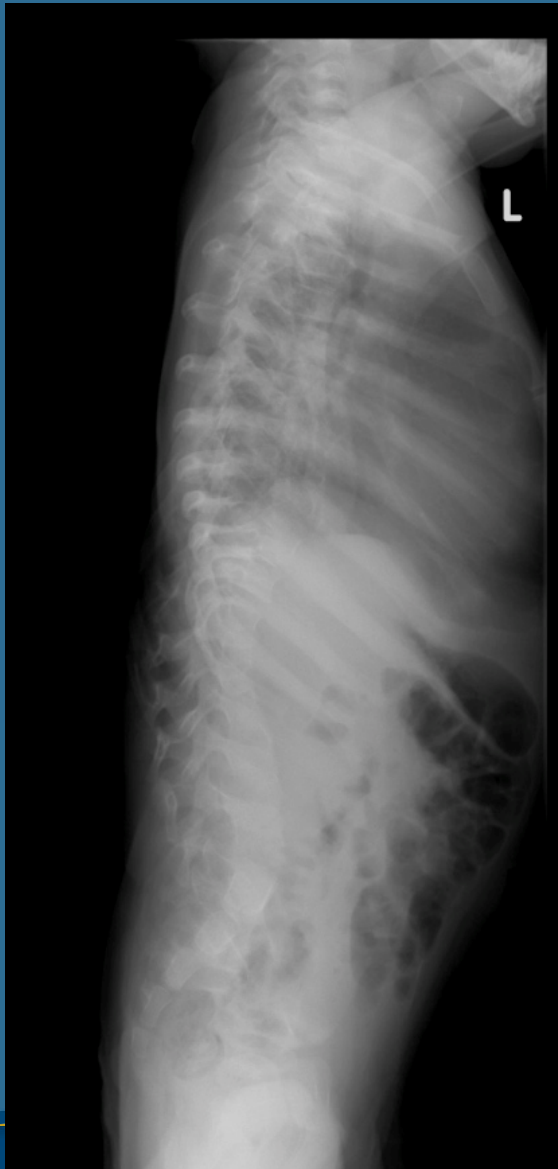## Primary implant



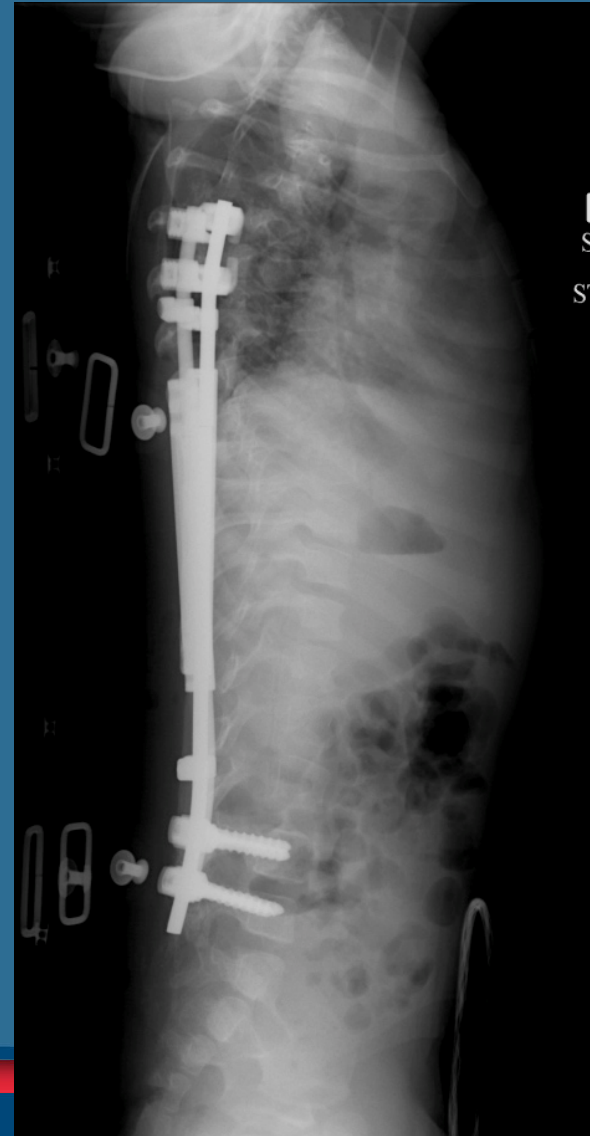USC University of  
Southern California

Children's  
Hospital  
LOS ANGELES  
CHILDREN'S  
ORTHOPAEDIC CENTER

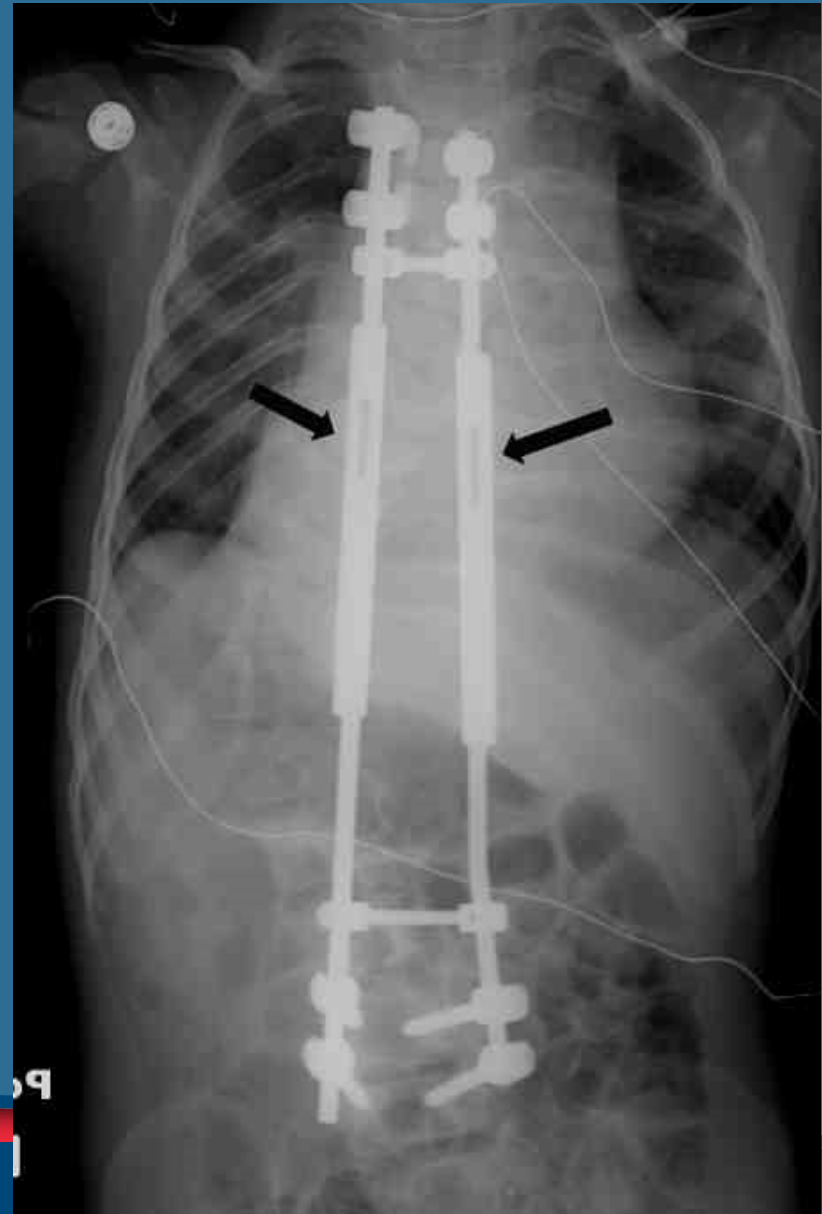
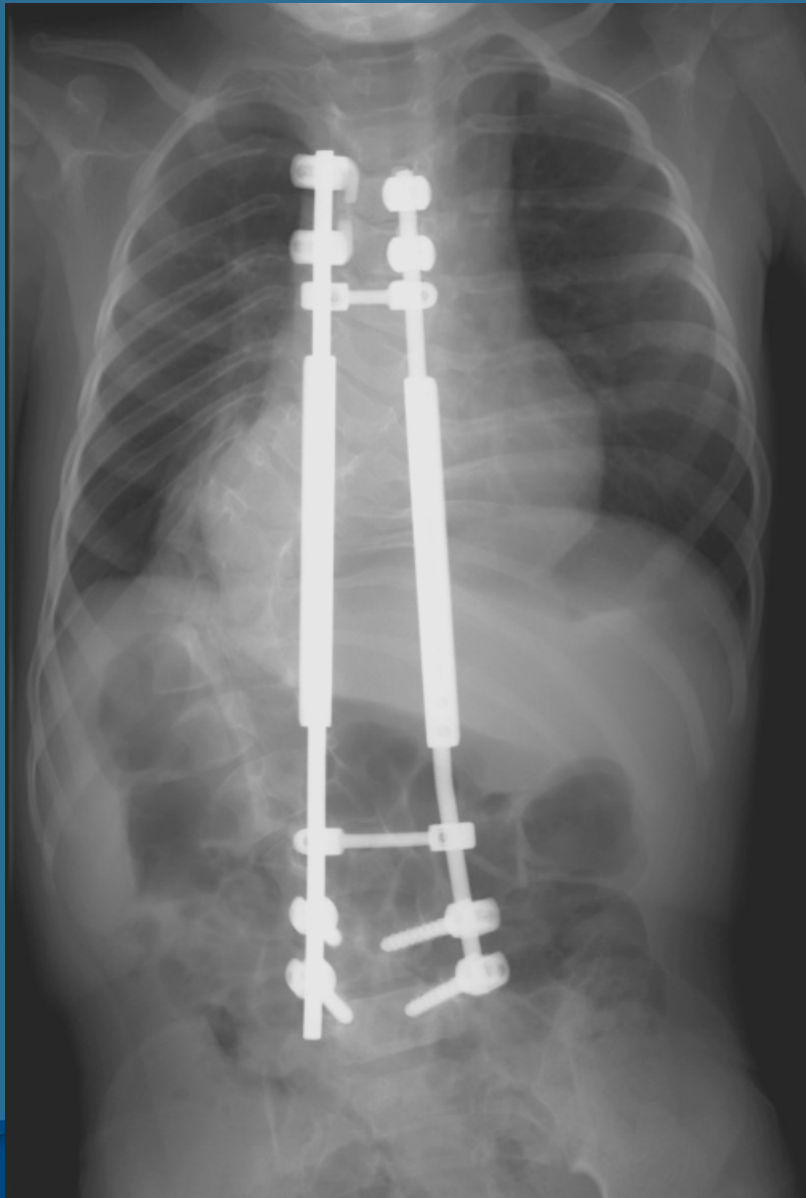
Kyphosis not an issue



Primary  
implant



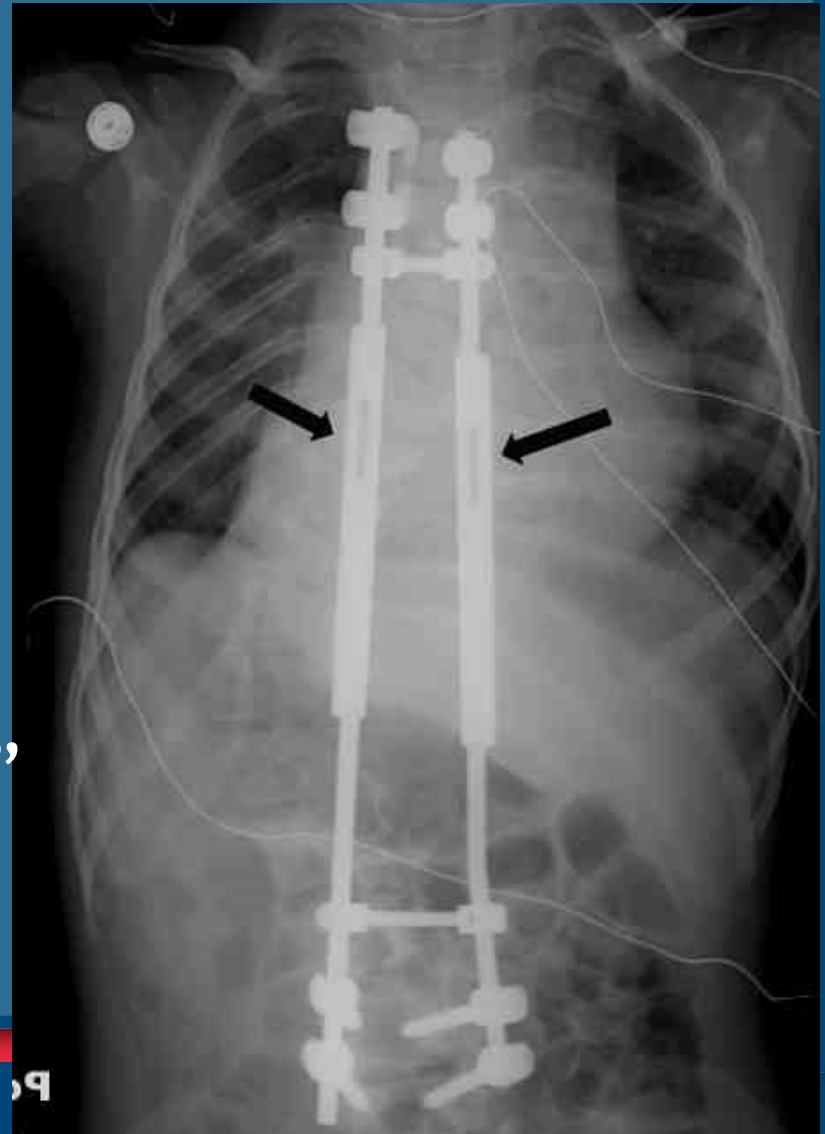
# 6 months later, Lengthening - 19mm



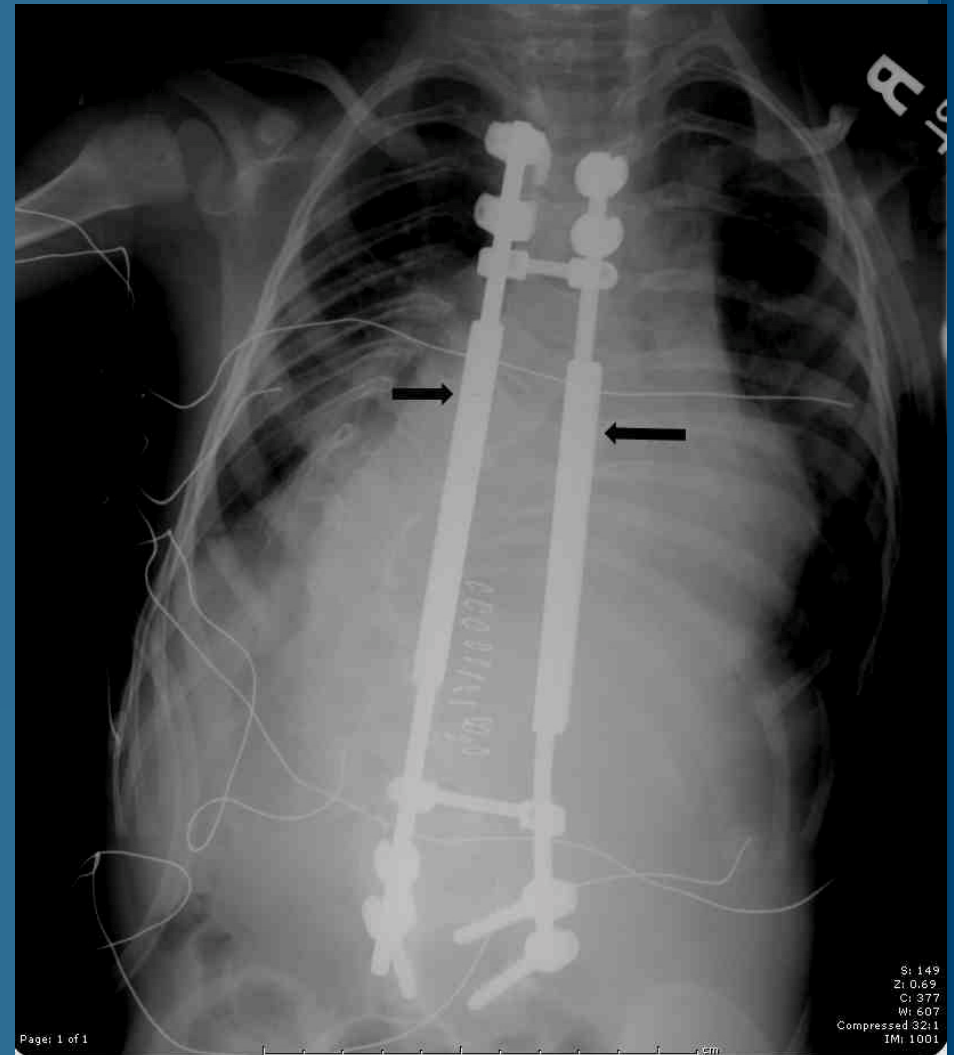
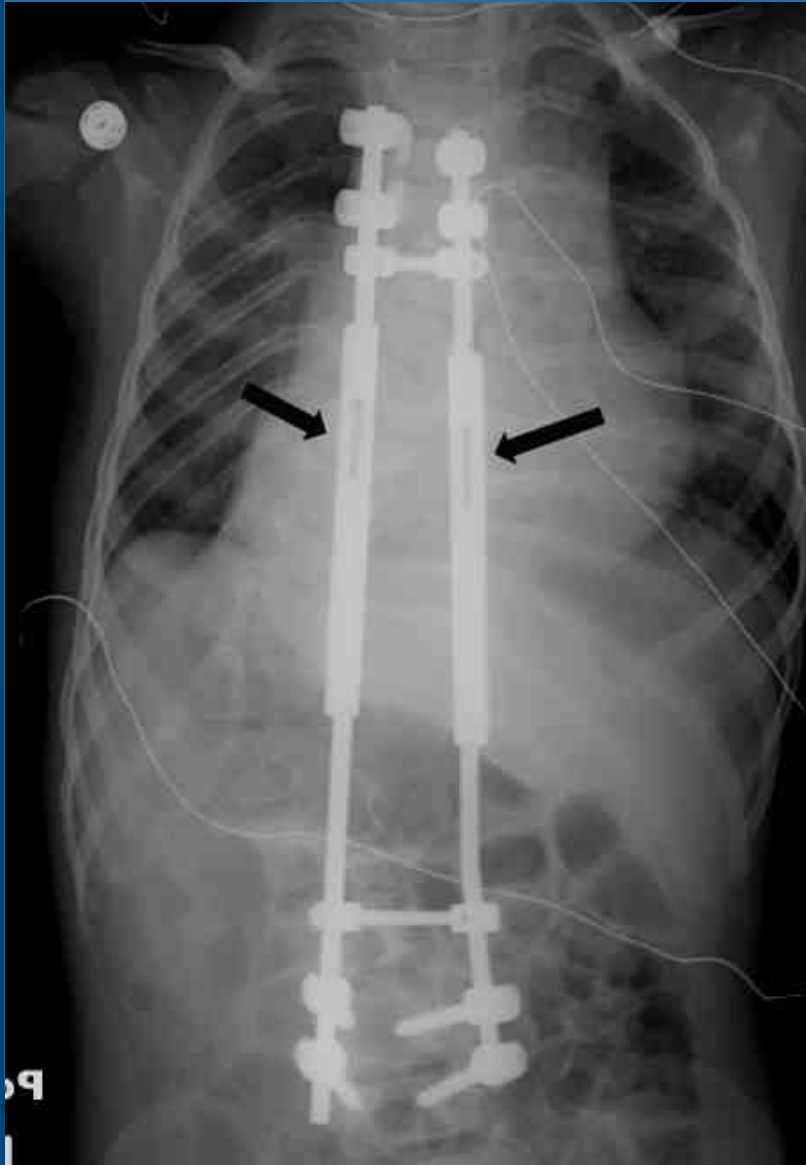
# Cardiac Failure

2AM, 18 hours after lengthening

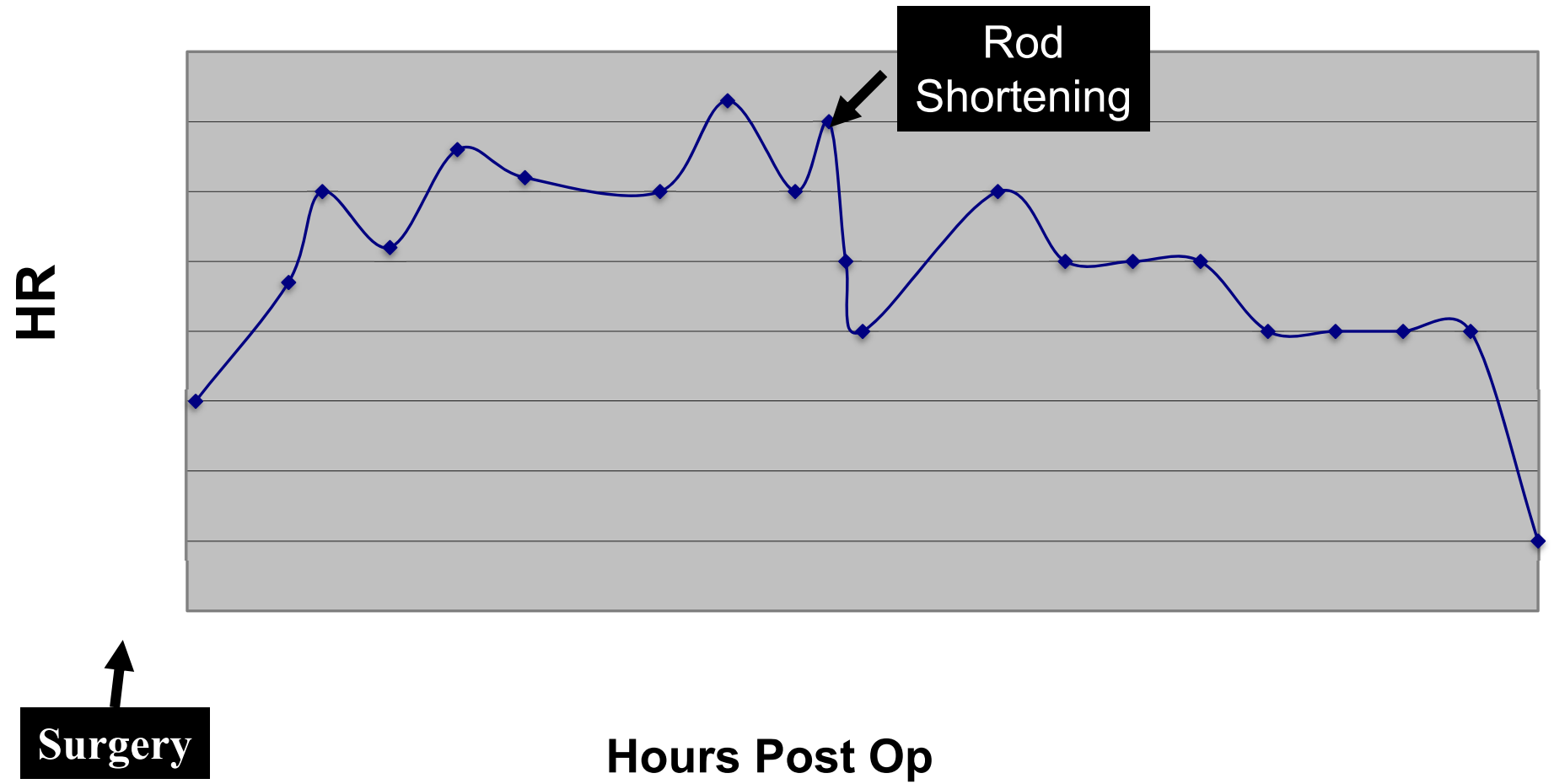
- ↑ heart rate (170)
- ↑ CPK-MB (21)
- ↑ Troponin (1.63)
- ↓ Shortening fraction (8% Vs. 28% pre-op)
- Steadily Worsening Clinically
- Death predicted in hours
- Consensus  
“too sick for anesthesia”



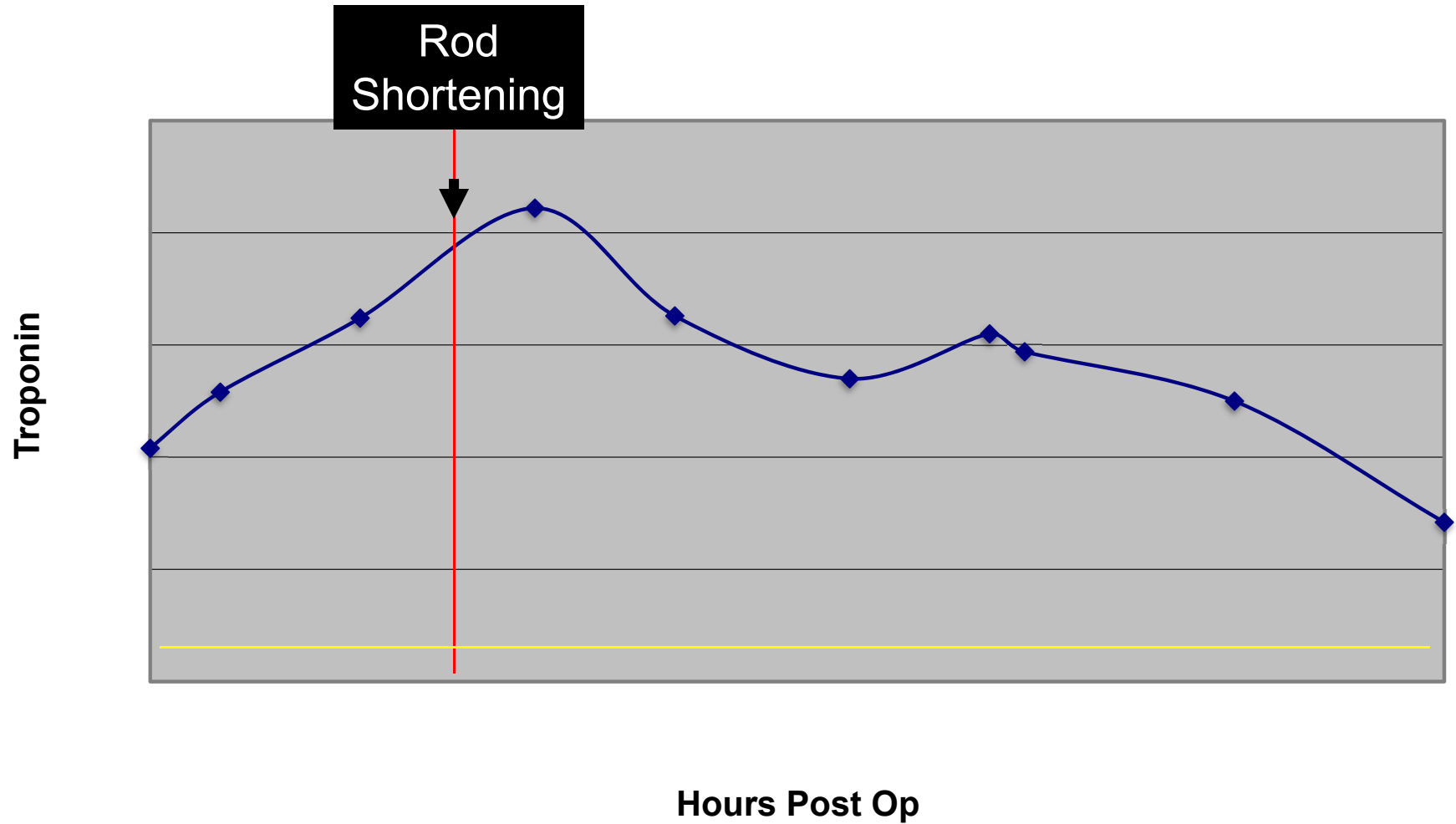
# Shortened Rods in ICU Emergently



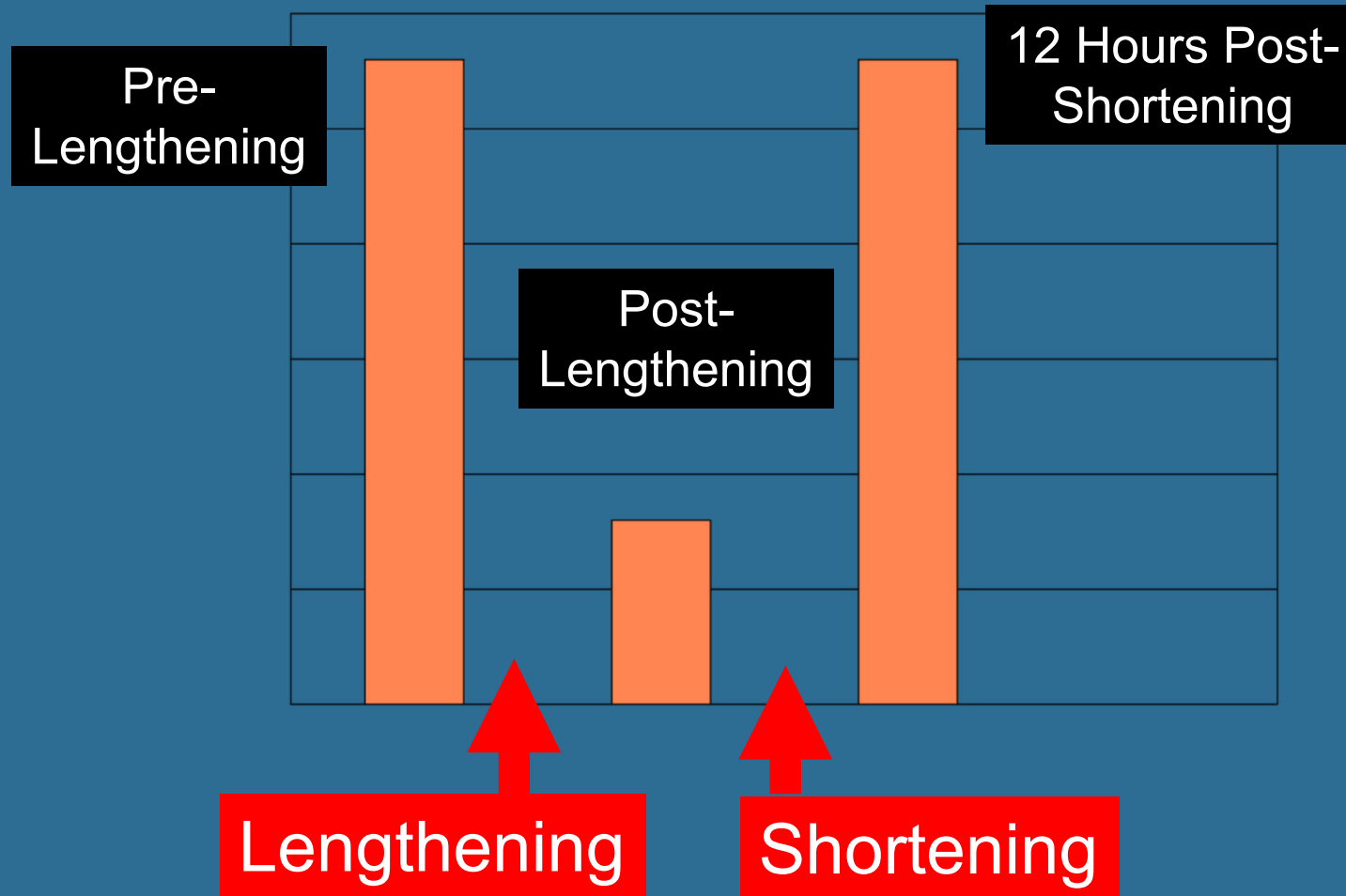
# Heart Rate



# Troponin

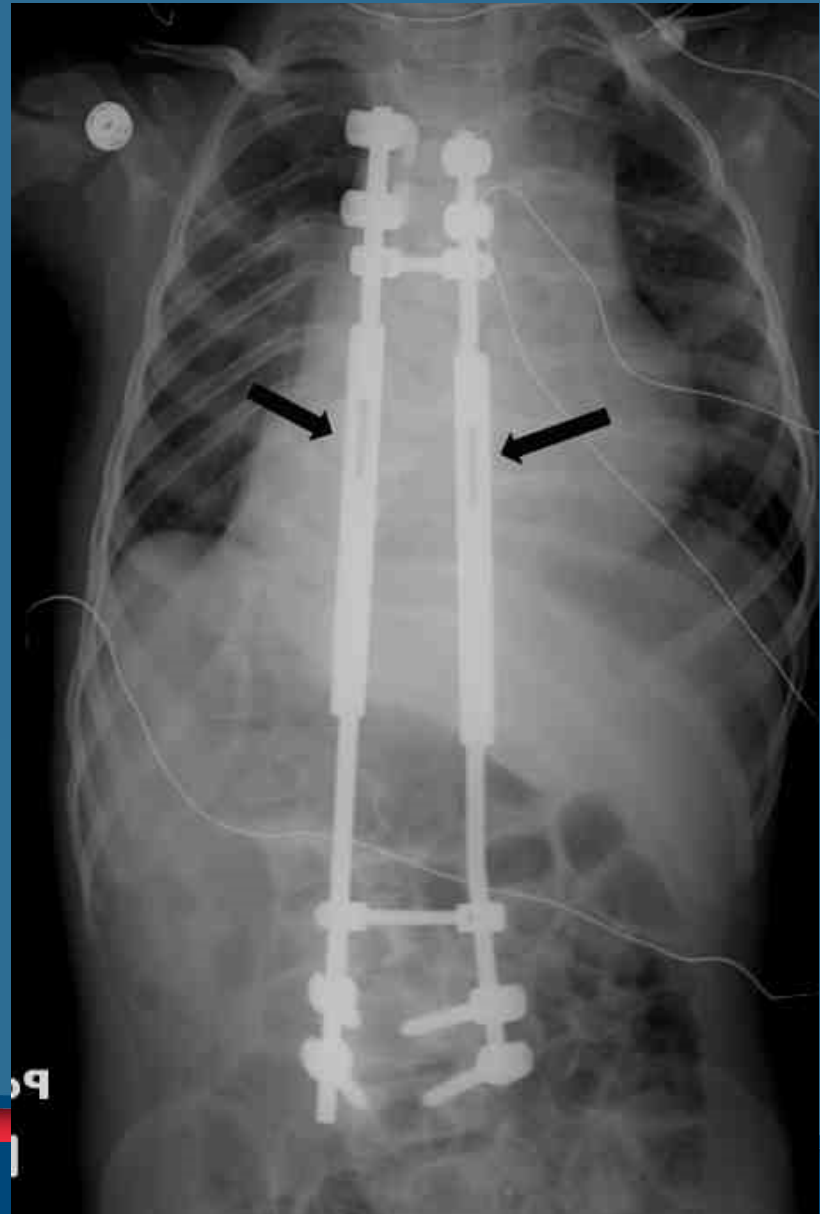
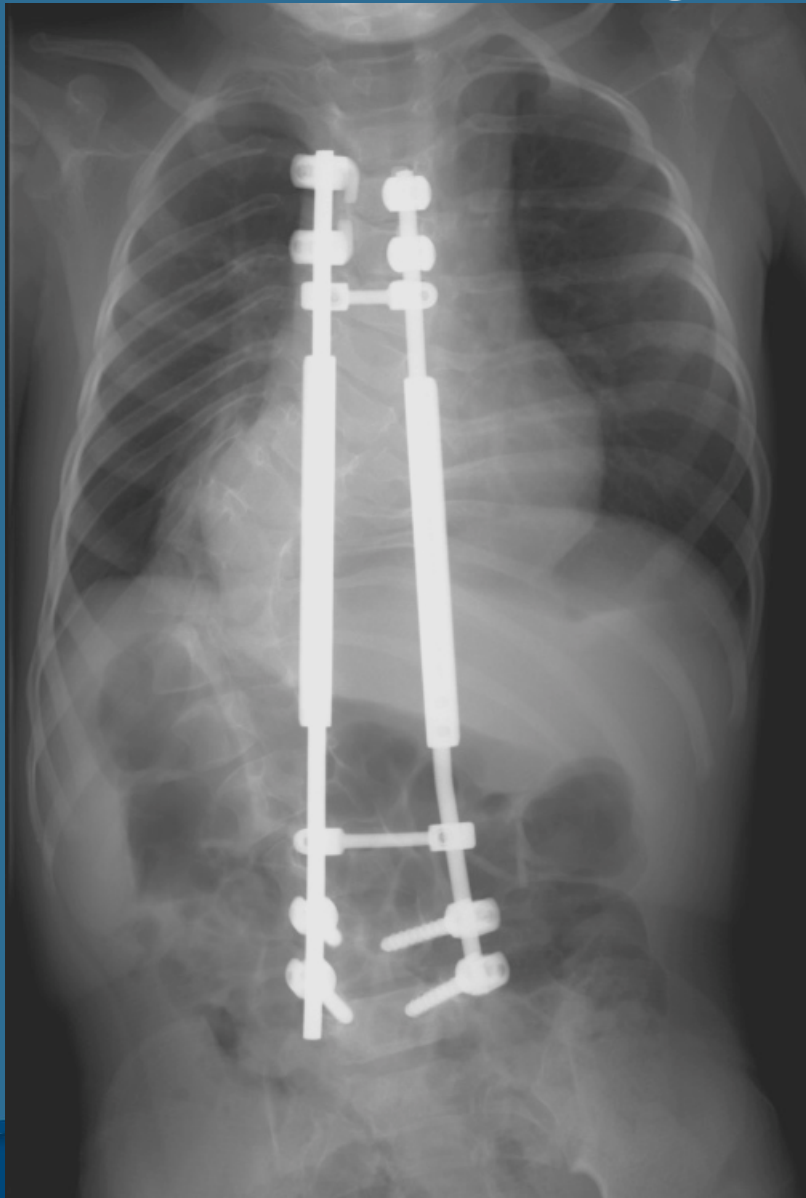


# Ejection Fraction



# Change in Practice

## Don't Lengthen >1cm at once



# Lessons

If our changing the shape of a child causes harm,  
consider reversing mechanical change.

Instead of “too sick to operate”,  
“too sick not to operate”

# Thank You



ORTHOPAEDIC CENTER

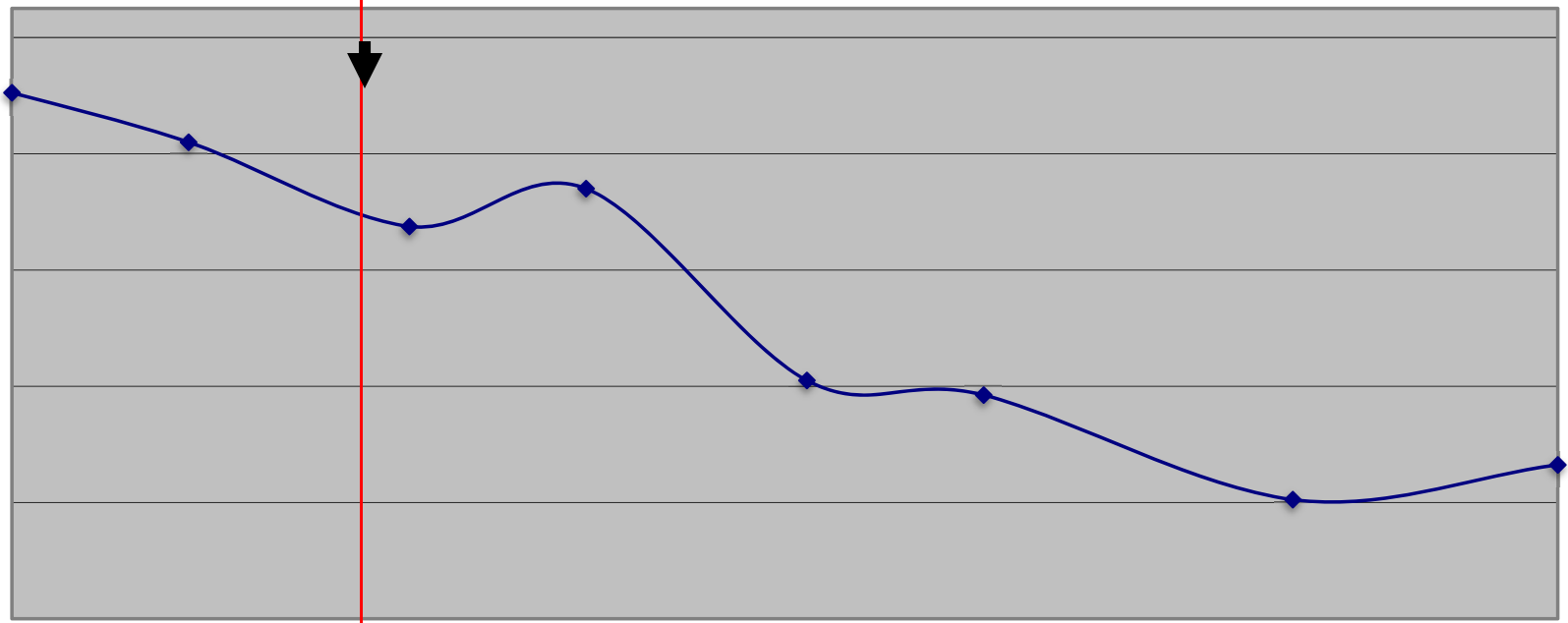
# Thank You



CKMB

Rod  
Shortening

CKMB



Hrs. Post Op

# Congenital Scoliosis with Right Side T2 Hemivertebrae

