

Lessons Learned: Something I wouldn't do again. Woos with Rib Bands

Richard M Schwend MD
Children's Mercy Hospital
Kansas City, MO

ICEOS 2015

9th International Congress
on Early Onset Scoliosis (ICEOS)

November 19 & 20, 2015

Seaport Hotel • Boston, MA, USA



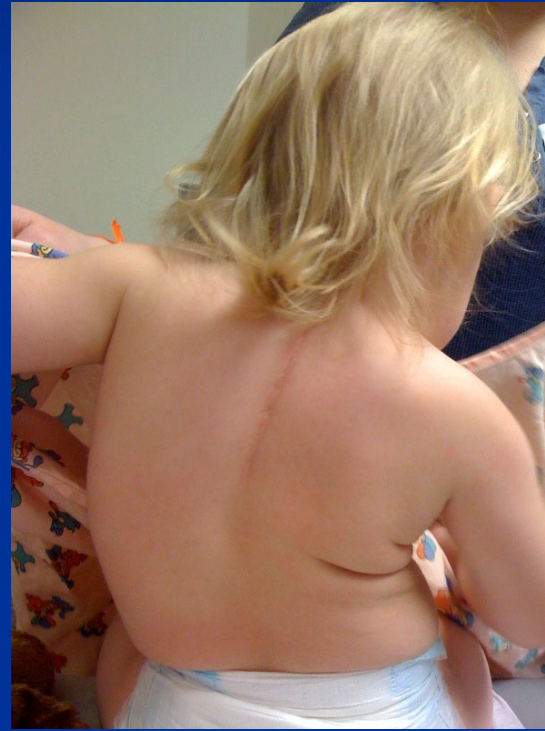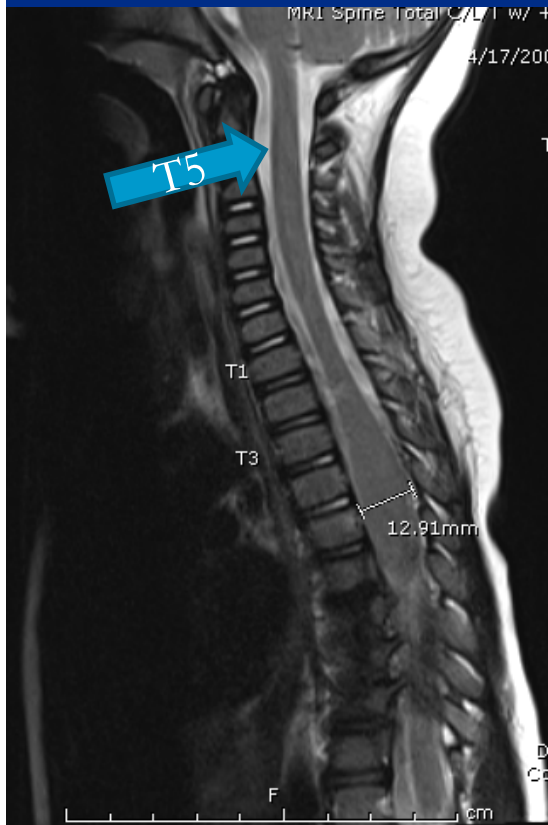Disclosure

Nothing to disclose

Disclosure

Other than Kansas City won the 2015 World Series



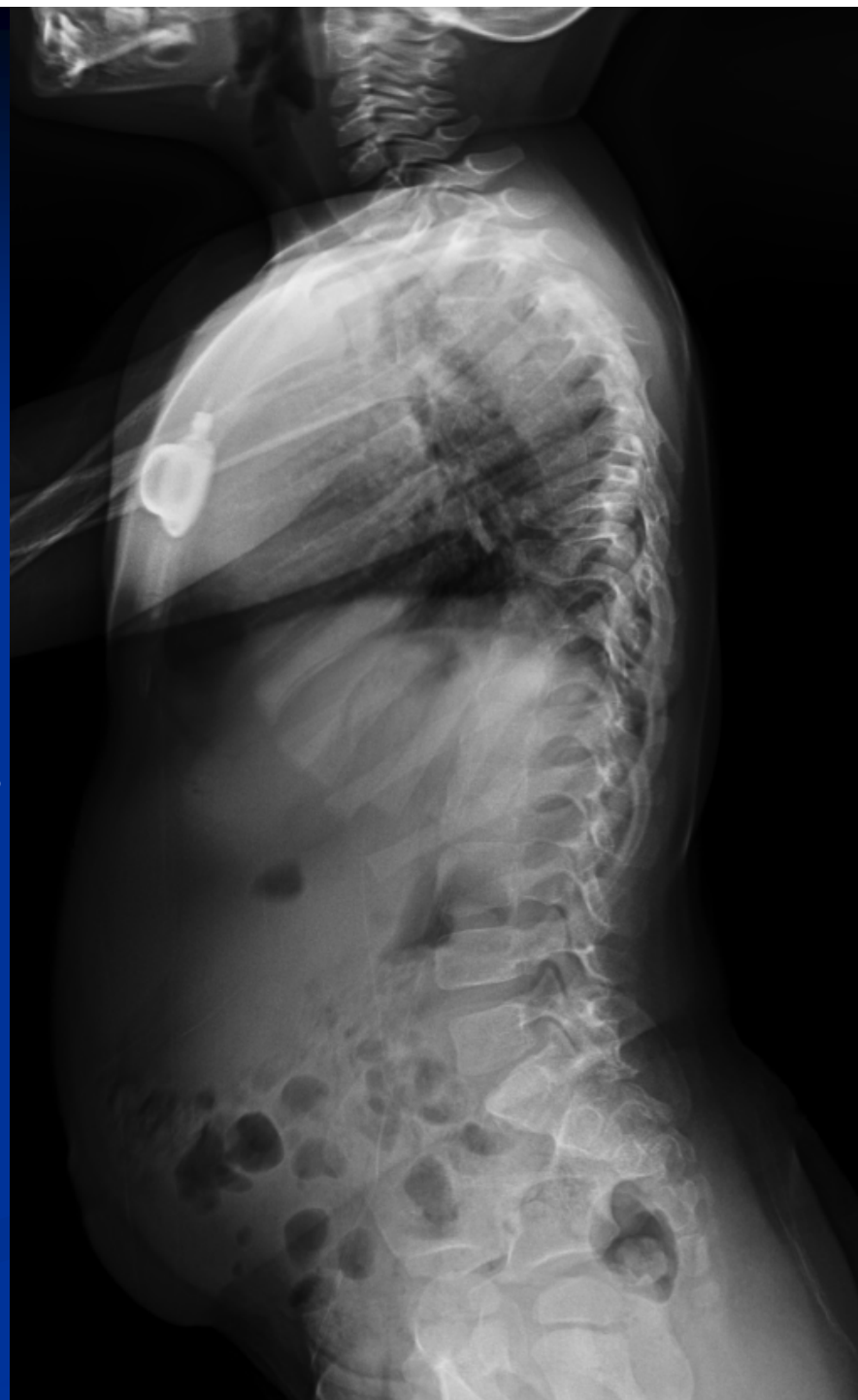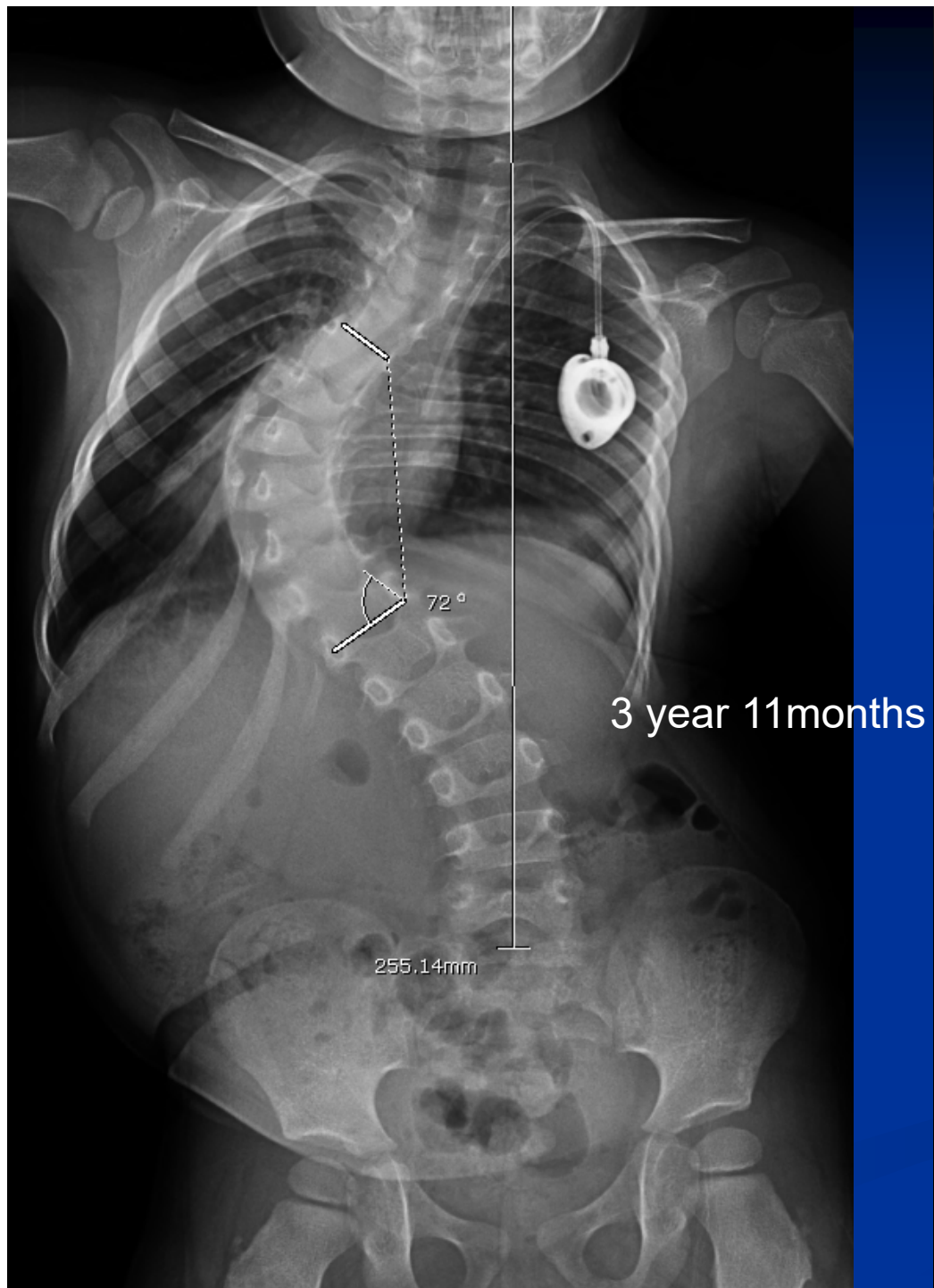


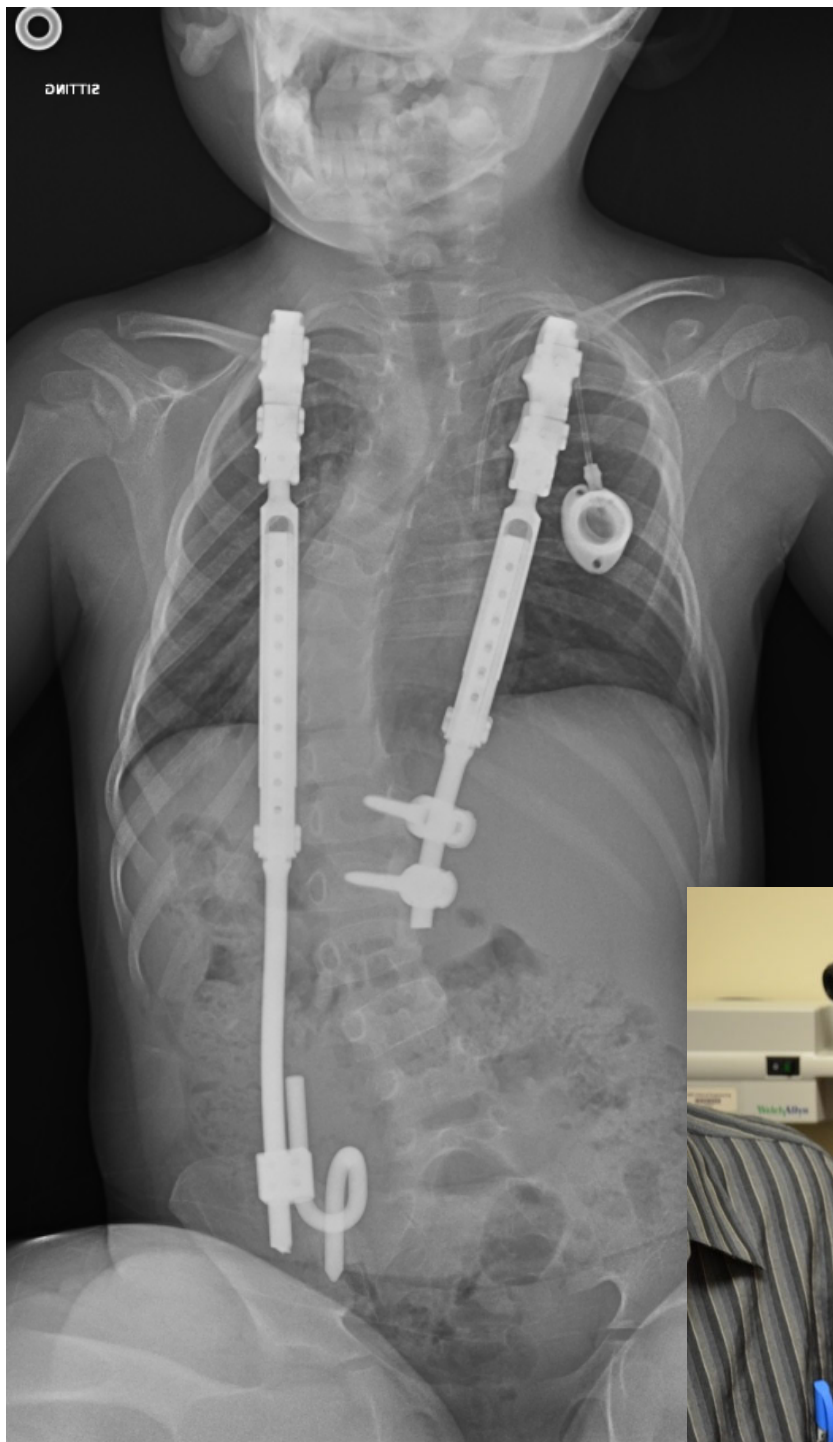
Low grade spinal cord tumor diagnosed at 17 months of age.

3 posterior biopsies were non diagnostic

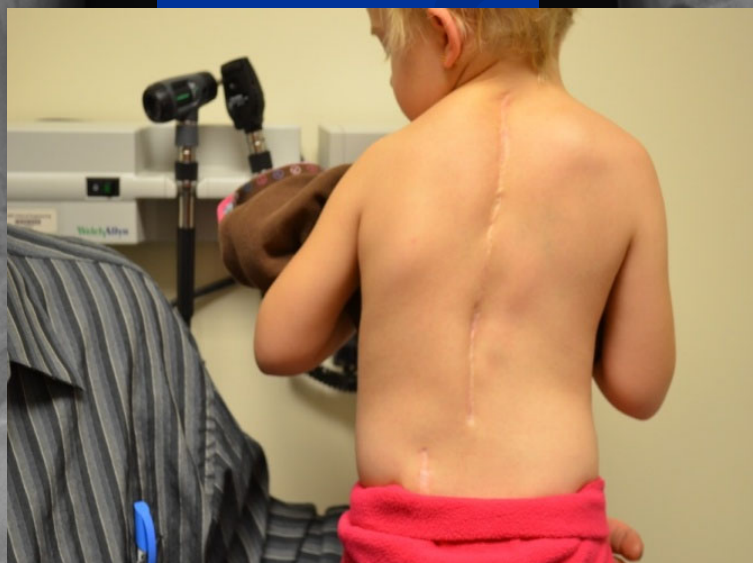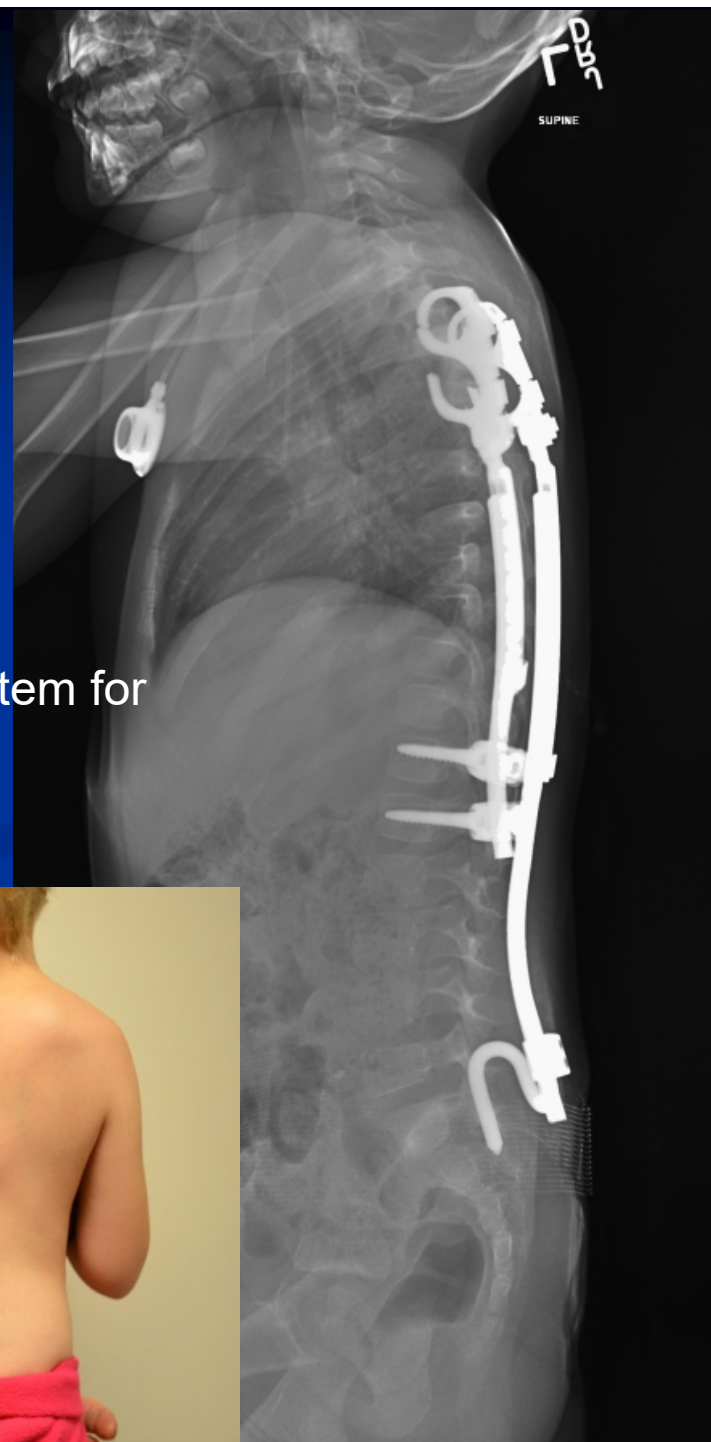
Treated with chemotherapy, casting and bracing for 2 years, attempting to keep implants away from spinal cord.

Previous animal study had shown needed VEPTR ≥ 3 cm away from spinal canal to have adequate MR images.

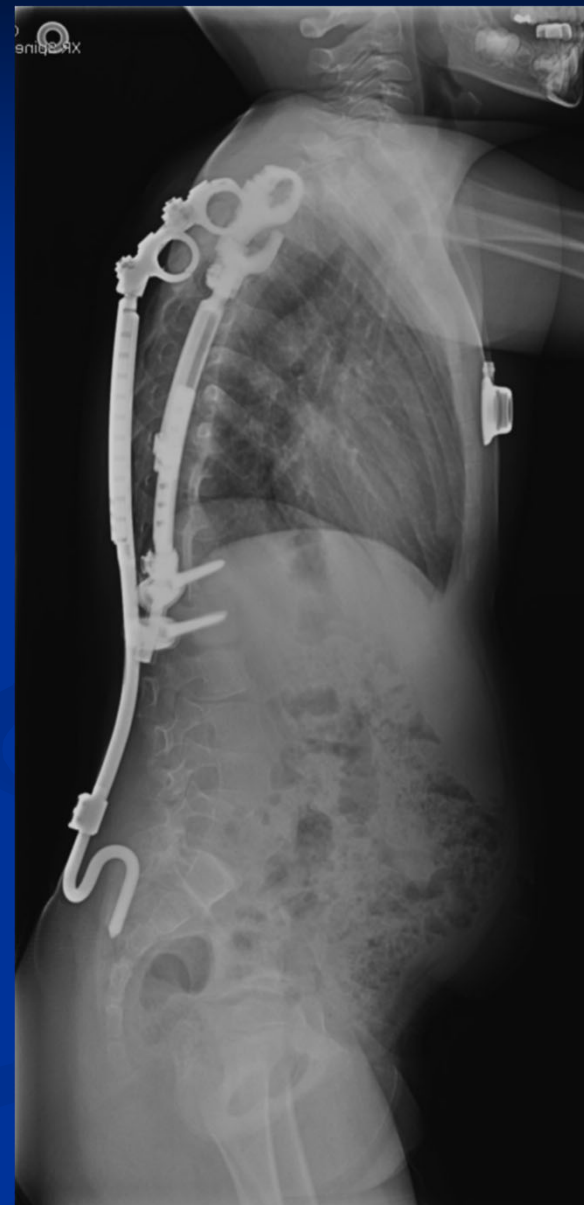
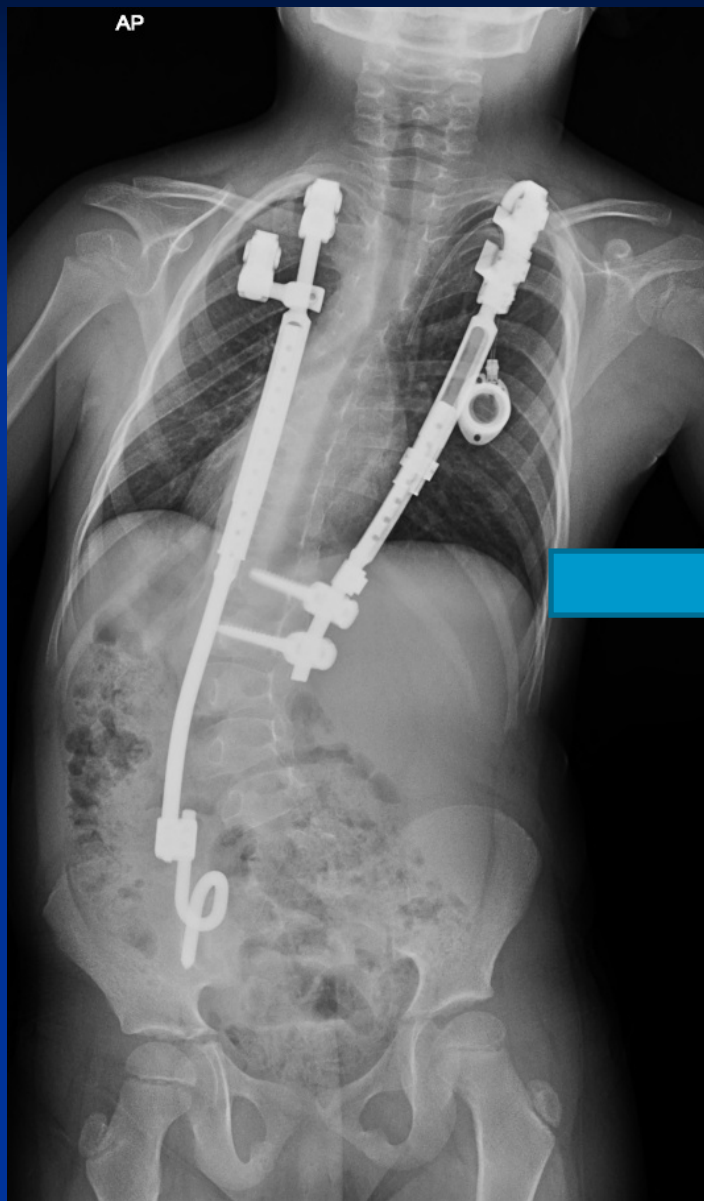





4 years
Rib based system for
MR imaging



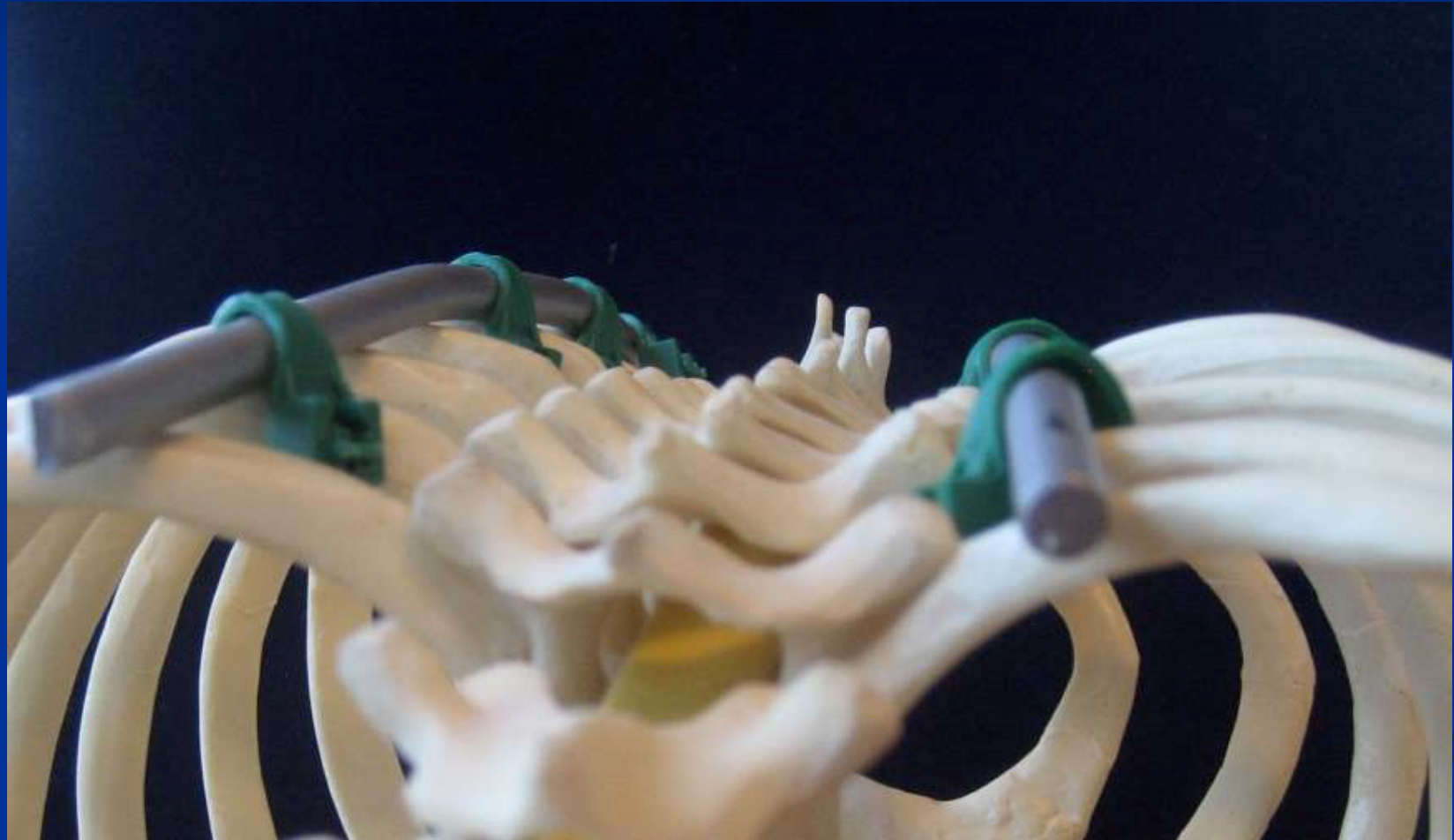
5 years 1 month

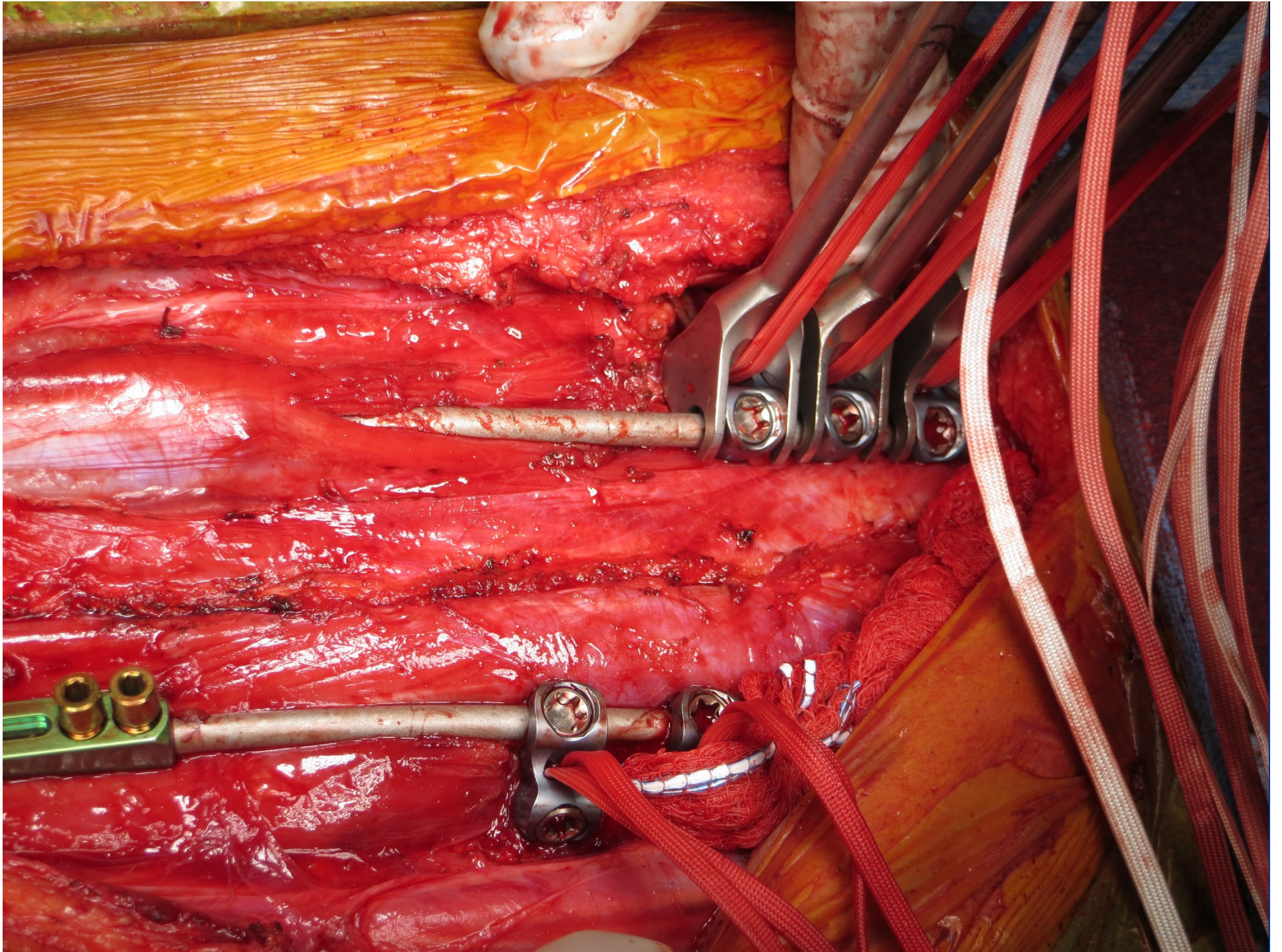




Rib Bands

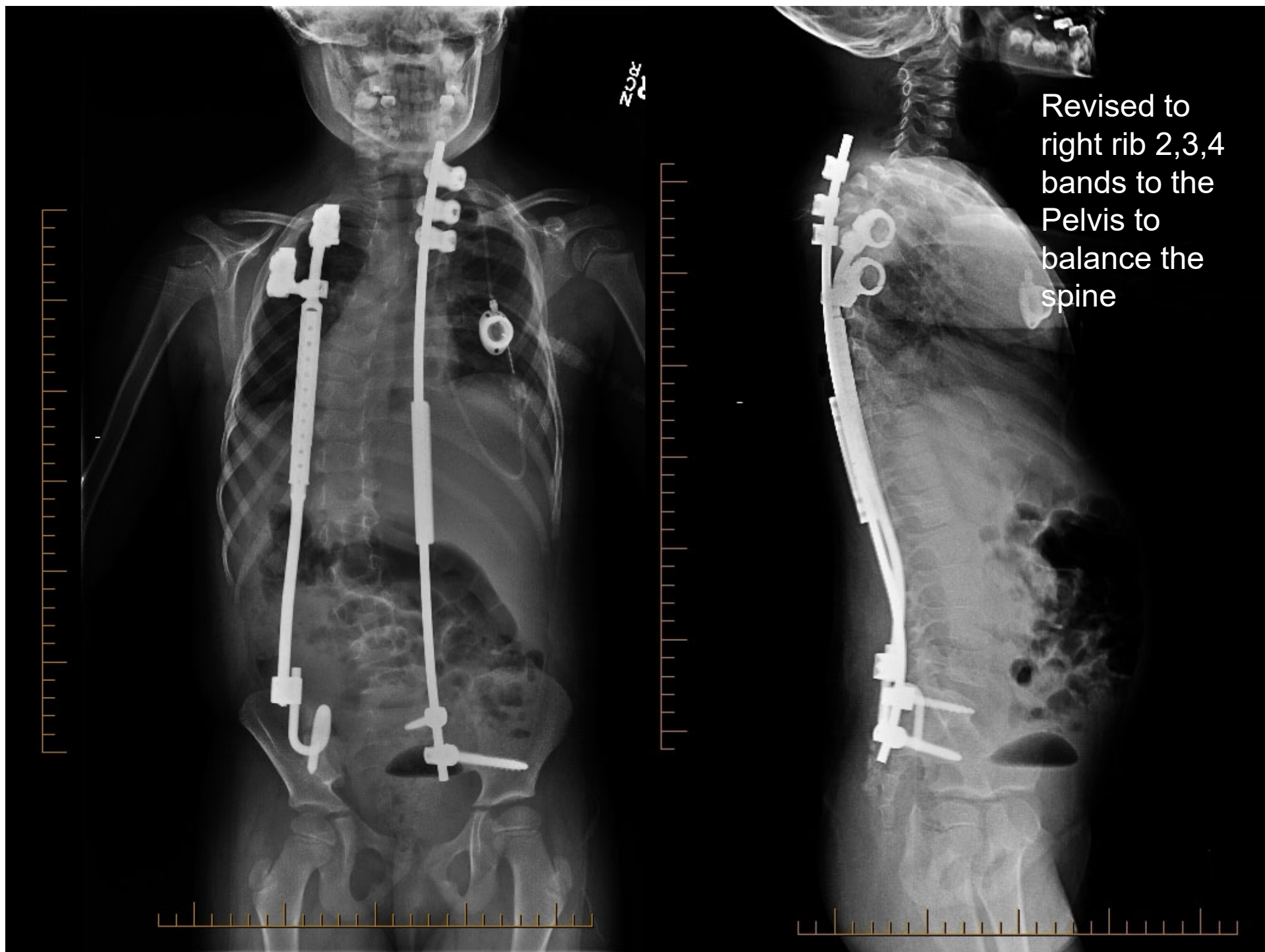
Axial view from inferior. Low profile



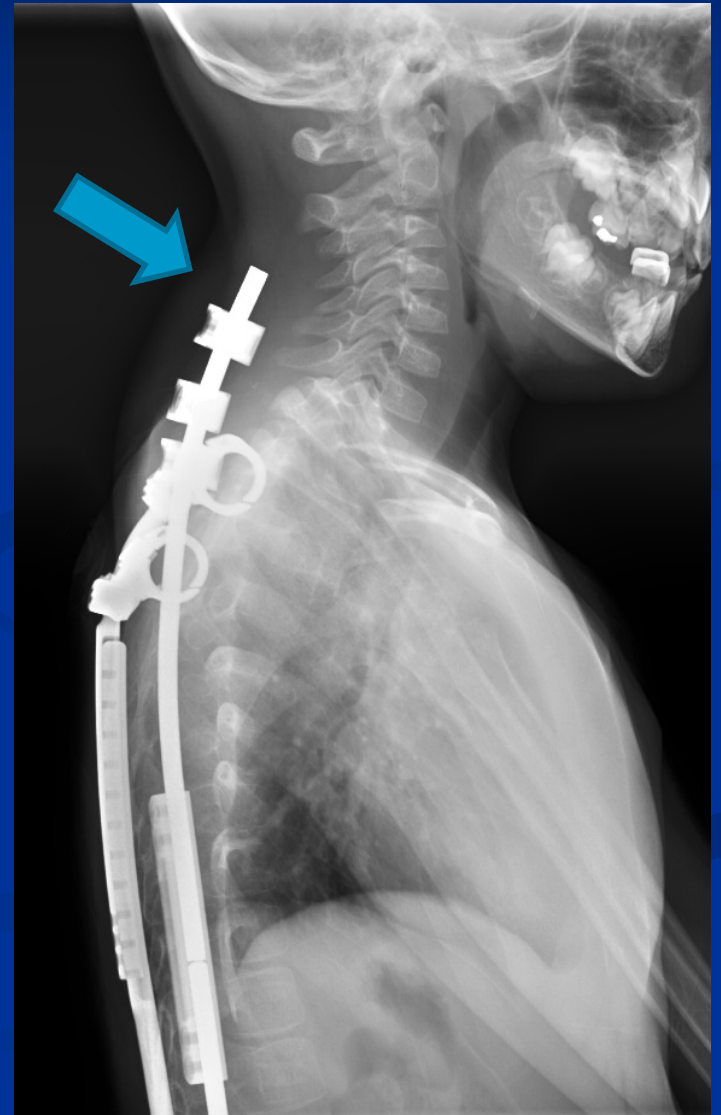
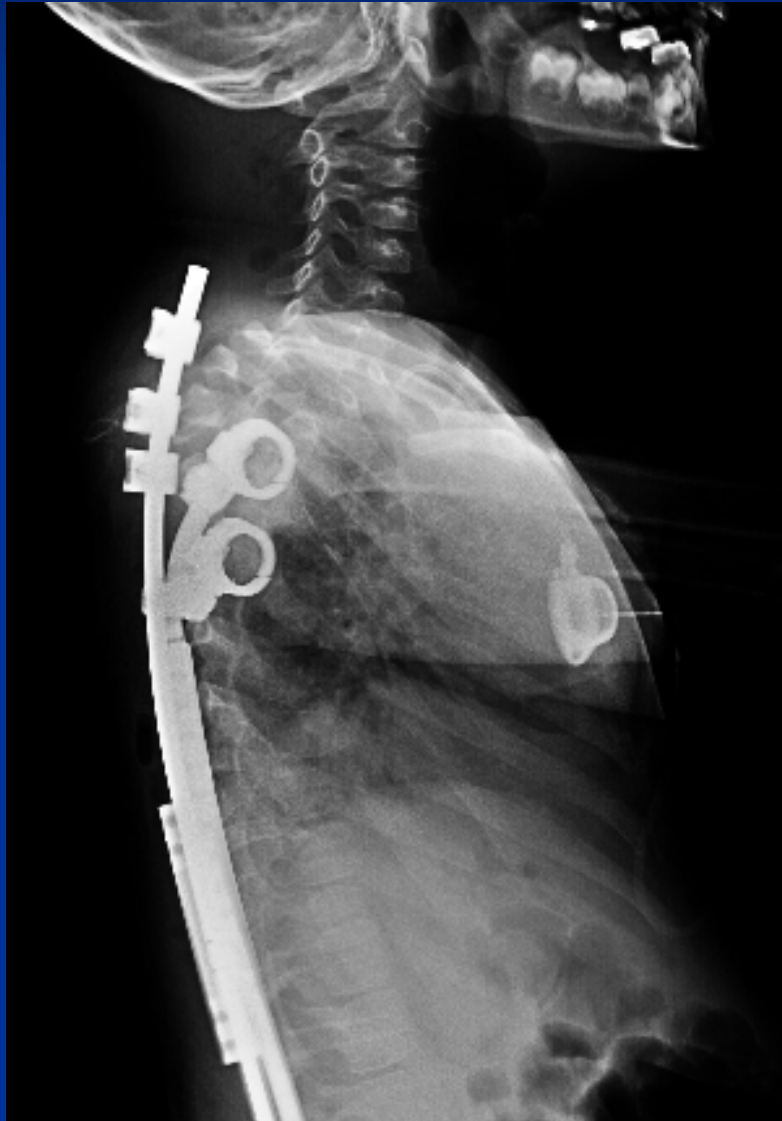


AP

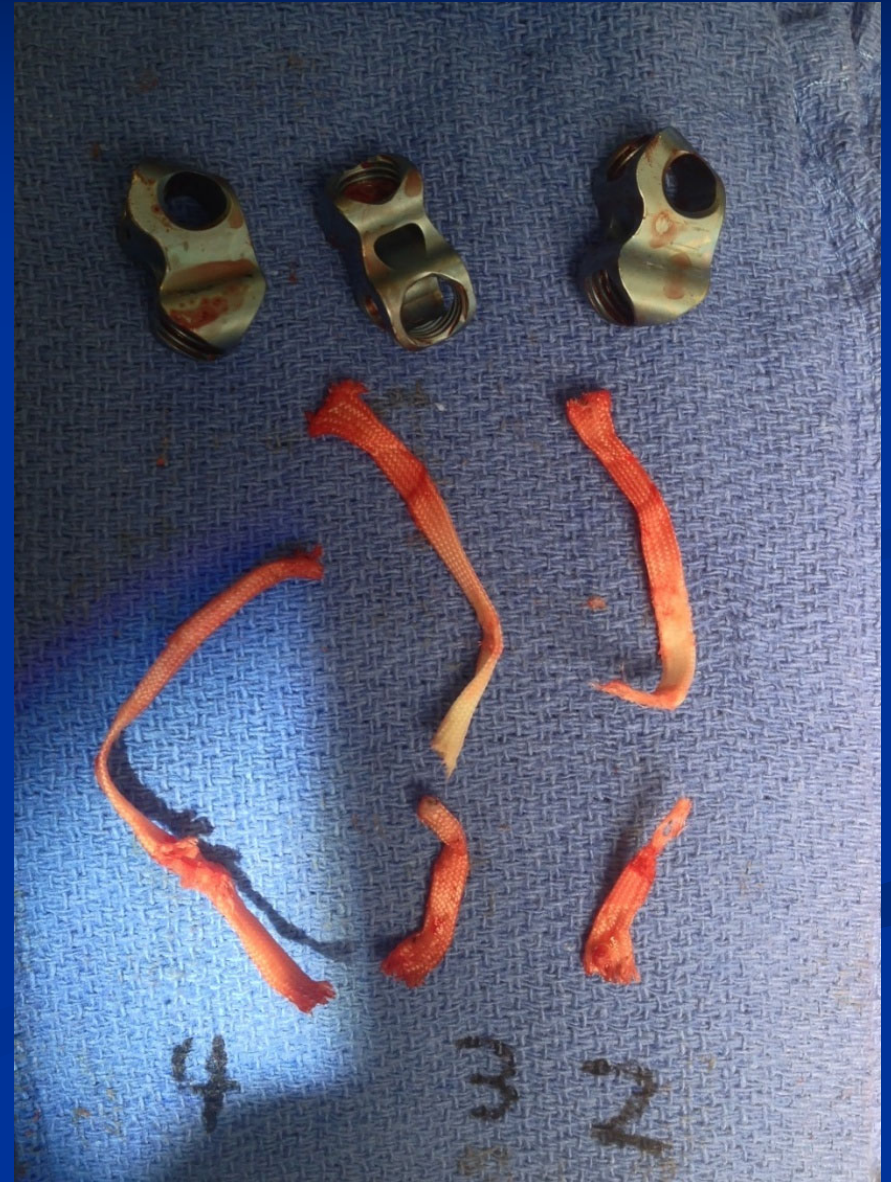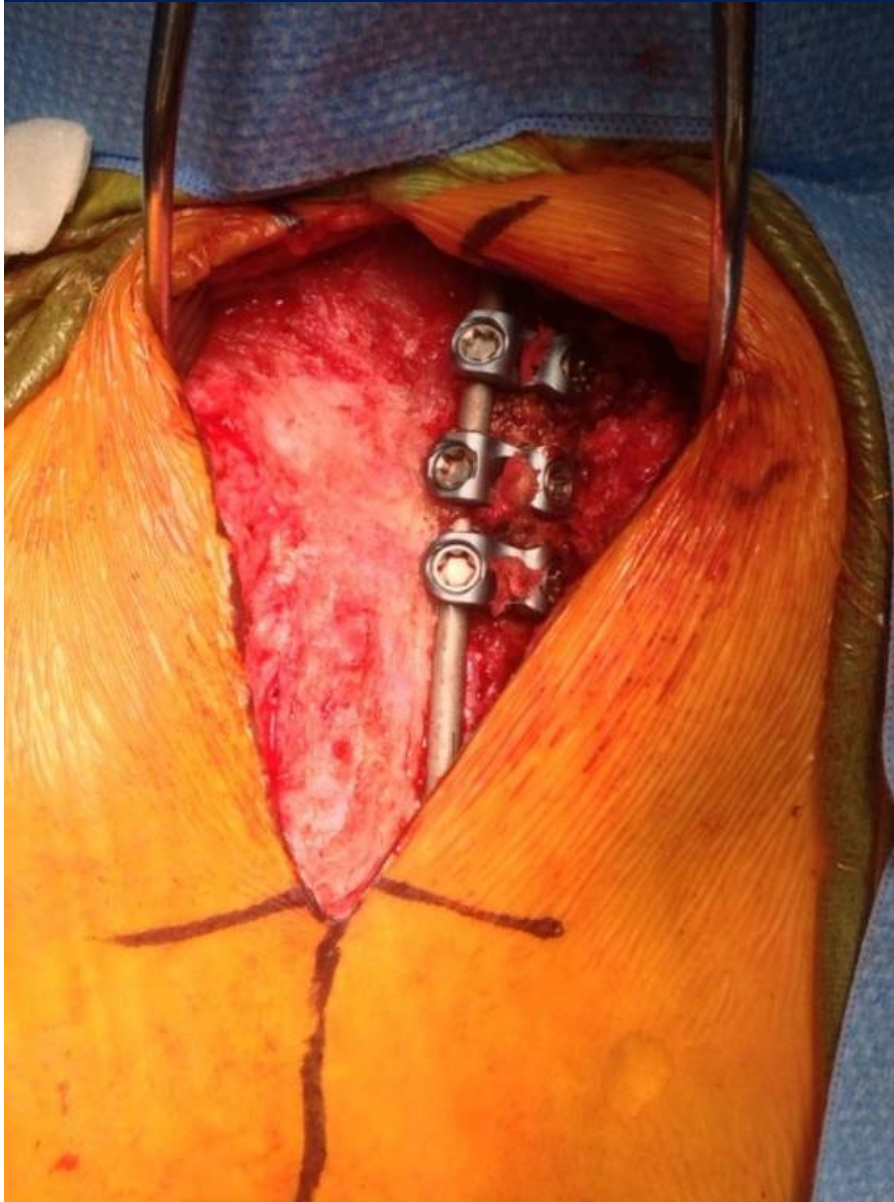
Revised to
right rib 2,3,4
bands to the
Pelvis to
balance the
spine



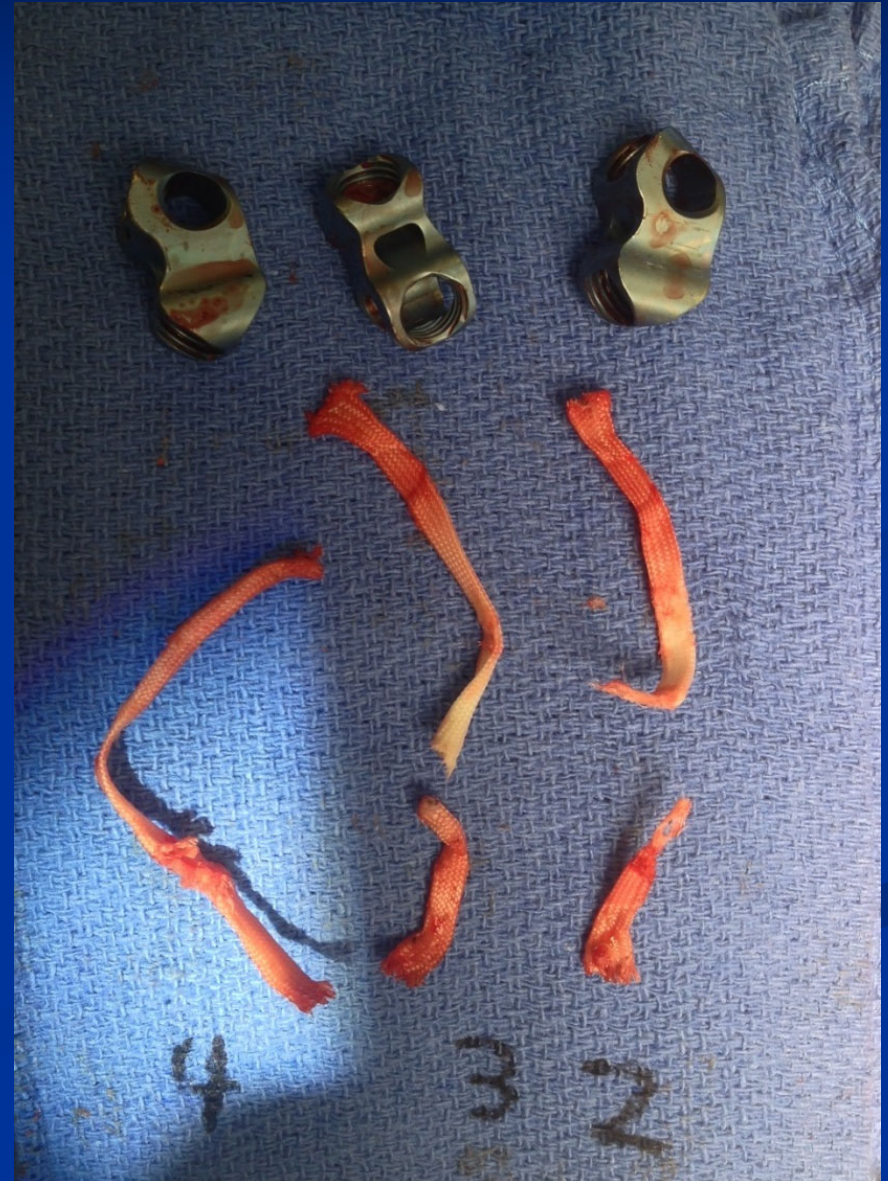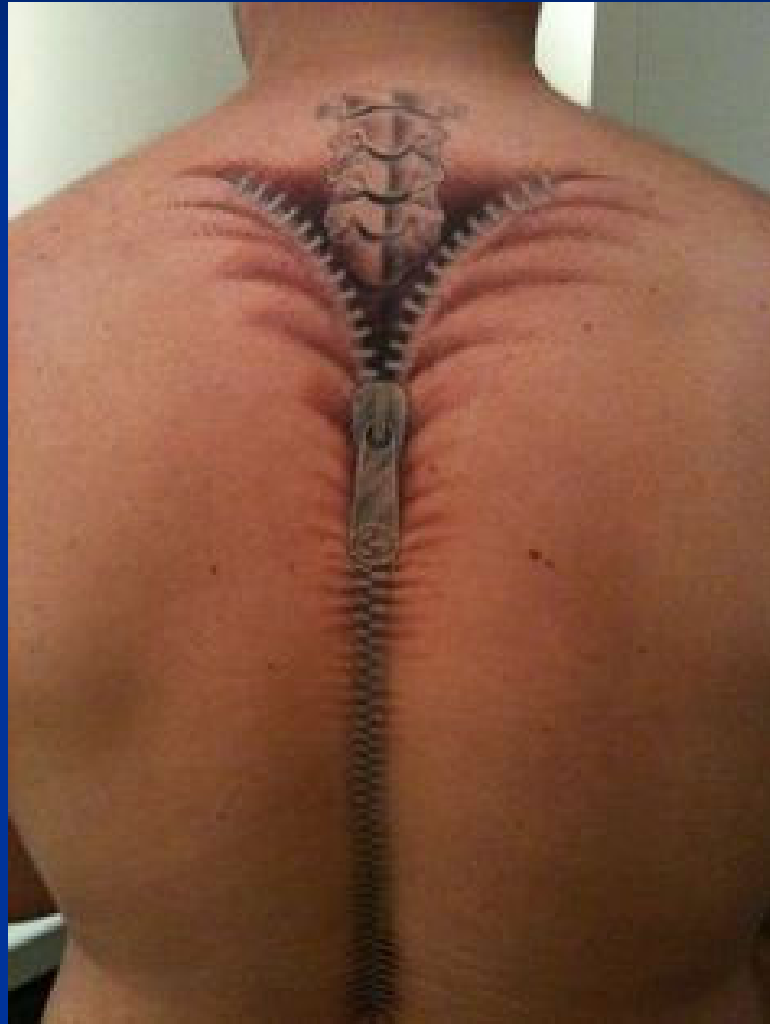3 months later-pain and lump

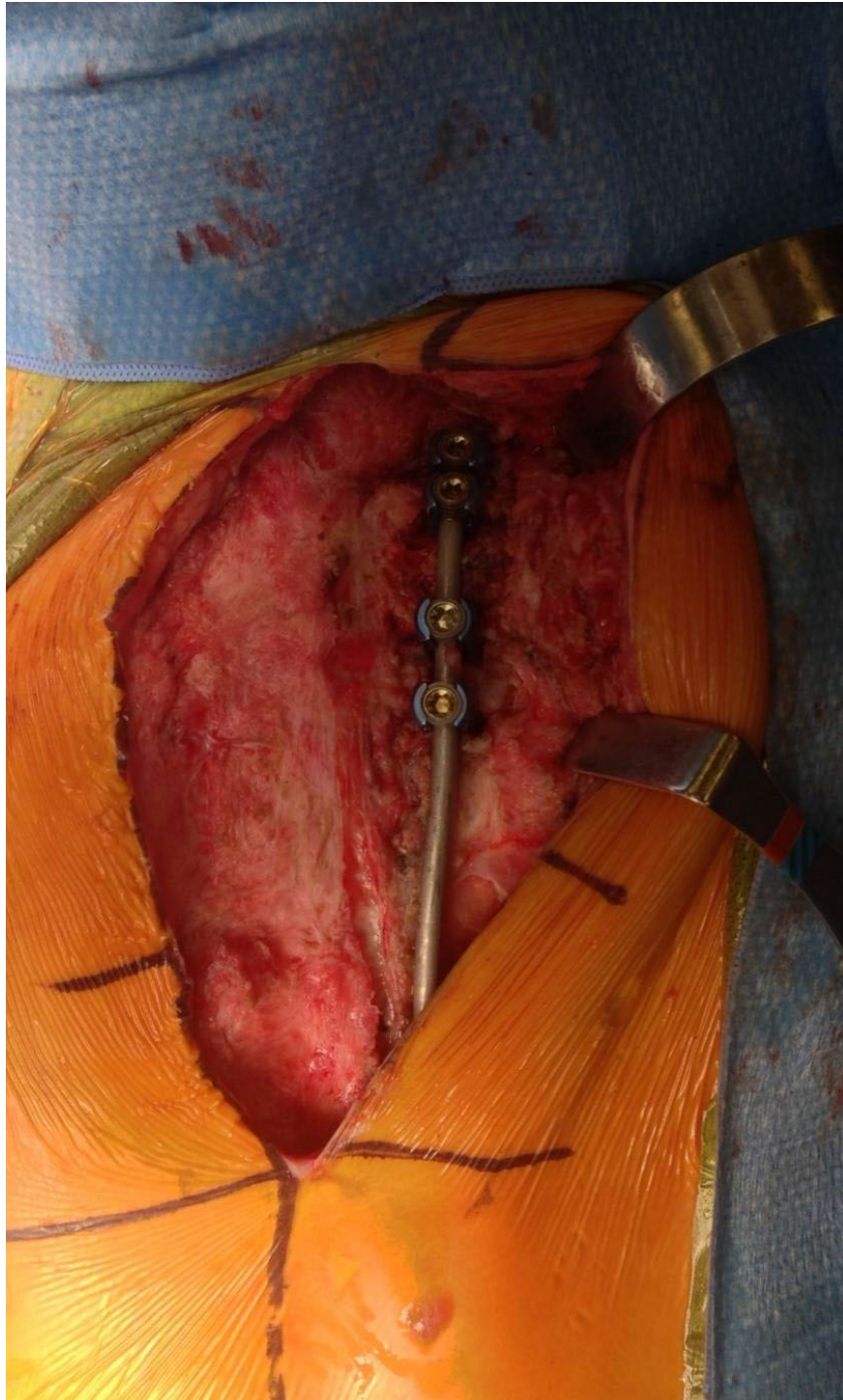


Bands broke top to bottom



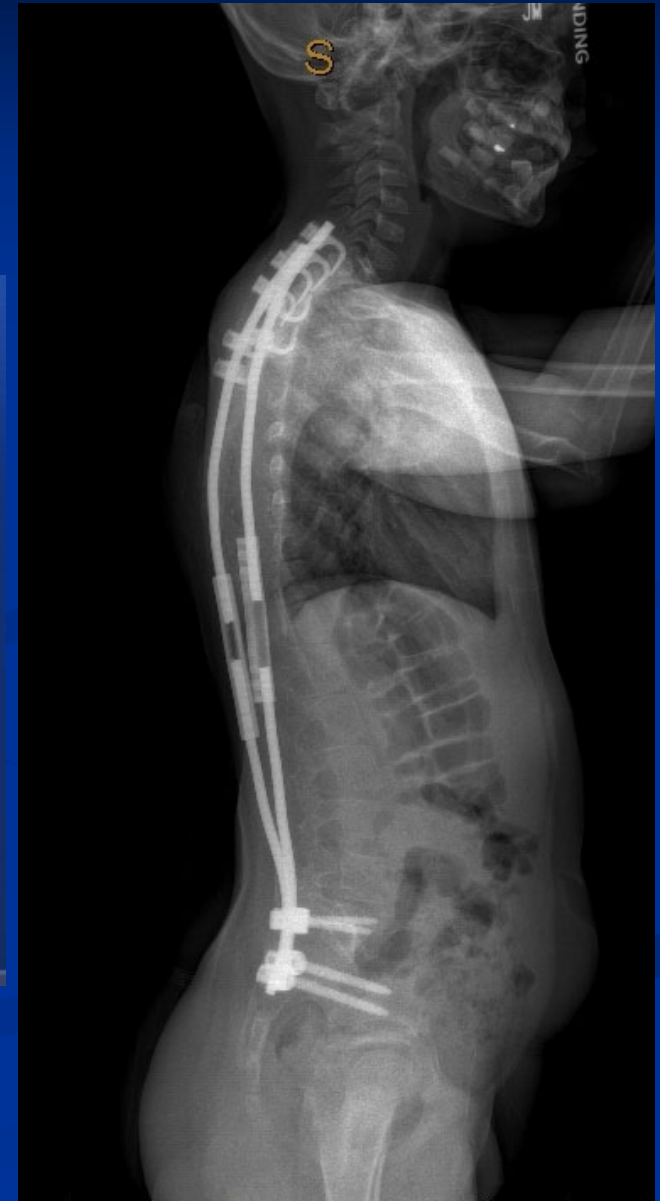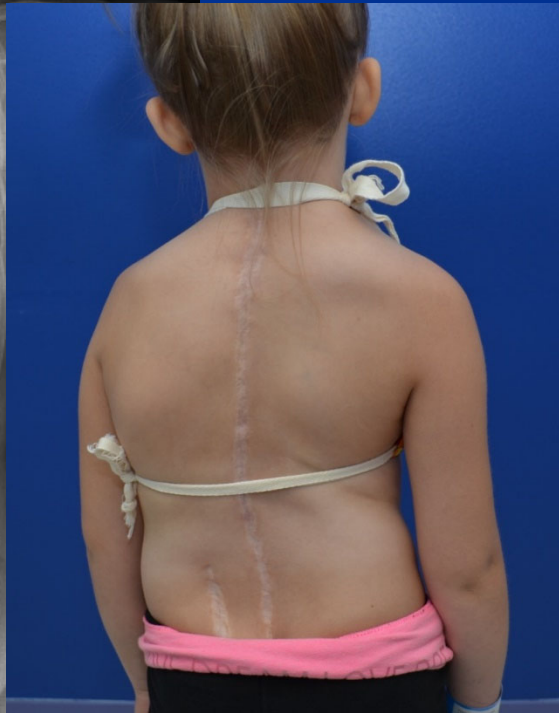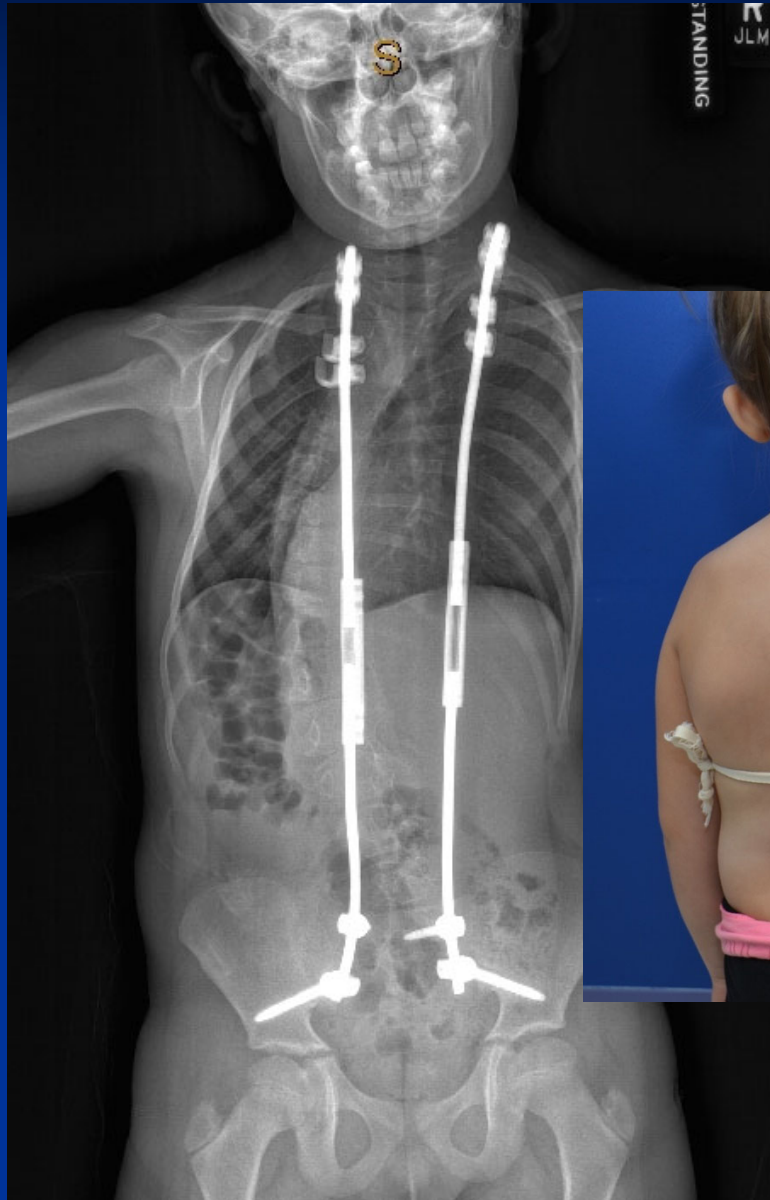
...like a zipper





Replaced with 4
rib constructs

7 year 6 months
Normal neural function and exam



NF1

