

# How Should We Finish?

## Strategies for Ending Growing Rod

---

Muharrem YAZICI, MD  
Hacettepe University, Ankara, TR

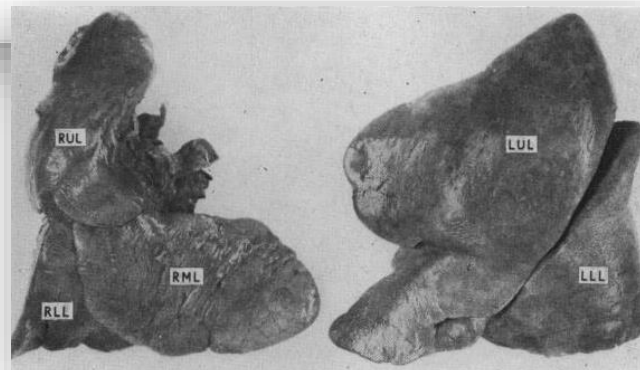
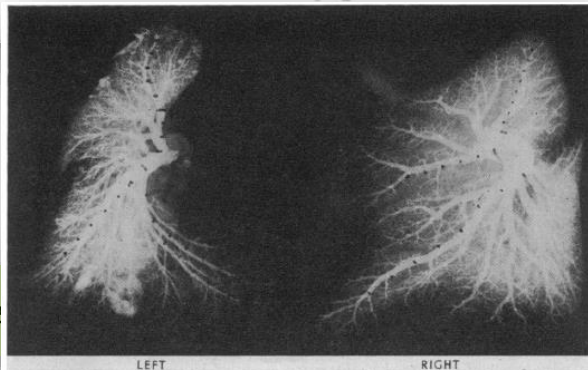
# Untertated EOS?

## Effect of Scoliosis on Growth of Alveoli and Pulmonary Arteries and on Right Ventricle

G. DAVIES\* and LYNNE REID

*From the Department of Experimental Pathology, Institute of Diseases of the Chest, Brompton Hospital, London*

**Davies, G., and Reid, L. (1971).** *Archives of Disease in Childhood*, 46, 623. **Effect of scoliosis on growth of alveoli and pulmonary arteries and on right ventricle.** During childhood the lung not only grows in size but alveoli and arteries multiply and the pattern of muscularity of the arteries changes. A quantitative study is here reported on 4 cases of scoliosis. The limitation and distortion of space available affect lung growth. In scoliosis, alveoli are too few in number, often emphysematous, and may even atrophy, the changes being irregularly distributed throughout a lobe or lung. Generally, the size of the large pulmonary arteries is appropriate to the lobar volume and hence small for the age of the child: arterial muscle hypertrophy and abnormal extension to the periphery were seen only in 2 of the 4 cases in which there was right ventricular hypertrophy. In these, hypoxaemia had been present for some time before death and this, not hypoplasia, seemed responsible for the muscle hypertrophy. In 2 cases where scoliosis was associated with a mesodermal dysplasia, there was an excessive number of intra-acinar arteries.



# Untreated EOS?

## CARDIORESPIRATORY CONSEQUENCES OF UNFUSED IDIOPATHIC SCOLIOSIS

M. A. BRANTHWAITE

*Brompton Hospital, Fulham Road, London SW3 6HP*

### *Summary*

A retrospective survey was carried out on approximately 800 scoliotic subjects attending a chest clinic over 25 years. One hundred thirty-one patients with unfused idiopathic scoliosis were identified and further consideration was restricted to 54 who were assessed at 30 years of age or older. Sex, age of onset of curvature, severity at the time of presentation, degree of dyspnoea, presence of independent cardiac or pulmonary disease and smoking habit were recorded. Measurements of lung function were compared with predicted figures calculated according to span, age and sex.

Disabling dyspnoea or cardiorespiratory failure were associated with either scoliosis of early onset (curve first noticed before 5 years) or with independent cardiac or pulmonary disease. Only one of 28 patients with unfused idiopathic scoliosis of adolescent onset developed disabling dyspnoea in later life attributable solely to spinal deformity. A similar conclusion was drawn from a separate survey of mortality in 86 patients, 19 of whom suffered from idiopathic scoliosis. Cardiorespiratory failure attributable to the scoliosis was the cause of death of 11 patients, in 10 of whom the curve had first been noticed at less than 5 years of age whereas the onset was during early adolescence (11 years) in only one.

# Untreated EOS?

---

- Pehrsson et. al., Spine 1992
  - Increased mortality
    - High risk for infantile
      - 40% respiratory failure
      - 90% of patients with respiratory failure was diagnosed before the age of 9
  - 50% of surviving patients are receiving anti-hypertensive treatment

# Early fusion?

---

- Goldberg et. al., Spine 2003
  - 41% FVC at maturity, if spine is fused < 10 years-old
- Karol et. al, JBJS 2008
  - Age @ surgery 3.3 and FU 14.6 year
  - FVC 57.8 %
  - Length of fusion and low FVC
  - Extension of fusion thru T1-T2 and pulmonary problems
- Emans J, SRS 2004
  - Age @ surgery 2.6 and FU 11 yr
  - FVC 62 %
  - Early fusion and ↓FVC, number of fused vertebrae and ↓FVC

# Ideal solution?

---

- Growth preservation, as much as possible
  - Delaying tactics
    - Casting
    - Growth friendly techniques
- If it is not possible
  - Minimum motion/growing segment fusion





# Growth friendly instrumentation\*

---

- Compression based
  - Tethering
  - Stapling
- Distraction based
  - GR
  - VEPTR
- Guided growth
  - Luque-trolley
  - Shilla

\* Skaggs, JPO 2013

# What we aim?

---

- Normal/near normal
  - Trunk height
  - Body appearance
  - Pulmonary capacity
  - ADL



# What we find?

---

- Day of graduation
  - Radiological
  - Functional
  - Life quality
  - Side effects



# Radiology +

---

- GR
  - Klemme et.al., JPO 1997
    - 76 pt, 45 grad.
    - 4.9 lengthenings before grad.
    - Pre-index 67°, pre-definitive 47°
    - 16 pt >10° rotation
    - 3 cm height gain in 3 years
      - 0.08 cm/segment/year



# Radiology +

---

- GR
  - Akbarnia et.al., Spine 2008
    - 13 graduates
    - T1-S1
      - 1.84 cm/year vs. 1.02 cm/year
    - Correction
      - @ index surgery 56%
      - @ definitive surgery 24%
    - 13 complications in 6 patients



# Radiology -

- GR
  - Acaroglu, Yazici, JPO 2002
    - 12 idiopathic graduates
    - Cobb
      - Pre-index öncesi  $58^{\circ}$
      - Pre-definitive  $59^{\circ}$
      - Successful results on both coronal and sagittal planes
    - Rotational increase( $>10^{\circ}$ ) 10/12
      - Insufficient control of axial plane deformity
      - Or cranksahfting?
    - 4 cm height gain



# Radiology -

- GR
  - Cahill et.al., Spine 2010
    - 9 graduates
      - Pre-index
        - »  $72^{\circ}$
      - Pre-definitive
        - »  $48^{\circ}$
      - Post-definitive
        - »  $28^{\circ}$
    - 89% autofusion
    - T1-S1 length increase
      - 3.7 cm, during lengthening
      - 4.1 cm, after definitive
      - Mean 7 PCOs



# Radiology +

---

- VEPTR
  - El-Hawary ve. ark., JPO 2016
    - 35 VEPTR pts, followed >5 years
    - T<sub>1</sub>-S<sub>1</sub> height
      - Average 15 lengthenings
      - From 20 cm to 28 cm
      - They maintained greater than 75% of expected age-matched spine growth
      - No Law of diminishing return



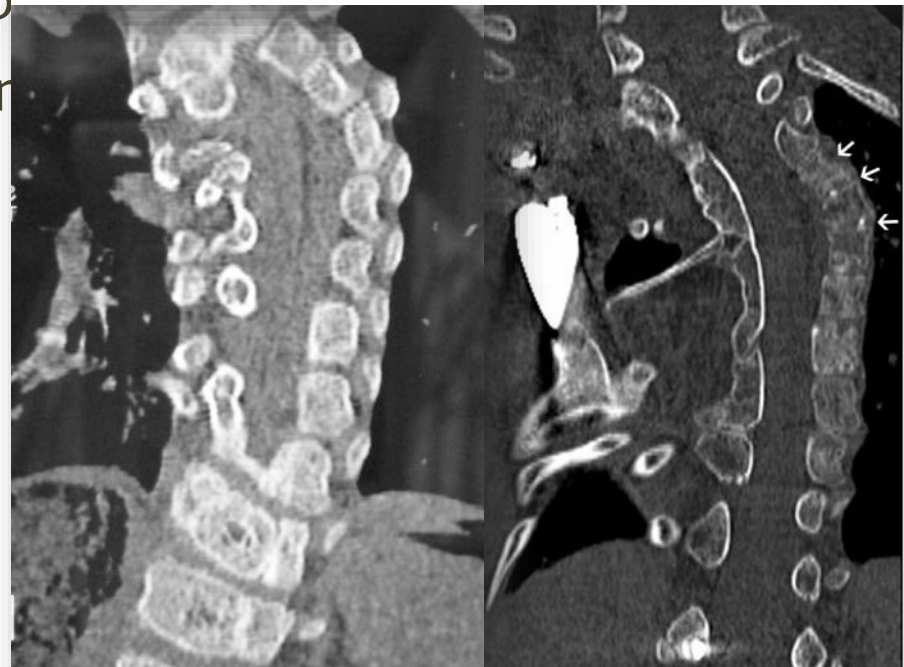
# Radiology -

- VEPTR
  - Samdani, IMAST 2
  - 33 VEPTR grade
  - » 48% autofusion
  - » No autofusion
  - » Autofusion

## ORIGINAL ARTICLE

Is Expansion Thoracoplasty a Safe Procedure for Mobility and Growth Potential of the Spine? Spontaneous Fusion After Multiple Chest Distractions in Young Children

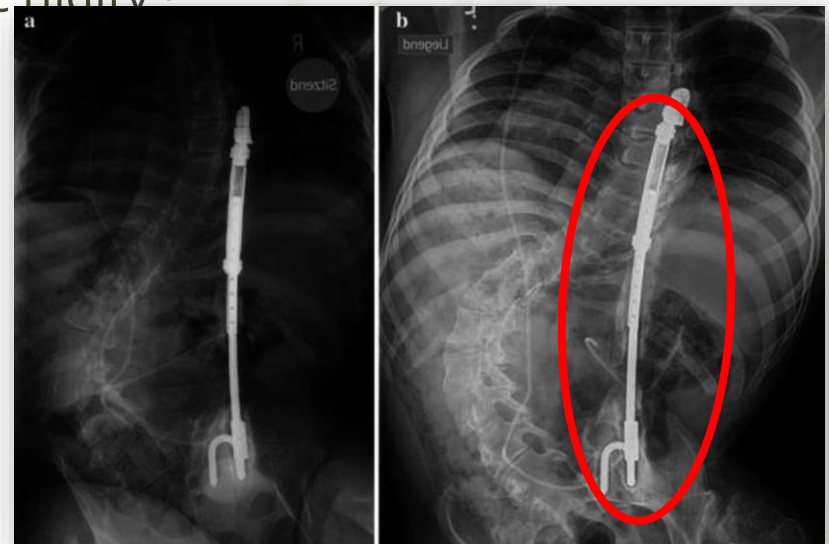
*Caglar Yilgor, MD, Gokhan Demirkiran, MD, Mehmet Ayyaz, MD, and Muharrem Yazici, MD*





# Radiology -

- VEPTR
  - Hasler, J Child Orthop 2014
    - 65 VEPTR
    - 65% peri-implant ossification
      - 45% full length of implant
      - Chest compliance and spine rigidity!

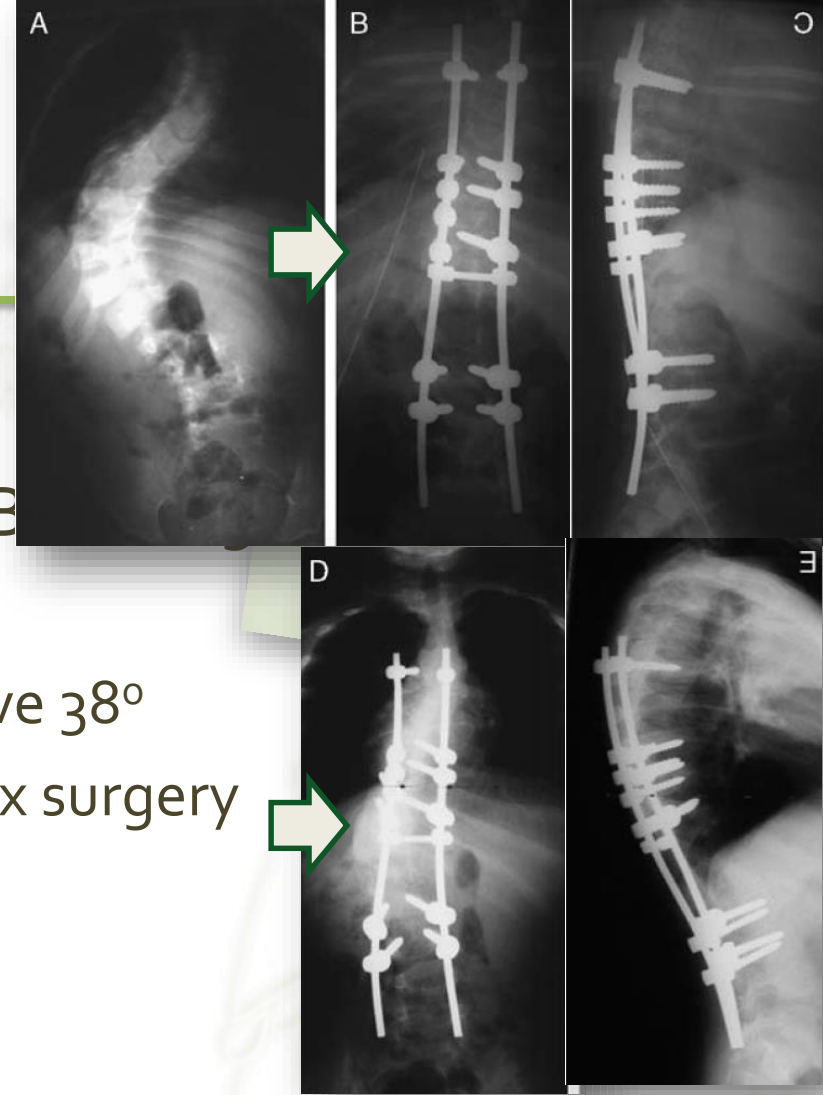


# Radiology +

- Shilla

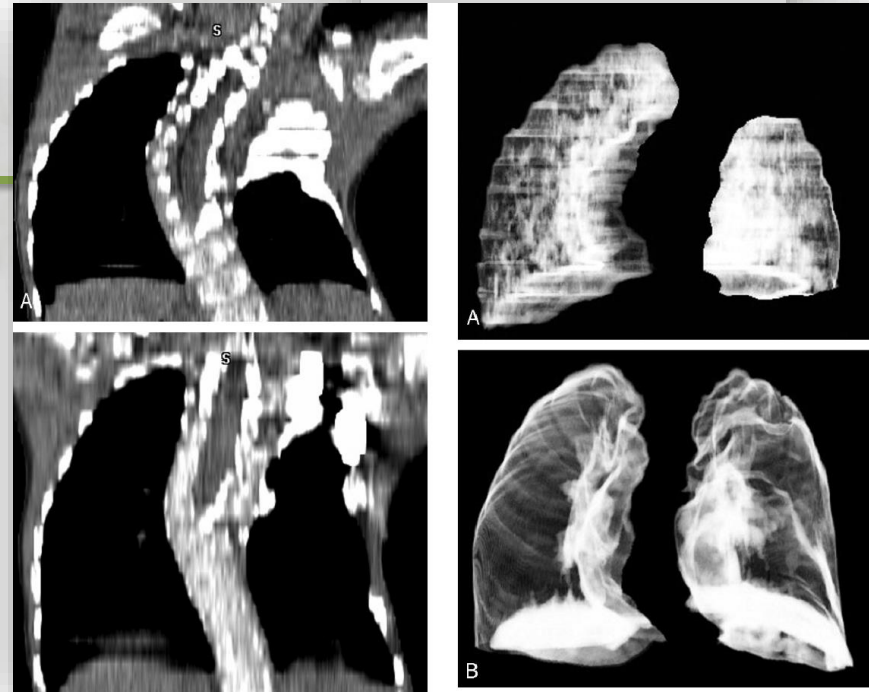
- McCarthy ve McCullogh, JB

- 40 Shilla patients
    - Pre-indeks  $69^{\circ}$ , pre-definitive  $38^{\circ}$
    - Spinal length gain, inc. index surgery
      - T1-12 0.7 cm/year
      - T1-S1 1.5 cm/year
    - Rotation?



# Lung +

- Emans et.al., Spine 2005
  - 31 congenital scoliosis with rib fusion
  - VEPTR after thoracotomy
  - Volume with CT
    - Volume increase
      - @ VEPTR side 219 %
      - Control side 147 %
    - Pulmonary functions?
  - 1.2 cm/year thoracic spine growth
    - Spinal penetration?



# Lung +

---

- Jiang et.al., Chin Med J 2011
  - 8 GR patients, 4 grad
  - Significant improvements on pulmonary functions
    - FVC and FEV<sub>1</sub> both increased
    - Ratio of FVC to predicted FVC and ratio of FEV<sub>1</sub> to predicted FEV<sub>1</sub> changed similarly and did not show statistical differences
      - Short trunk!



# Lung +/-

---

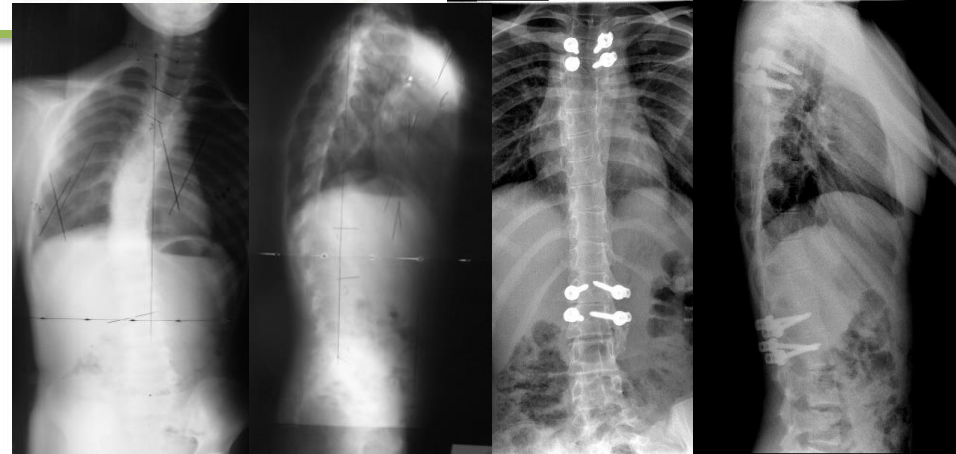
- Johnston, Spine Def 2016
  - 12 grad
  - Oxygen consumption
    - Clinically relevant pulmonary compromise
    - These children are able to keep up with their peers in daily activities and also have the capacity to exercise



# Lung -

---

- Dede et.al., JBJS 2014
  - 21 VEPTR
    - Pulmonary function test
      - Passive deflation techniques, GA
        - » Index surgery, lengthening
      - Absolute FVC increase, predicted FVC decrease
      - Chest compliance!



- Index surgery
  - 74 months
- Preop height
  - 115 cm
- # Surgery
  - 10
  - + Index + definitive
  - No unplanned surgery
- Final height
  - 151.5 cm
- FVC: 2 L / 76%
- FEV 1: 94%

- Index surgery
  - 74 months
- Preop height
  - 115 cm
- # Surgery
  - 10
  - + Index + definitive
  - No unplanned surgery
- Final height
  - 151.5 cm
- FVC: 2 L / 76%
- FEV 1: 94%



# Lung

---

- Can TGR change the natural history of pulmonary functions in EOS? Is Radiological Straightness Correlated with Normal Lung Development?
- Ebru Celebioglu, Alper Yataganbaba, Aslı Öncel, Ceren Degirmenci, I Aykut Kocyigit, Fatih Tekin, Gokhan Demirkiran, Elmas Ebru Yalcin, Ahmet Ugur Demir, Muharrem Yazici
- TGR can help EOS patients, who would otherwise be doomed to serious pulmonary insufficiency, achieve pulmonary capacities compatible with a healthy life
- Despite significant decreases in TGR graduates in oxygen consumption capacity and pulmonary tests compared to healthy controls, results were not statistically different than AIS patients
- TGR is effective and successful in achieving good results in pulmonary functions as well as radiological parameters

# How we finish?

---

- Don't touch spine, leave as it is!
- Remove implant and free the spine!
- Reconstruct (re-create) the spine with new implants and/osteotomies

# Graduation

---

- Flynn , JBJS 2013
  - 86% instrumented fusion
  - 13% GR+ in-situ fusion
  - 1% GR removal
- Sponseller, JBJS 2016
  - 137 definitive fusion, 26 GR only
  - Definitive fusion
    - No extra benefit regarding Cobb and spinal height
- Sawyer, Spine Def 2016
  - 37 VEPTR grad (12 observation, 25 definitive instrumentation)
  - Observation works!
  - Limited effect of instrumentation (Additional surgery in 24%!)

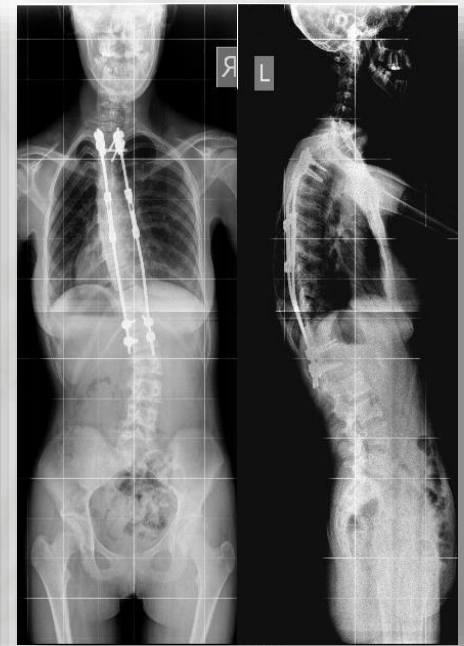
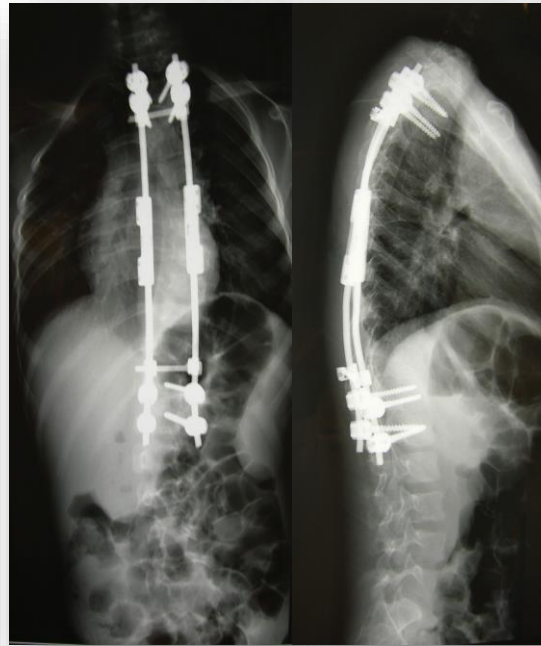
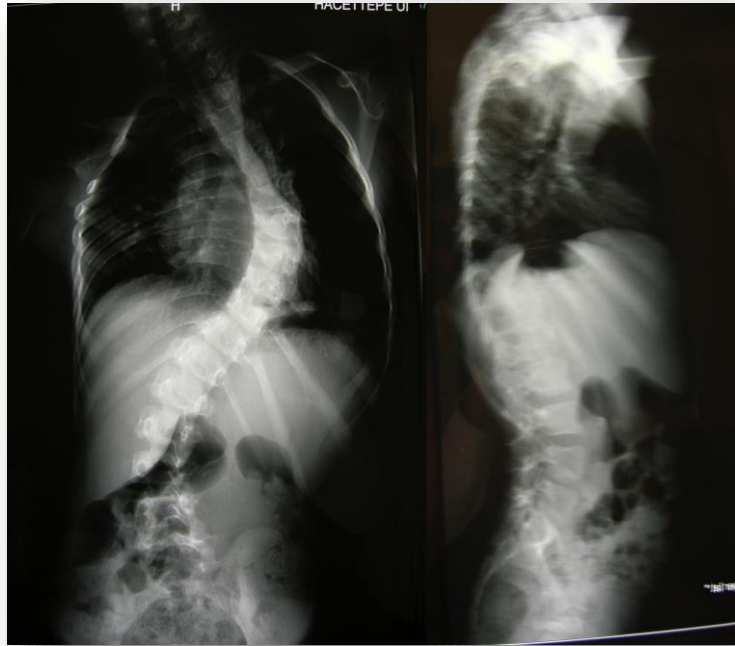# Final fusion is final?

---

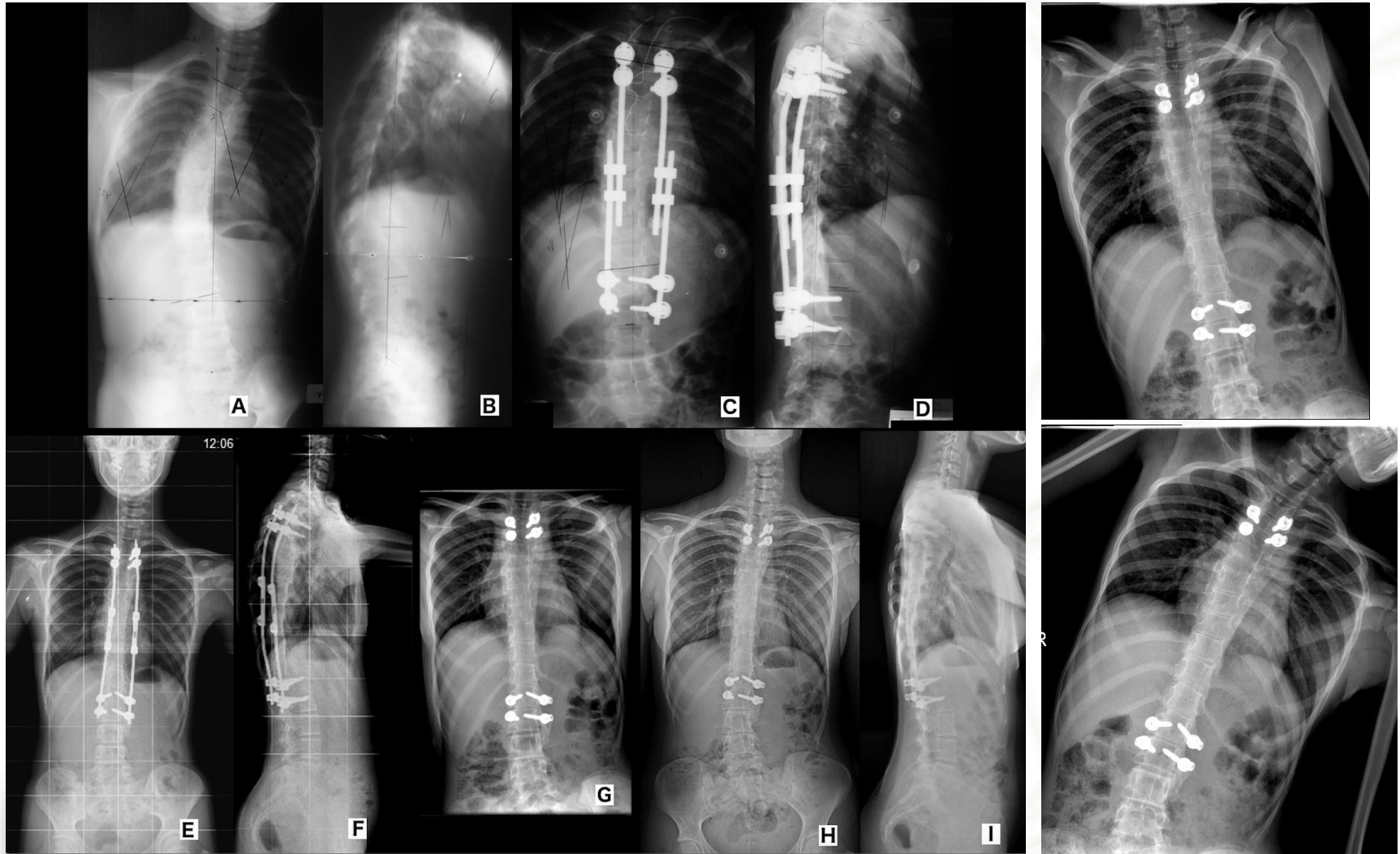
- Poe-Kochert, JBJS 2016
  - 119 grads.
  - Additional surgery after definitive fusion
    - 20 %
    - Re-surgery 7.4 year after final fusion

# Don't touch

---



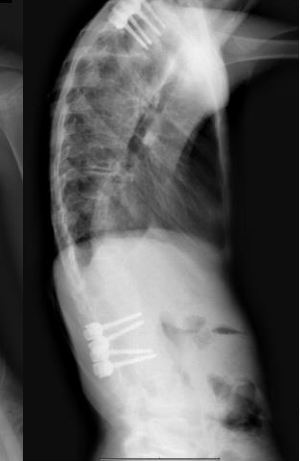
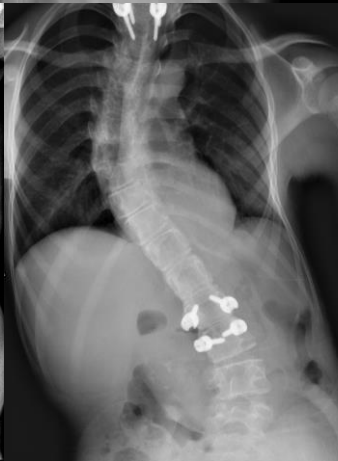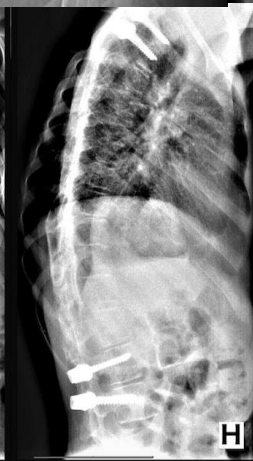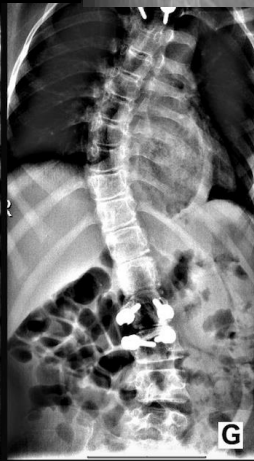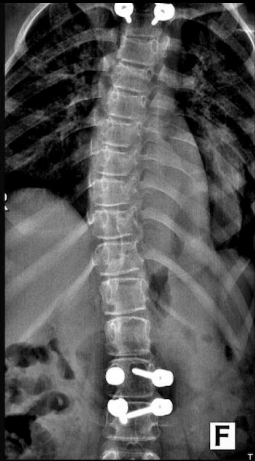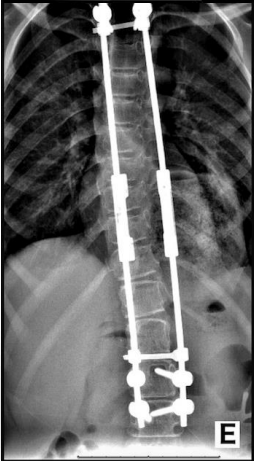
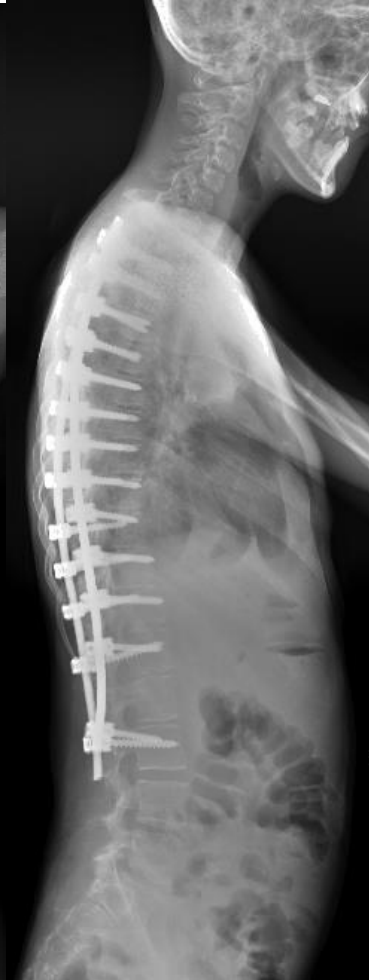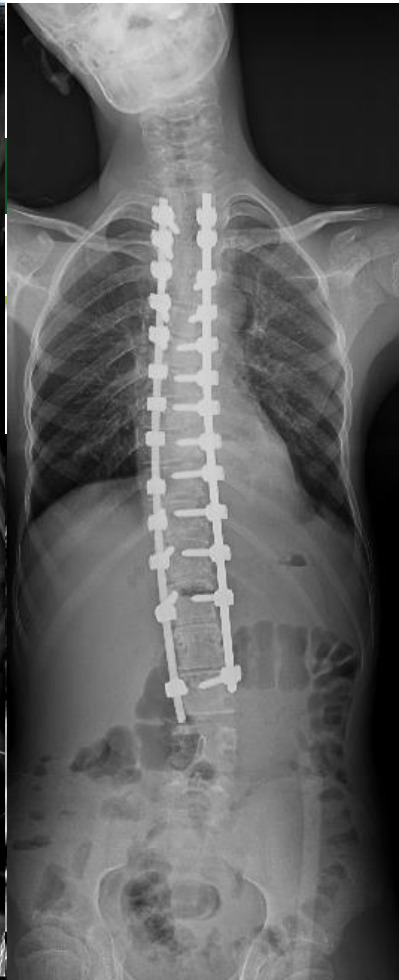
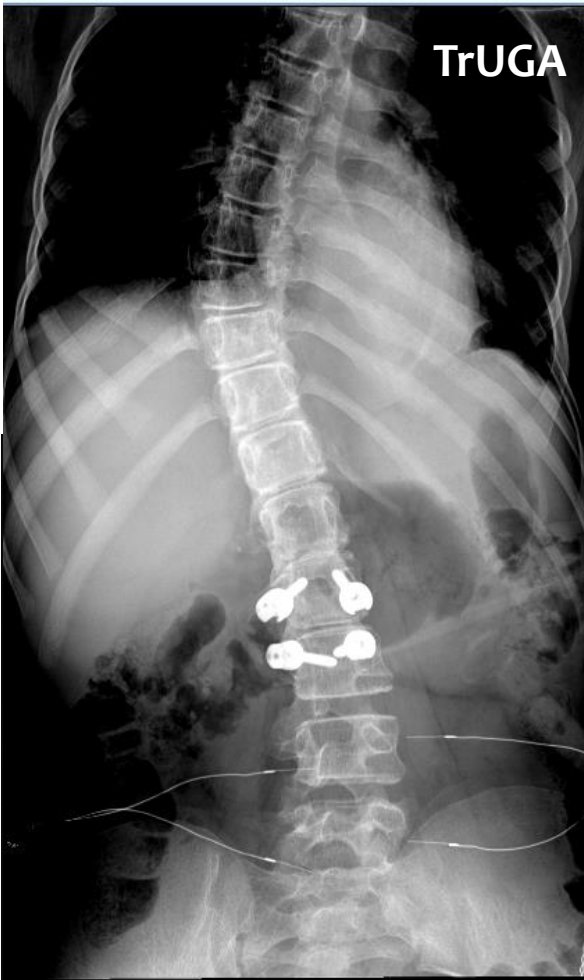# Remove implant and free the spine..





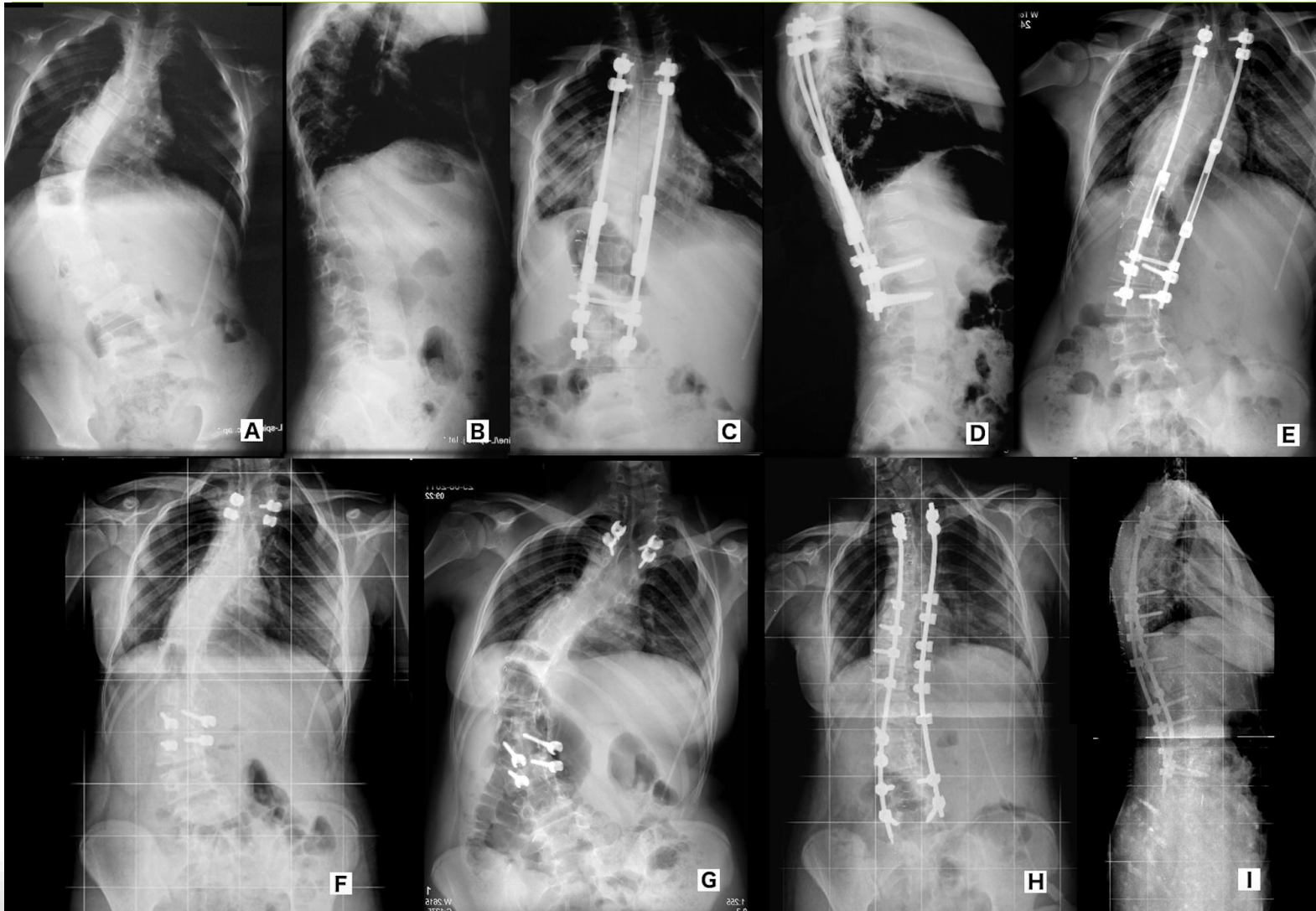
TrUGA

pine..

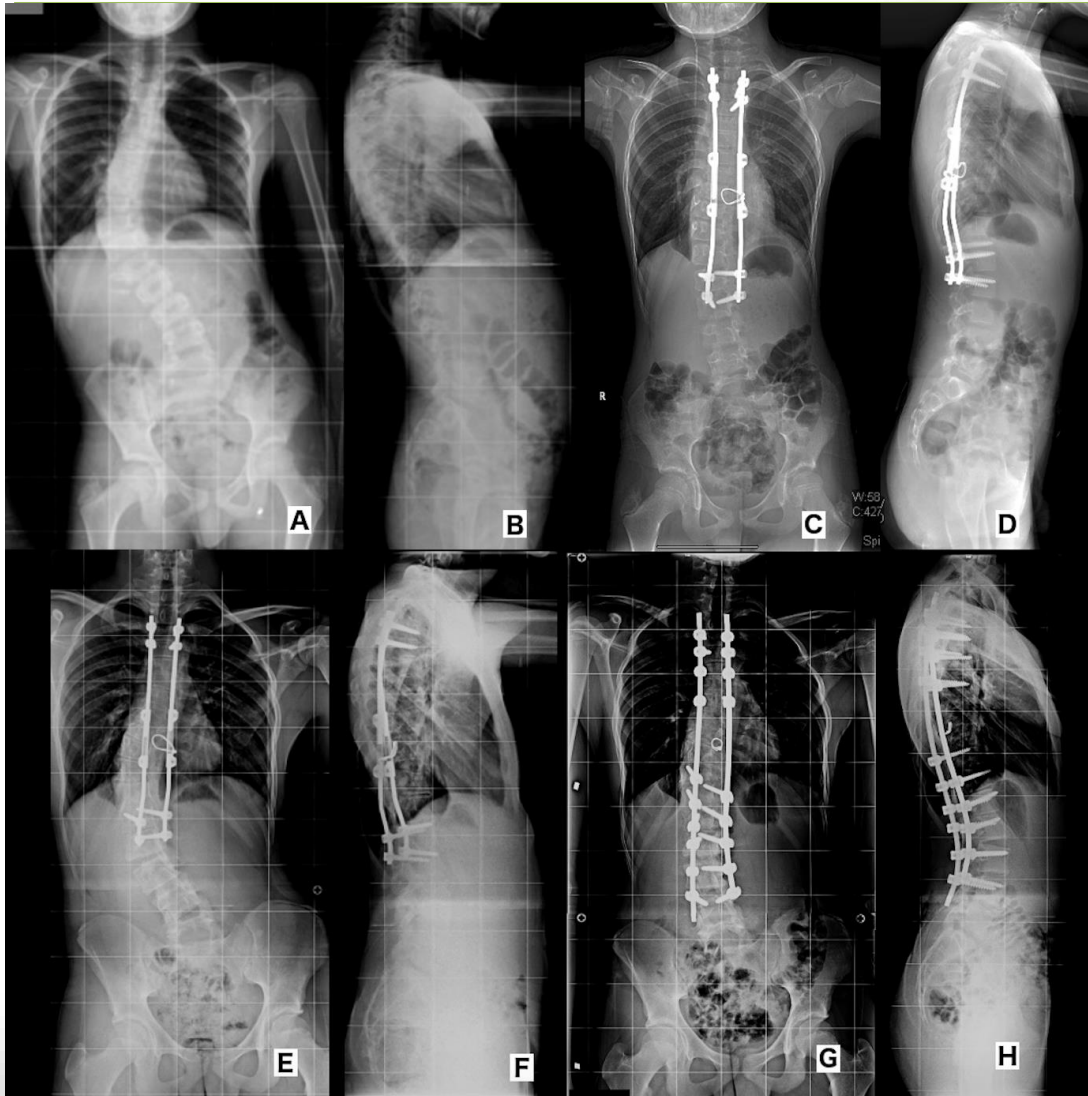




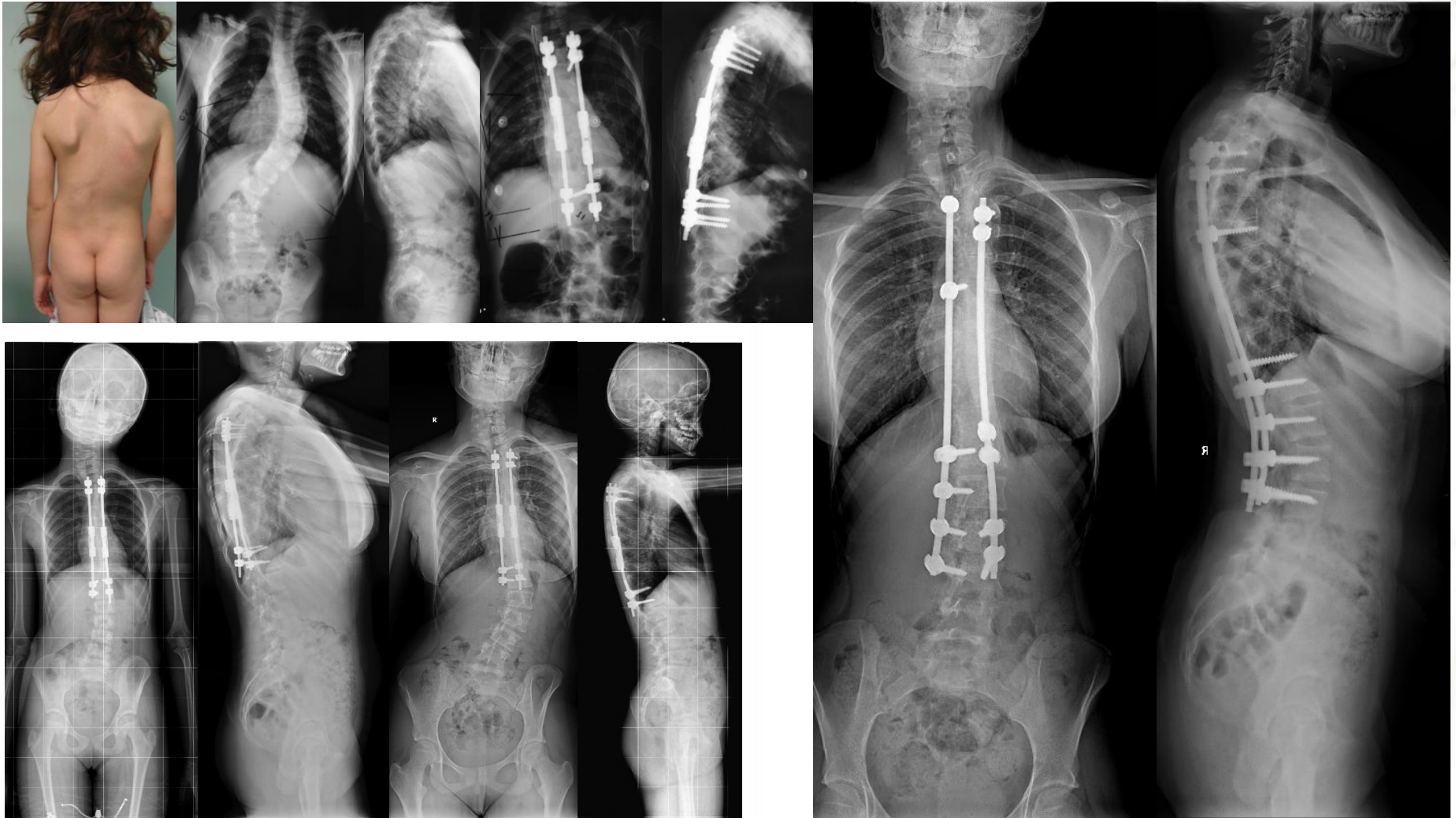# Remove implant and free the spine..



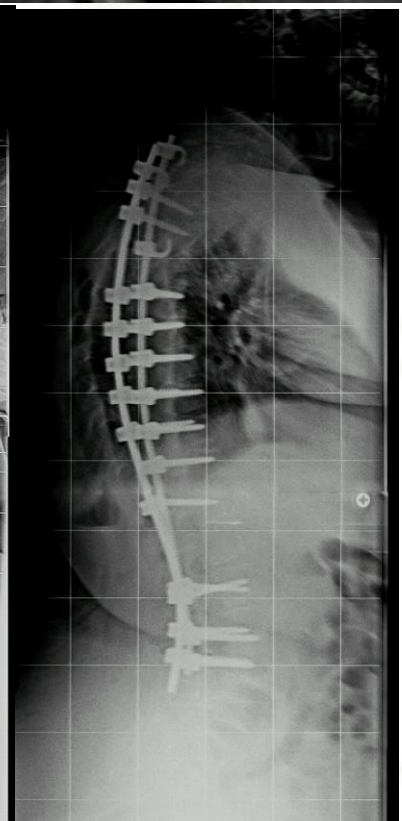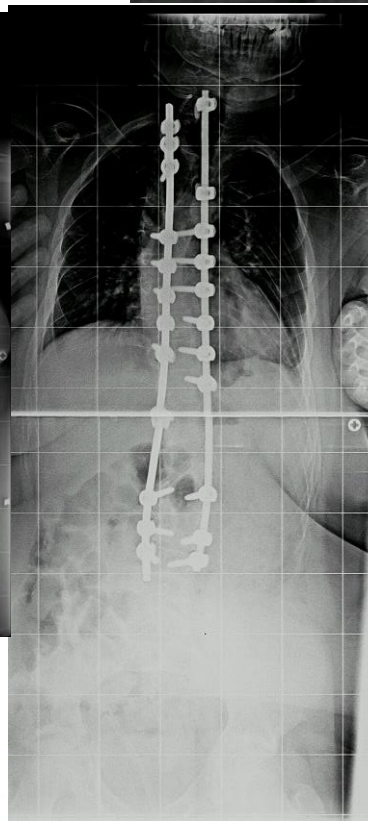
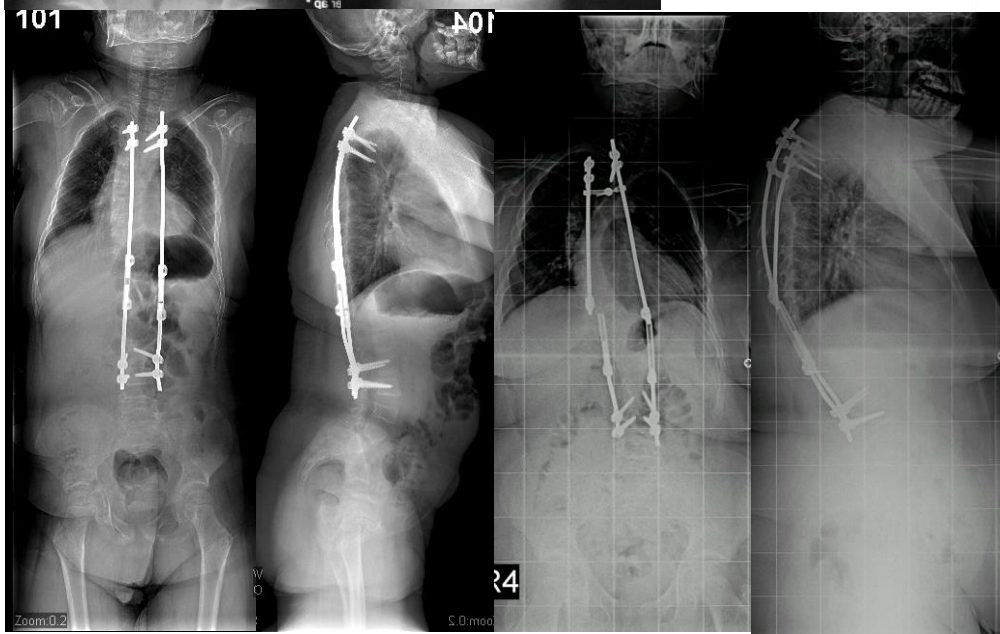
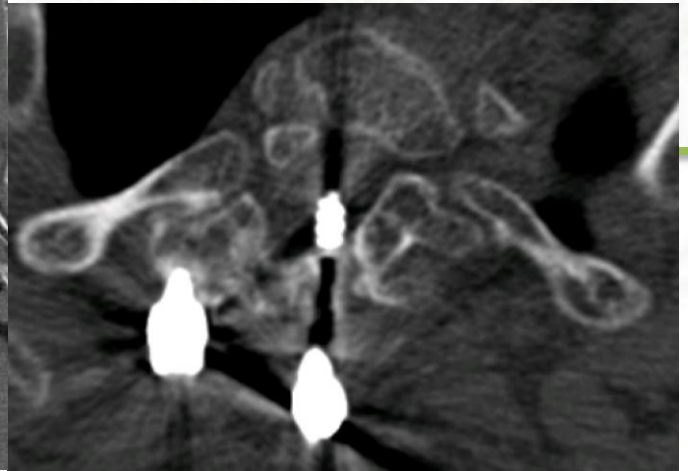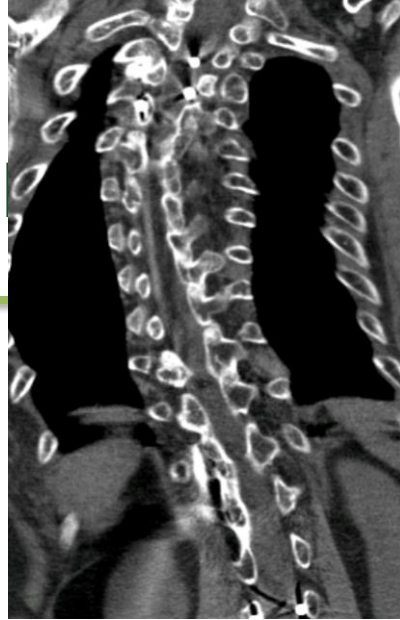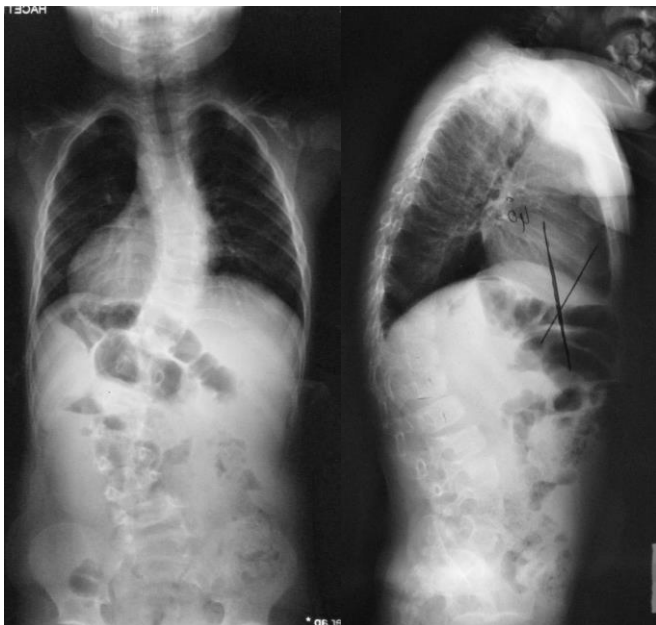
# We need more!



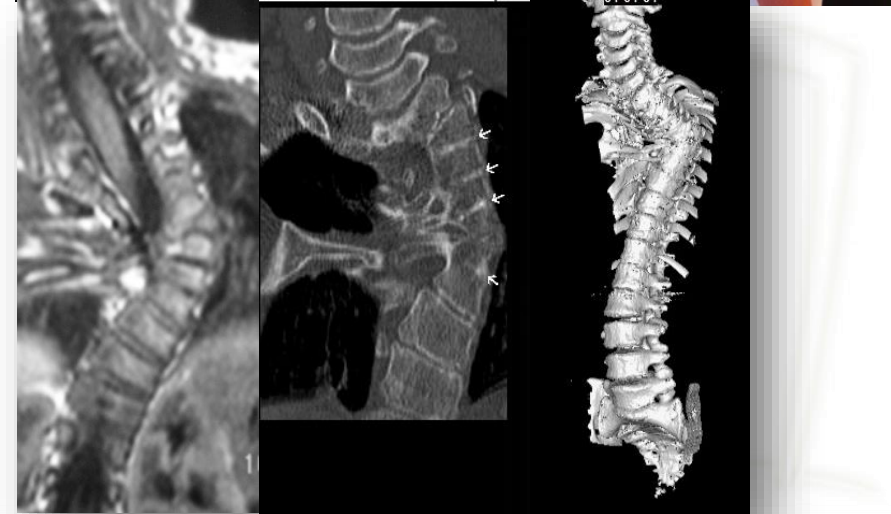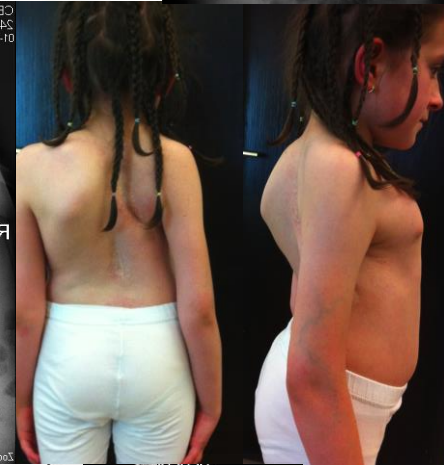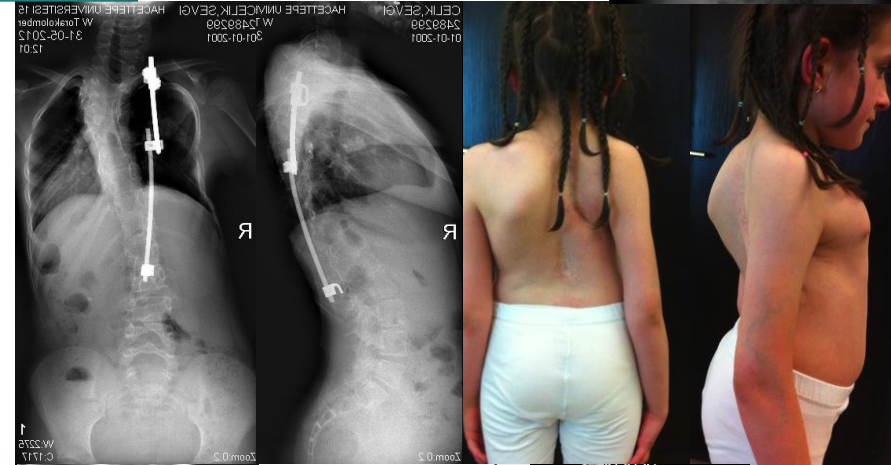
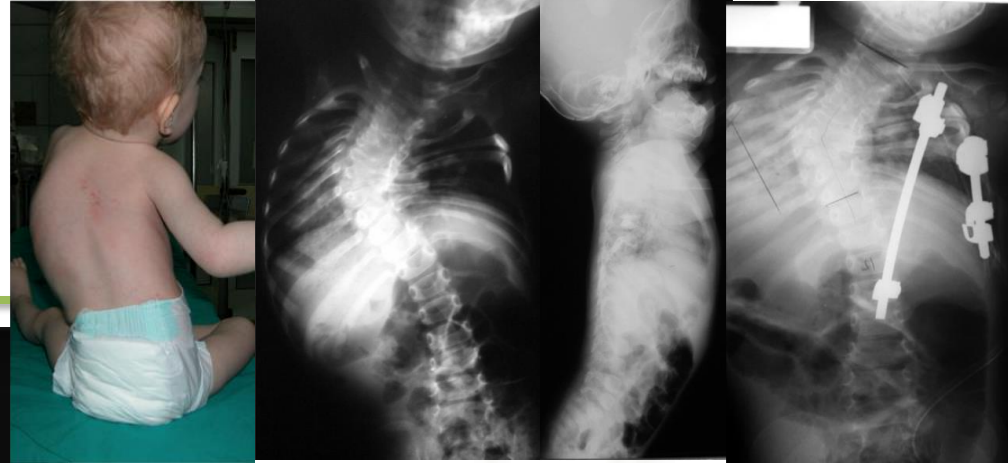
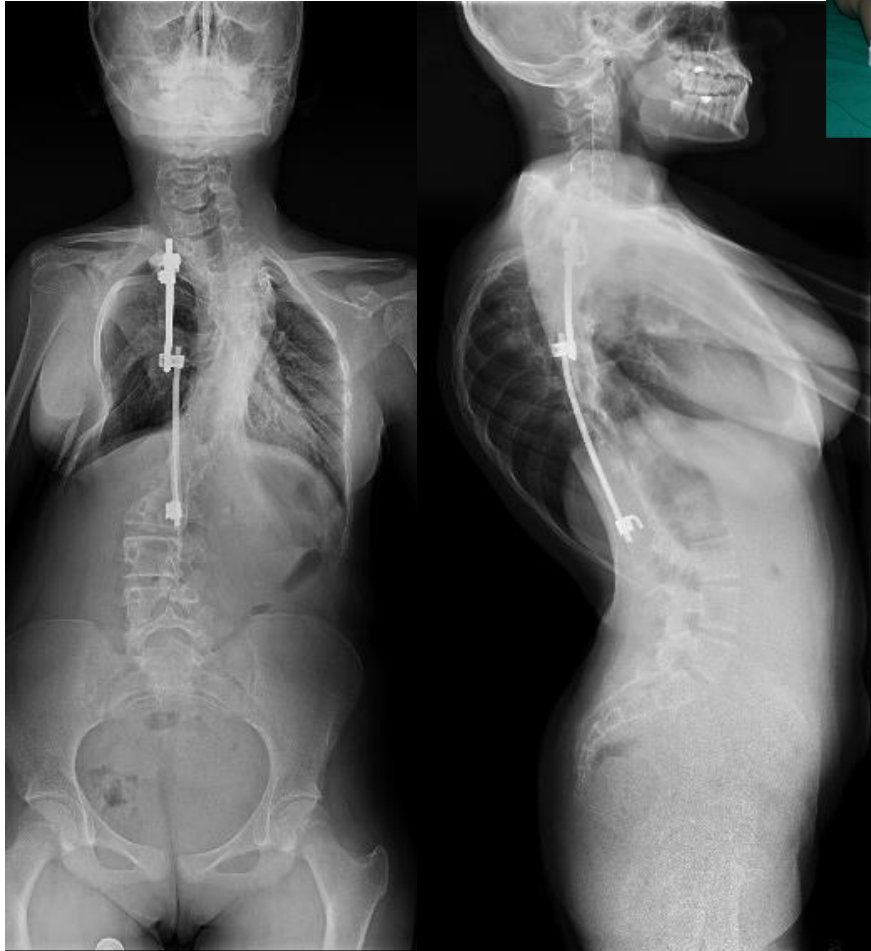# We need more!





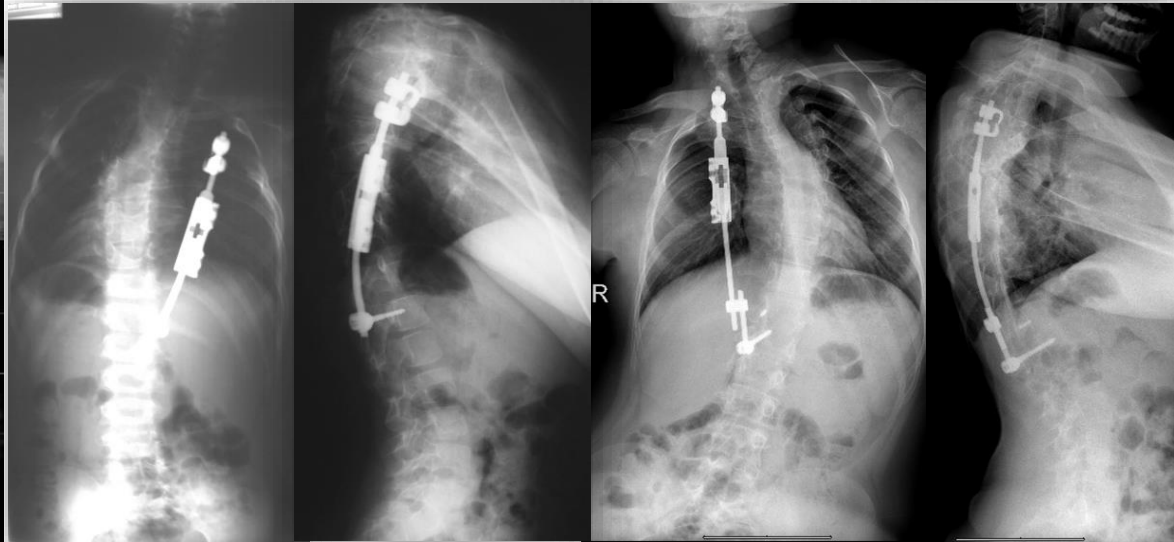
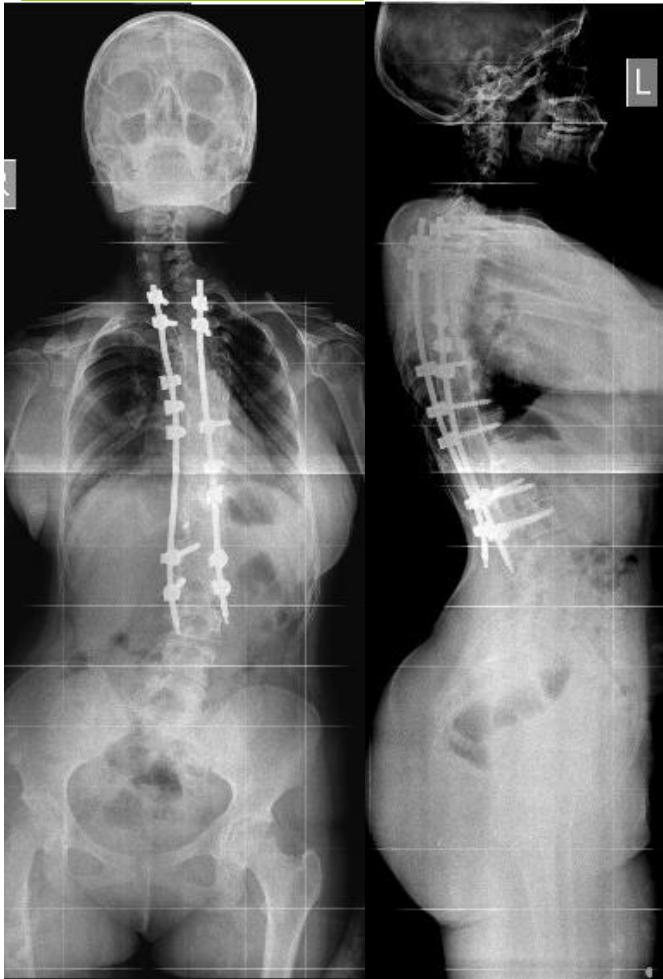
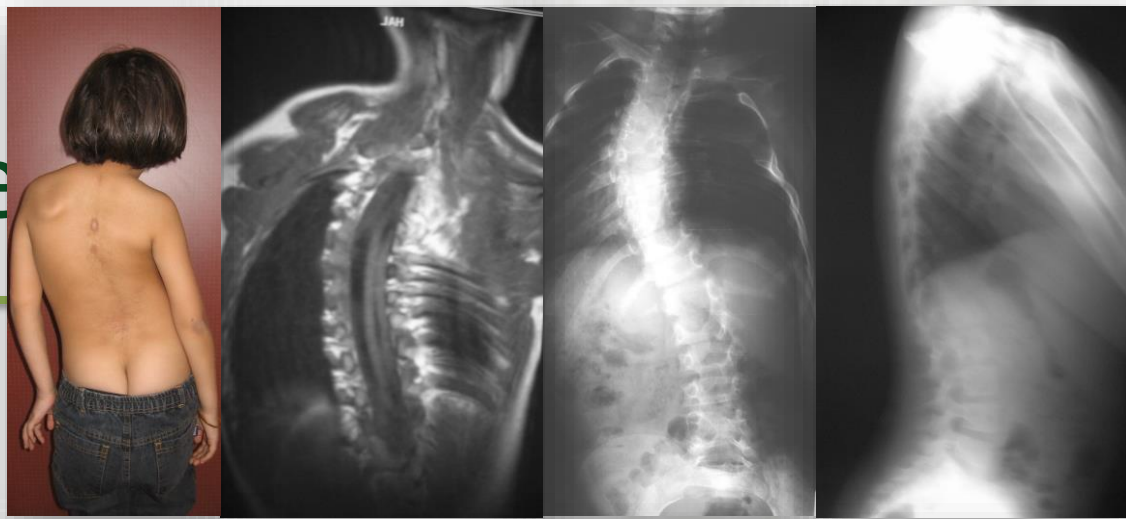

# Don't touch

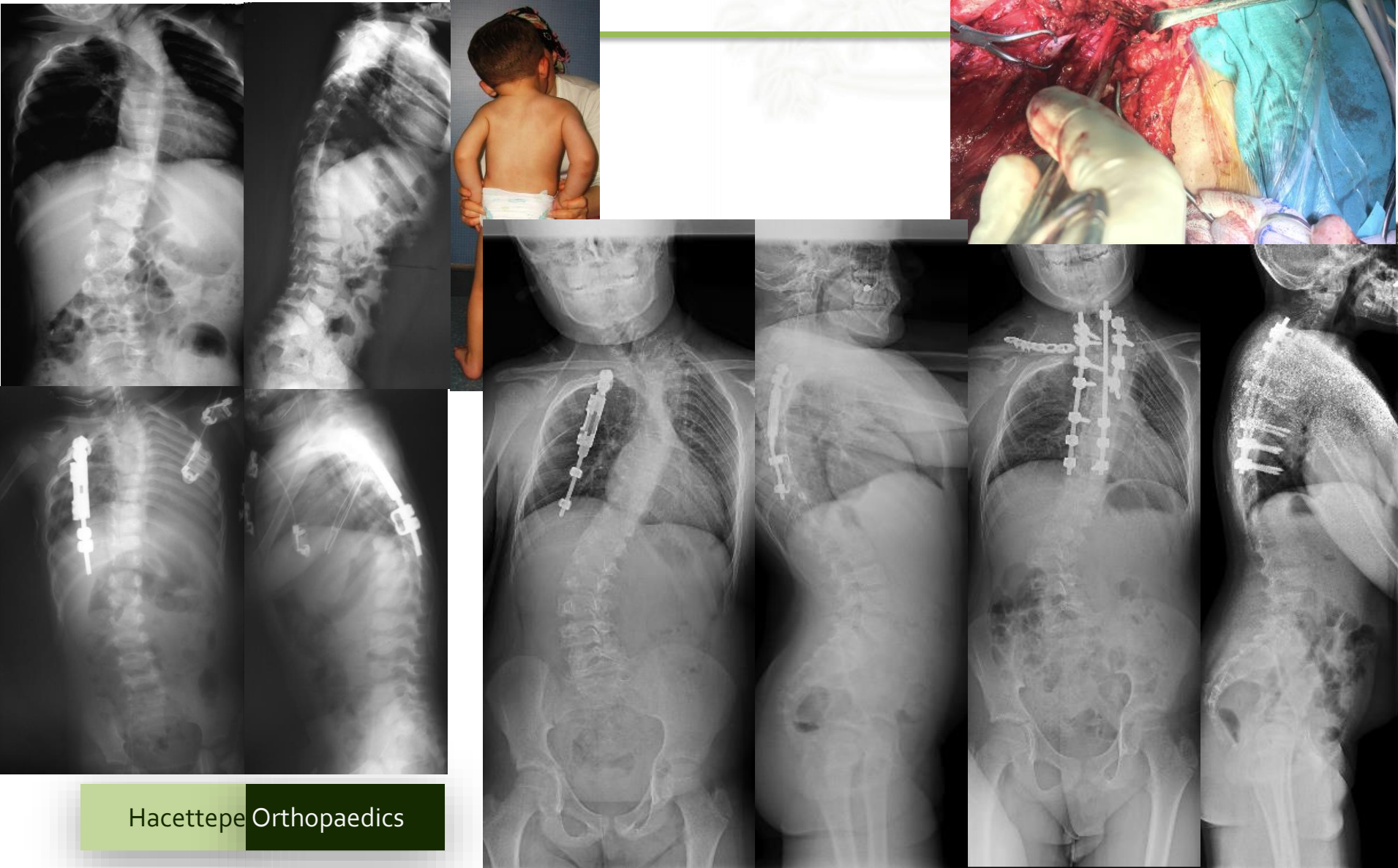



# We need more

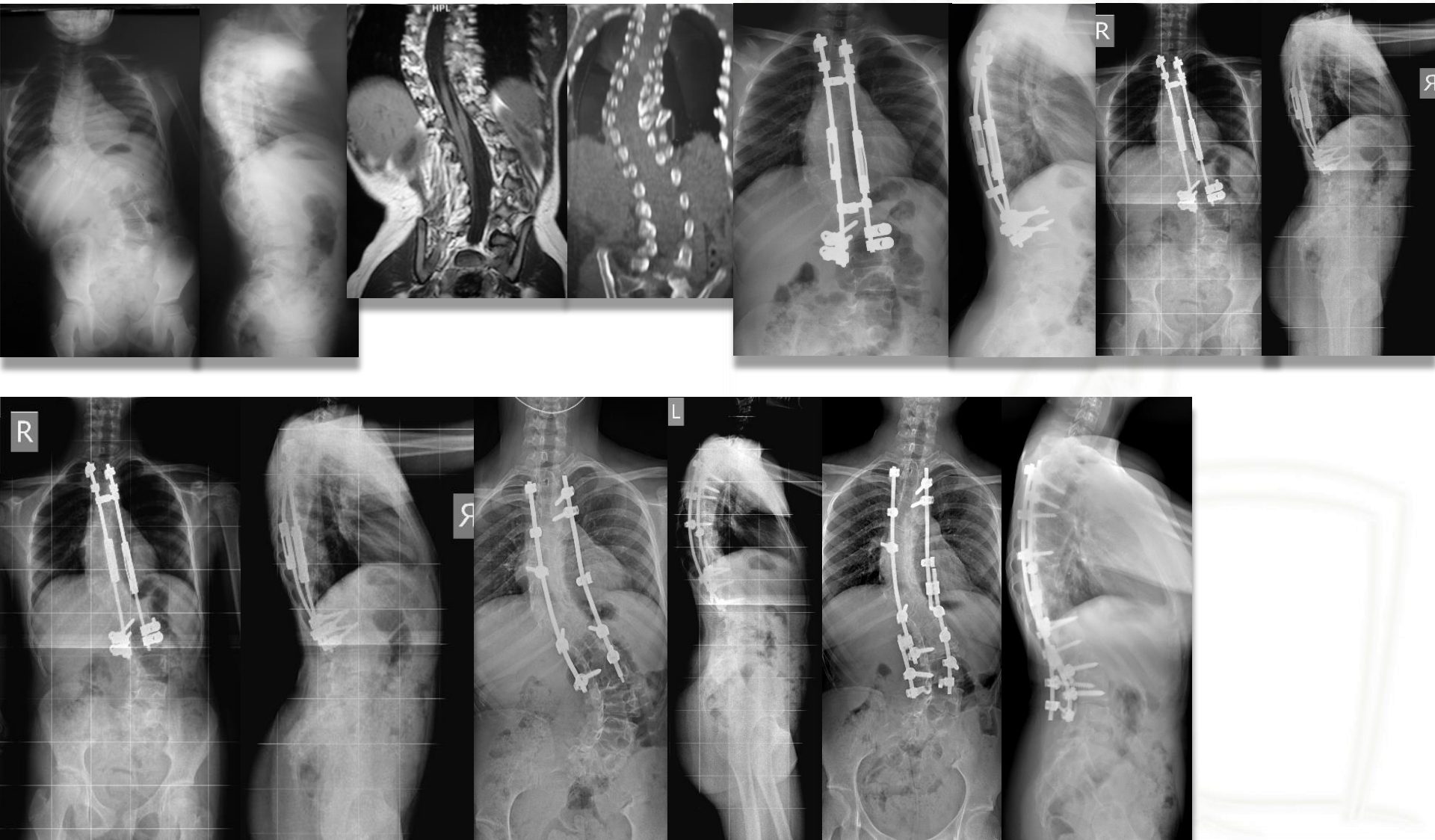

# We need more!

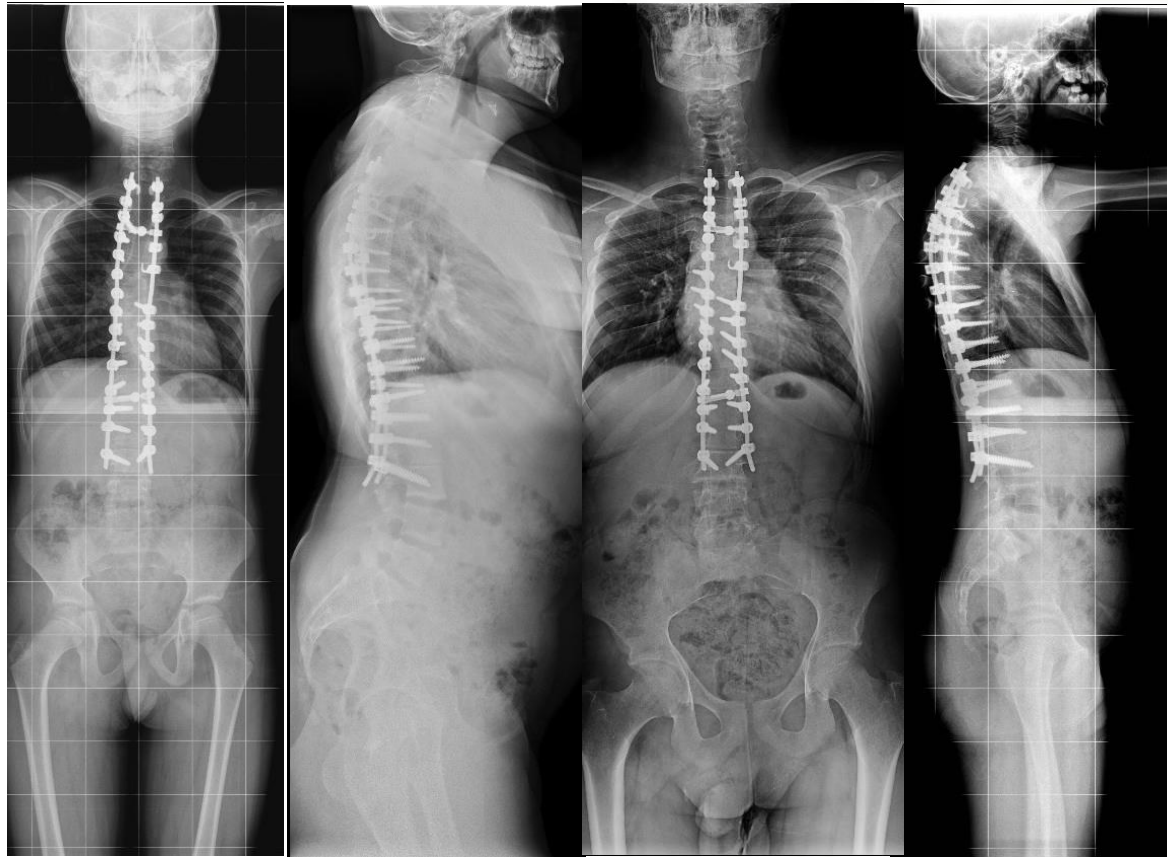
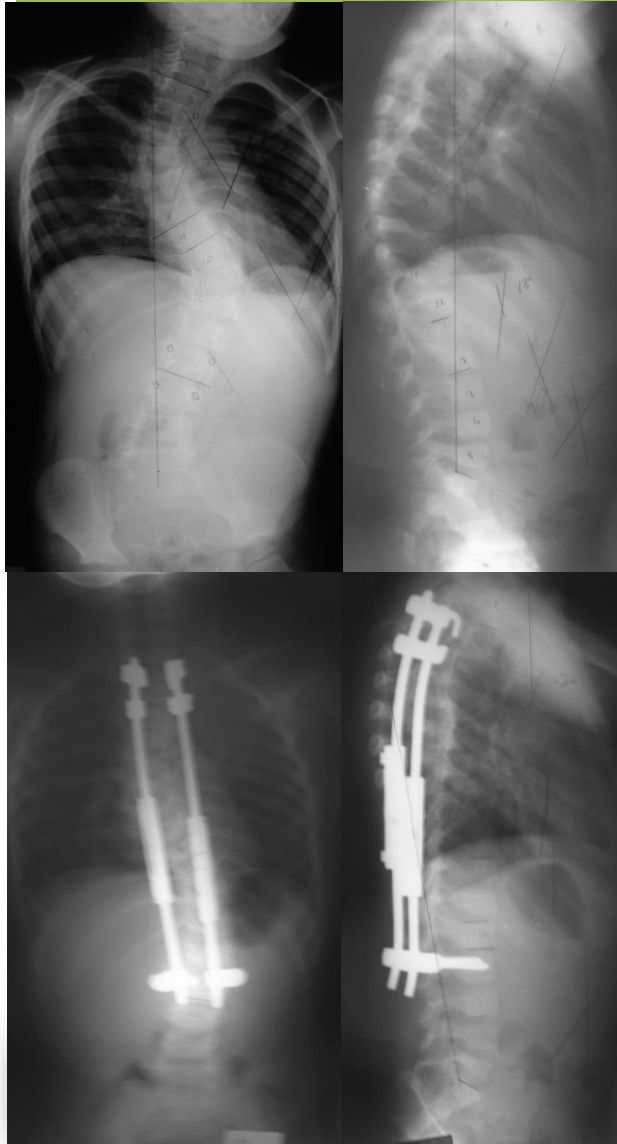




# Final fusion is final?



# Final fusion is final?



# Conclusion

---

- Removal of growing rod hardware after a measure of skeletal maturity has been achieved is not an acceptable end point for growing rod treatment
- Retaining hardware if curve features are acceptable
- Needs FU evaluation
  - Risk for further implant and/or deformity related problems?