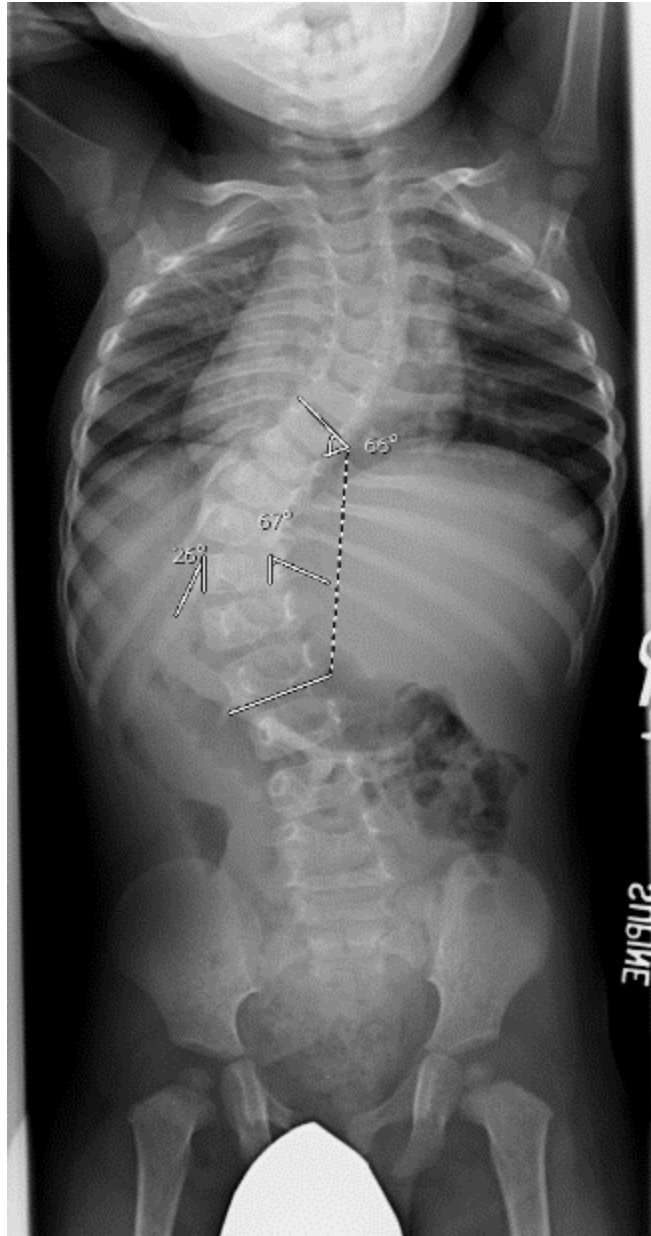


# Something I Wouldn't Do Again...

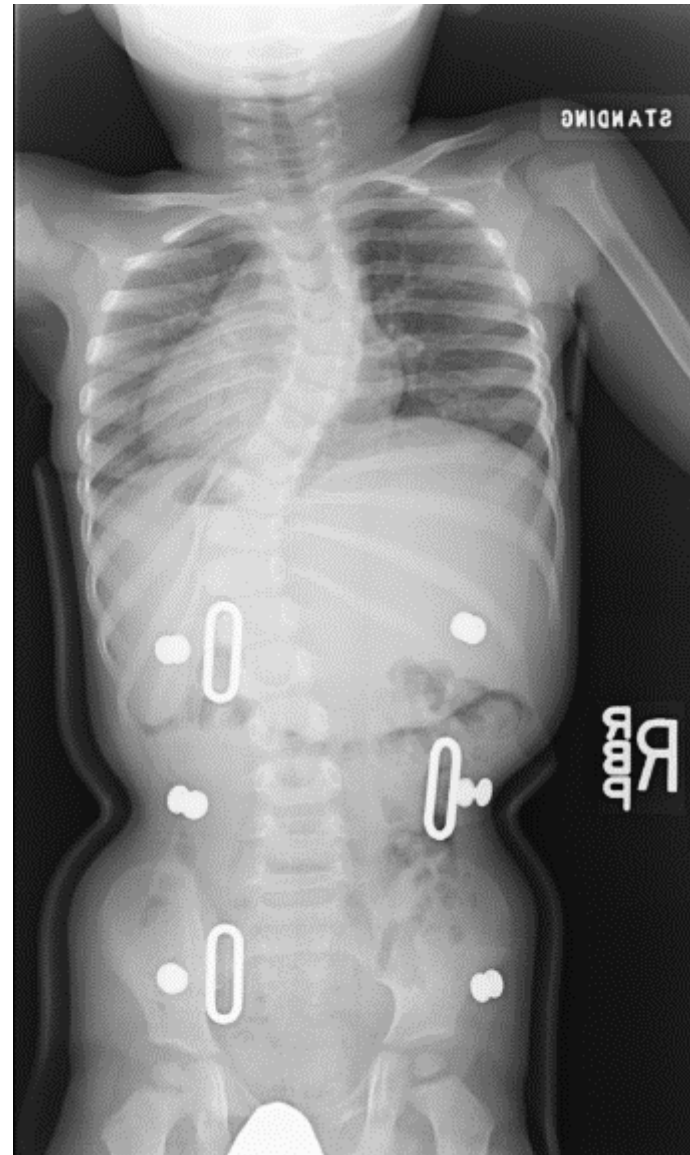
Ramo ICEOS 2017

- 15 month old male
- Infantile idiopathic scoliosis
- Circa 2001
- Treated initially with two Risser casts
- Transitioned to TLSO until age 11
- Wore TLSO for 20-23 hours/day for 10 years

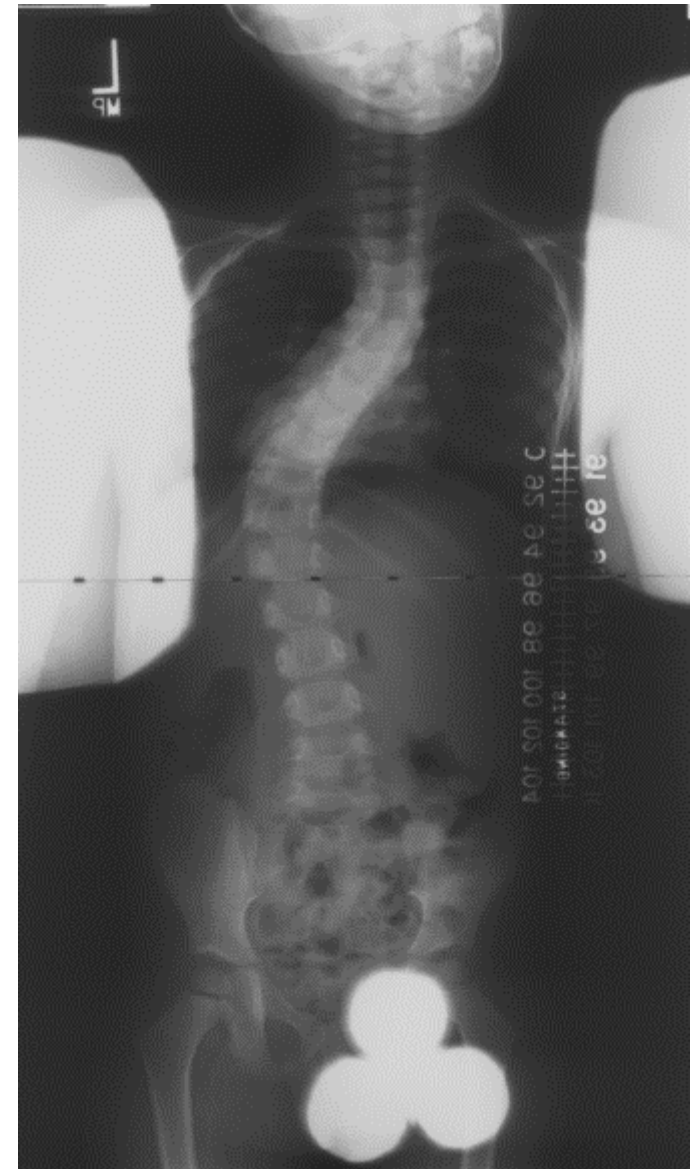
Age 16 months



Age 24 months

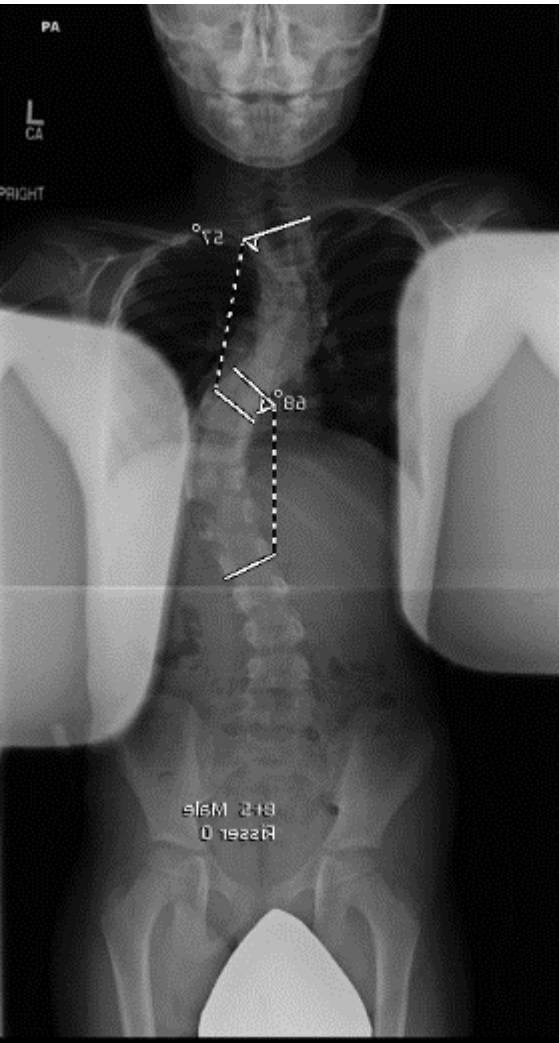


Age 48 months

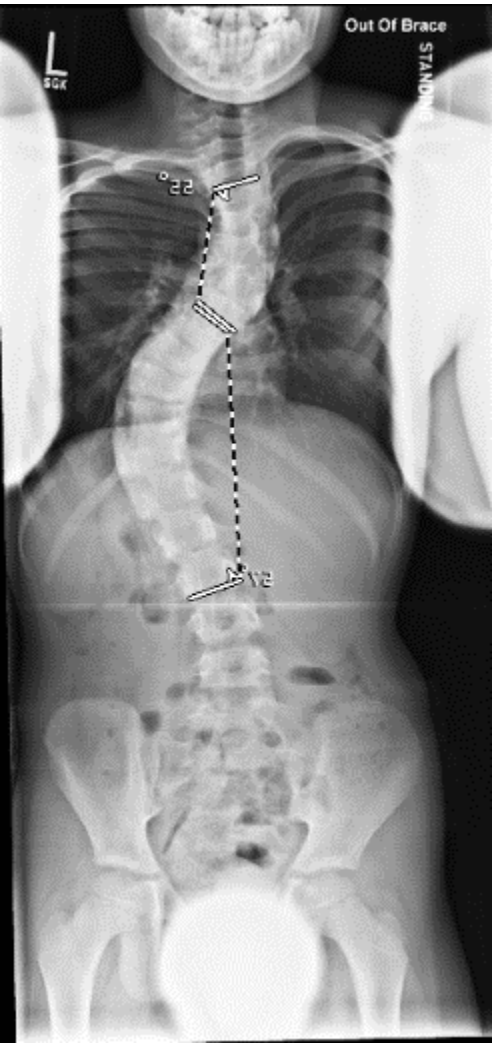


Braced for several years....

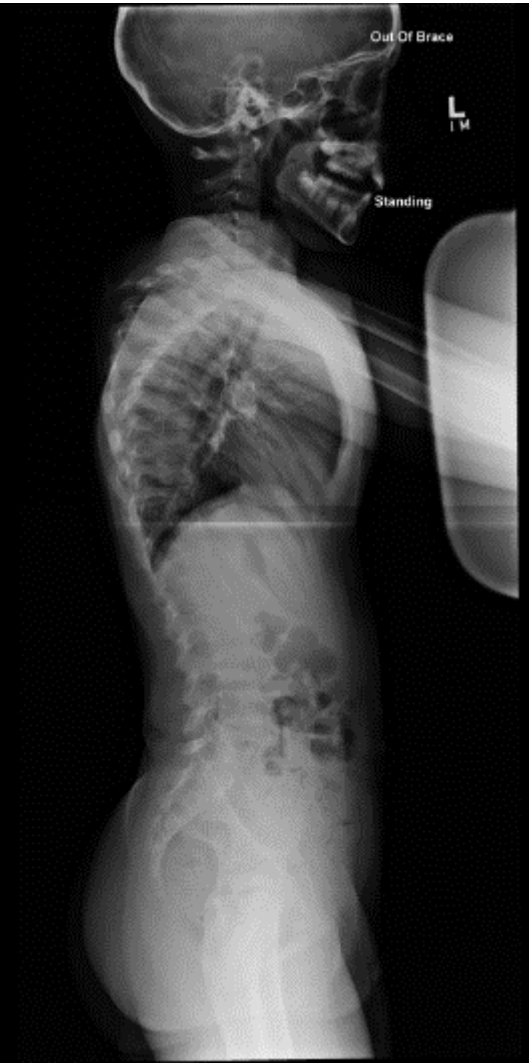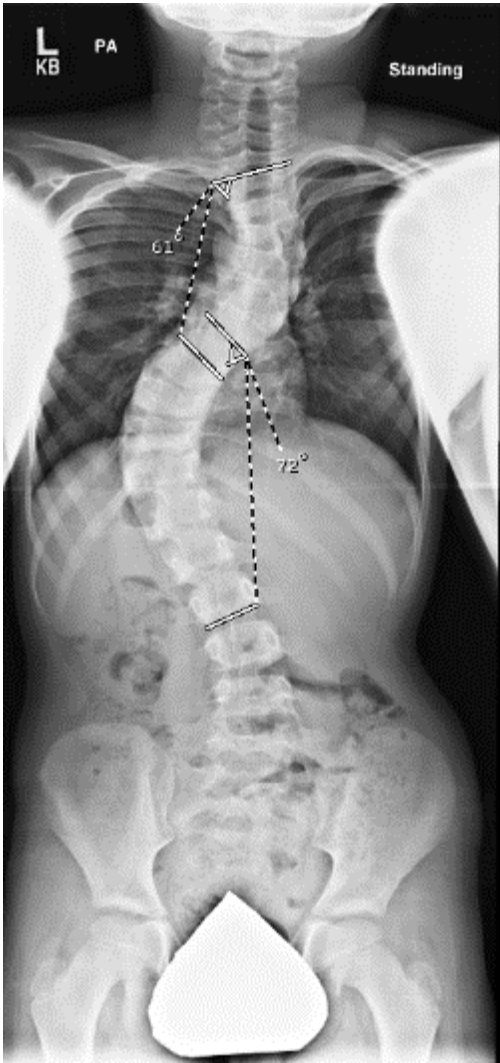
Age 8



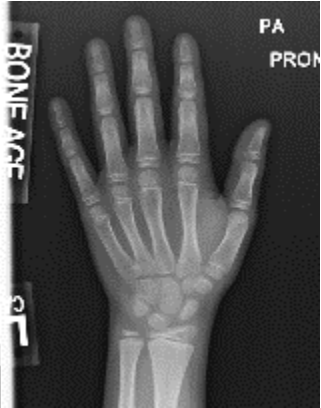Age 10



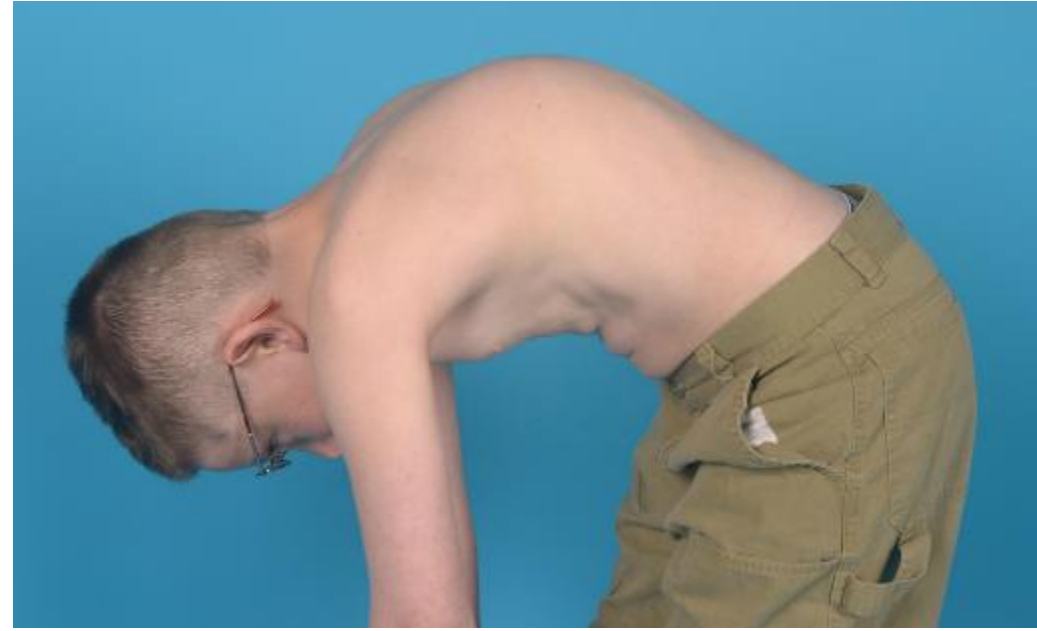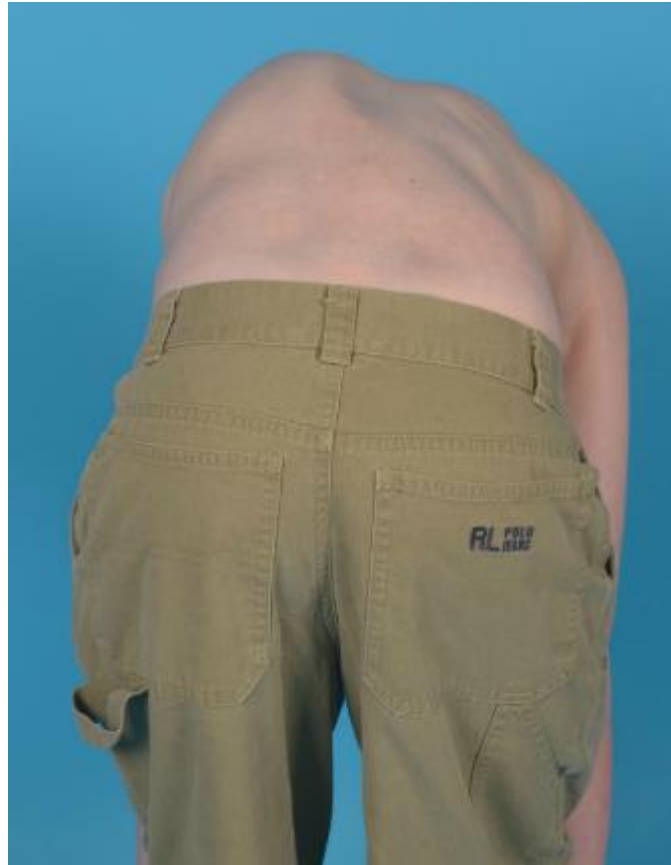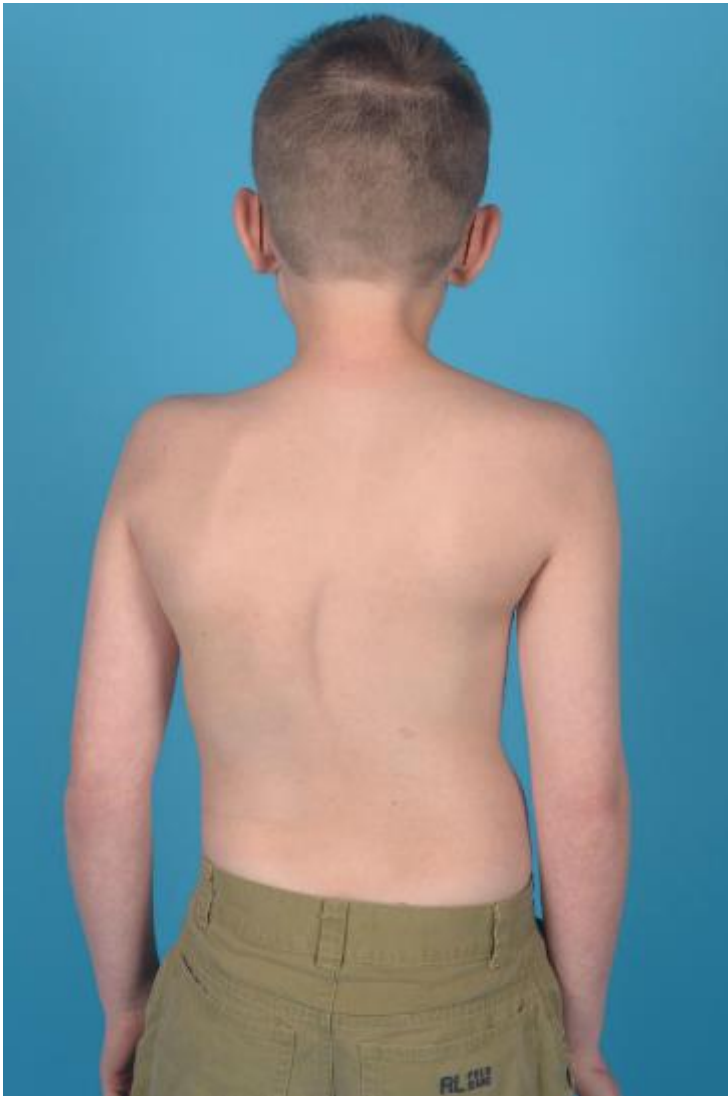Age 11



T1-T12 = 17cm  
Bone Age =10



Age 11+3



# Fixed Ends, Gliding Apex

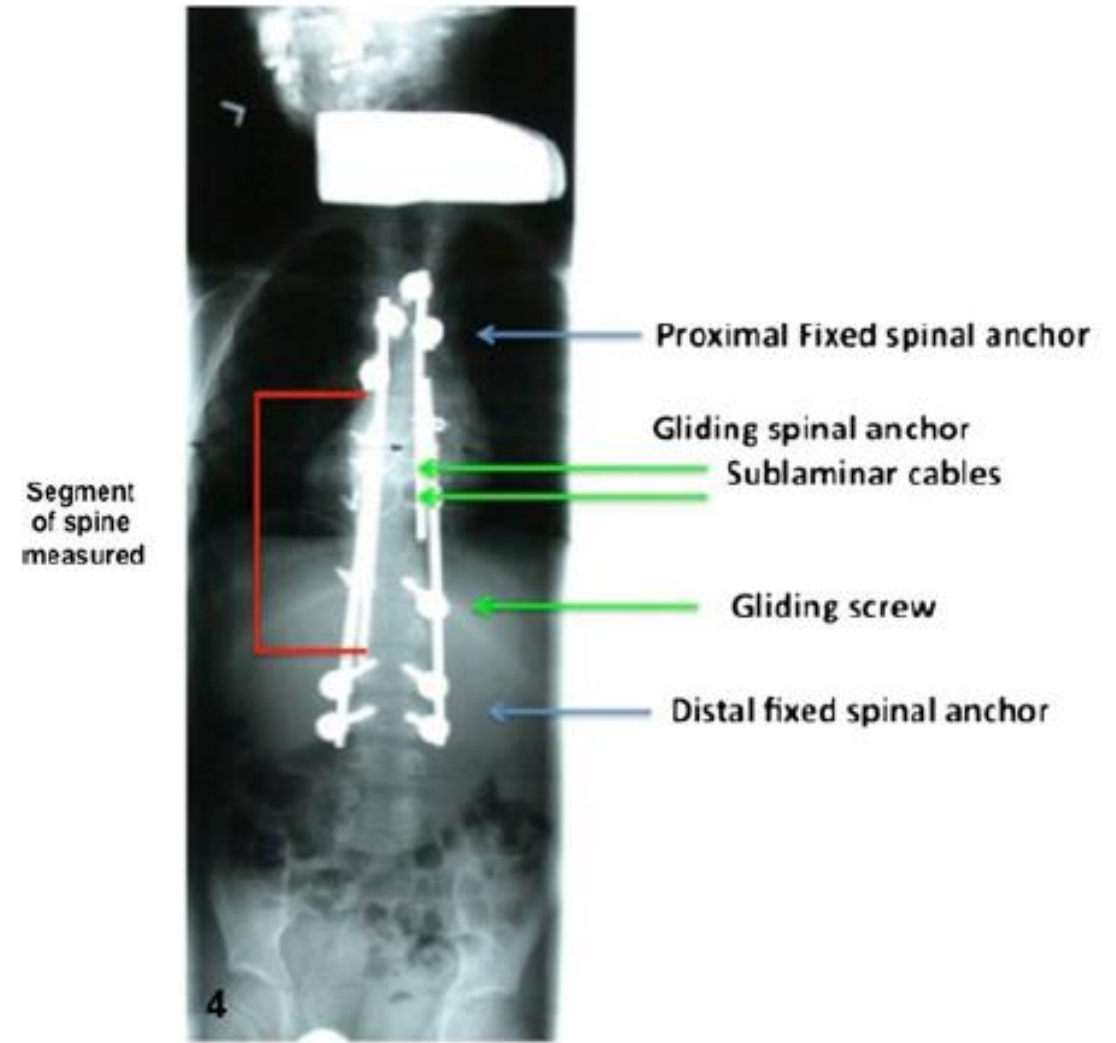
Clin Orthop Relat Res (2011) 469:1356–1367  
DOI 10.1007/s11999-011-1783-4

SYMPOSIUM: EARLY ONSET SCOLIOSIS

## Surgical Technique

### *Modern Luqué Trolley, a Self-growing Rod Technique*

Jean Ouellet MD, FRCSC



**Fig. 4** Classic construct of a modern Luqué trolley consisting of two proximal claws (or four proximal screws) and four distal pedicle screws as fixed anchors are shown. Two intercalated sublaminar cables are placed across the thoracic curve and one gliding screw at the apex of the lumbar curve.



Anterior Release T10-T12, fixation at T10-T12 (gliding)  
Domino used on left and Apical Wires on Right

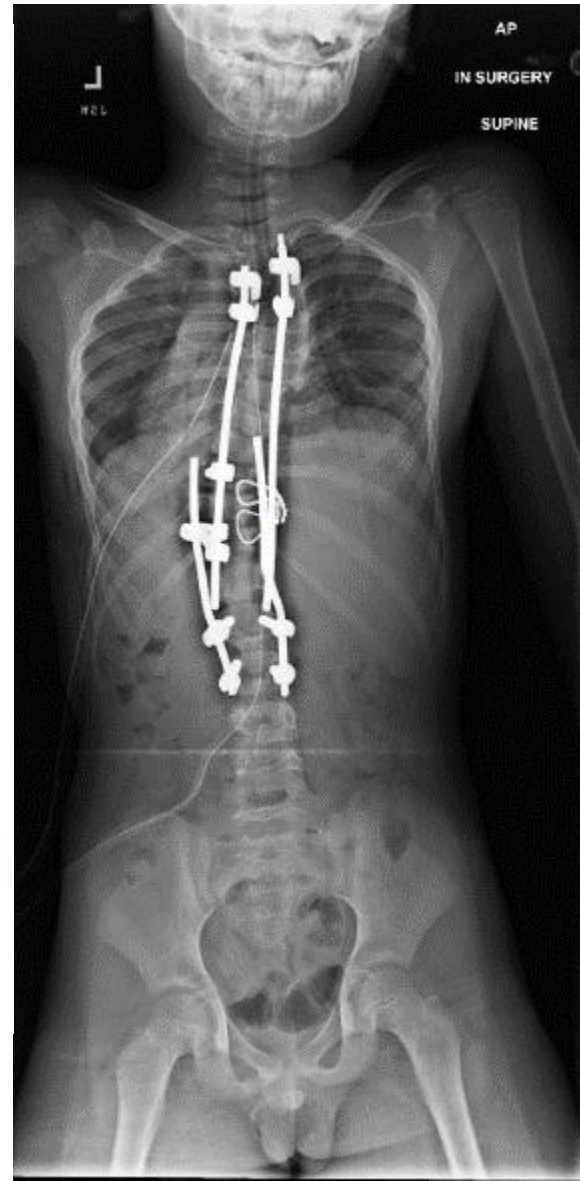
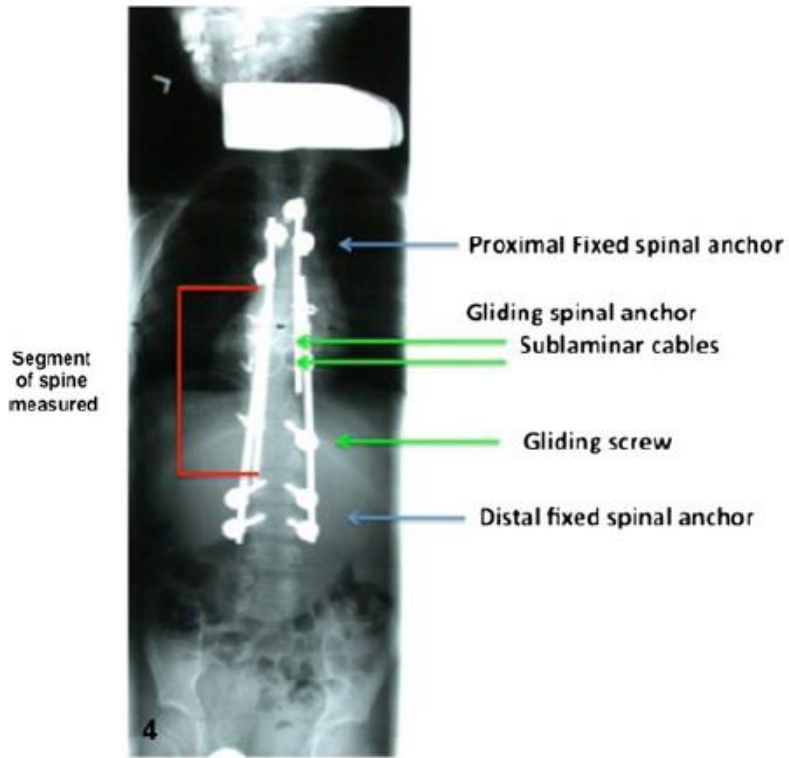
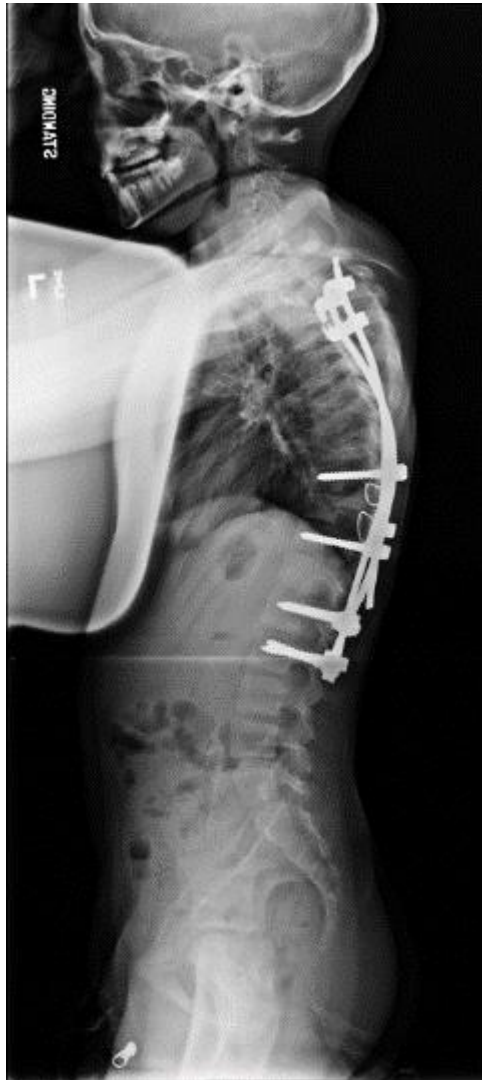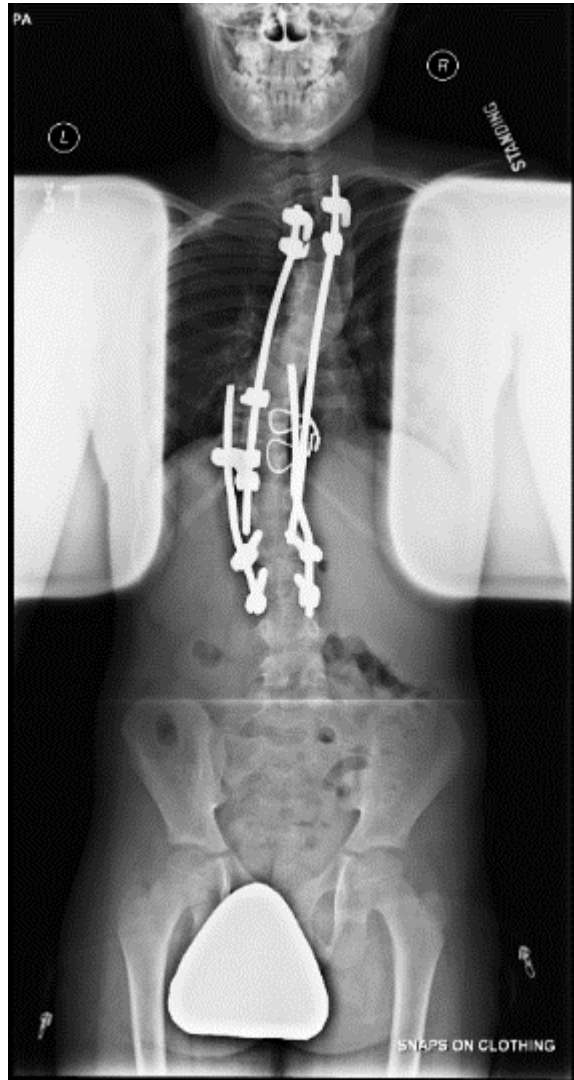
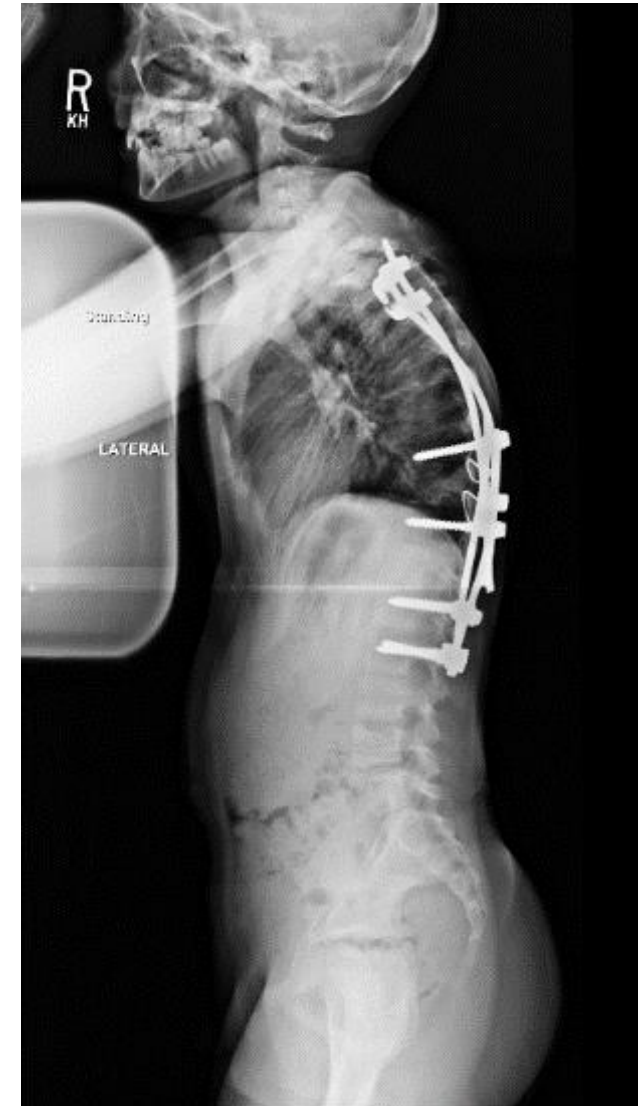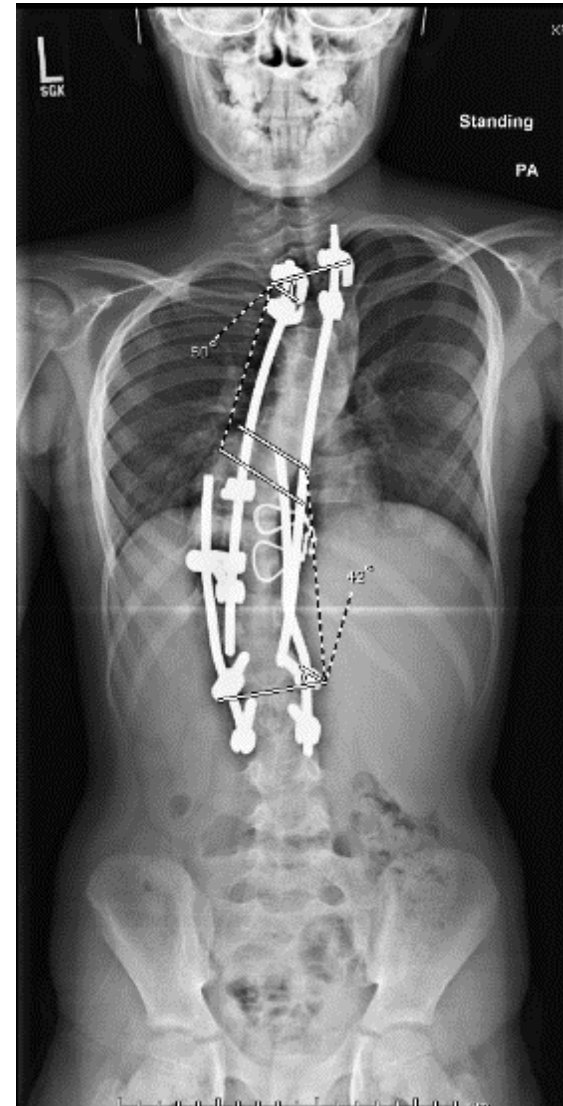


Fig. 4 Classic construct of a modern Luqué trolley consisting of two proximal claws (or four proximal screws) and four distal pedicle screws as fixed anchors are shown. Two intercalated sublaminar cables are placed across the thoracic curve and one gliding screw at the apex of the lumbar curve.

2 weeks postop –  
20.3 cm



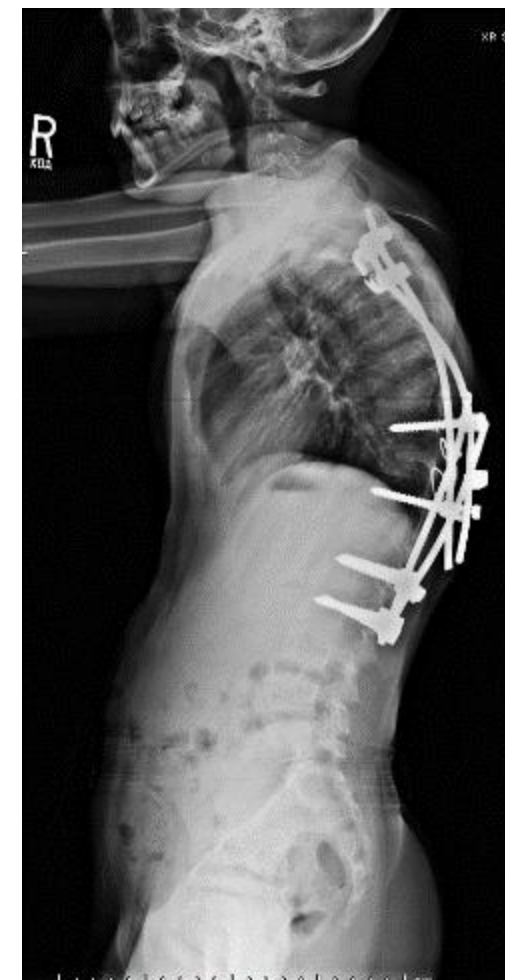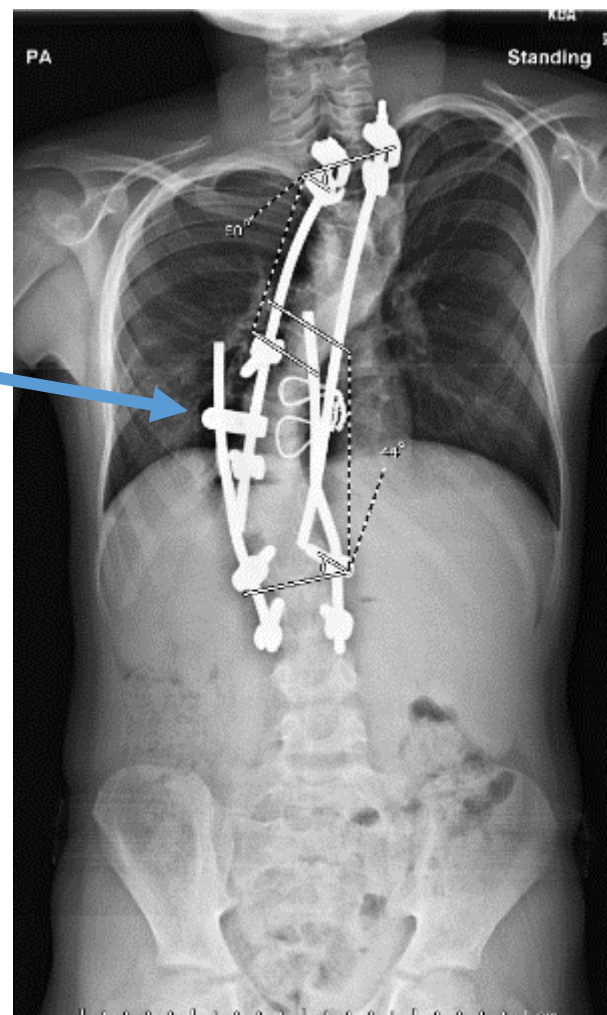
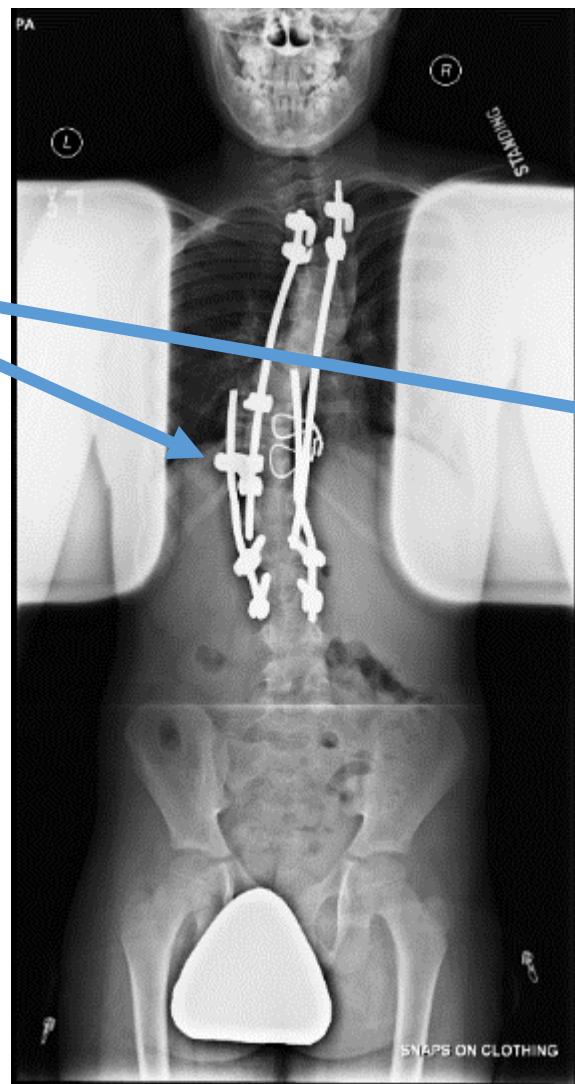
6 weeks postop



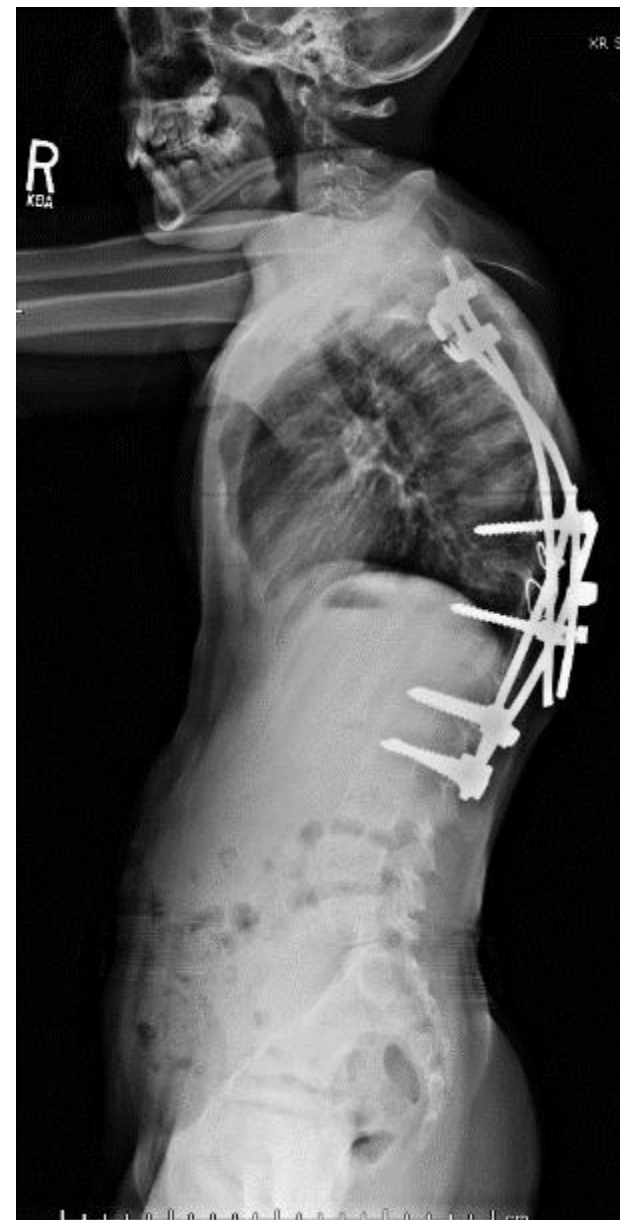


4 months postop –  
Child fell at school,  
sudden increase in  
pain at implants  
over apex

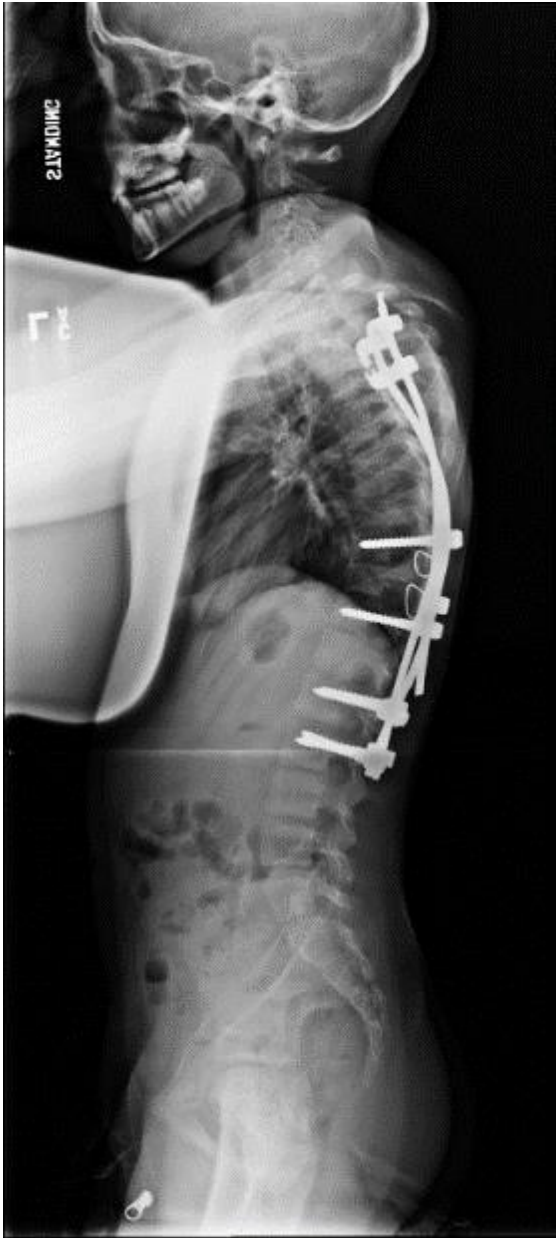Domino rotated



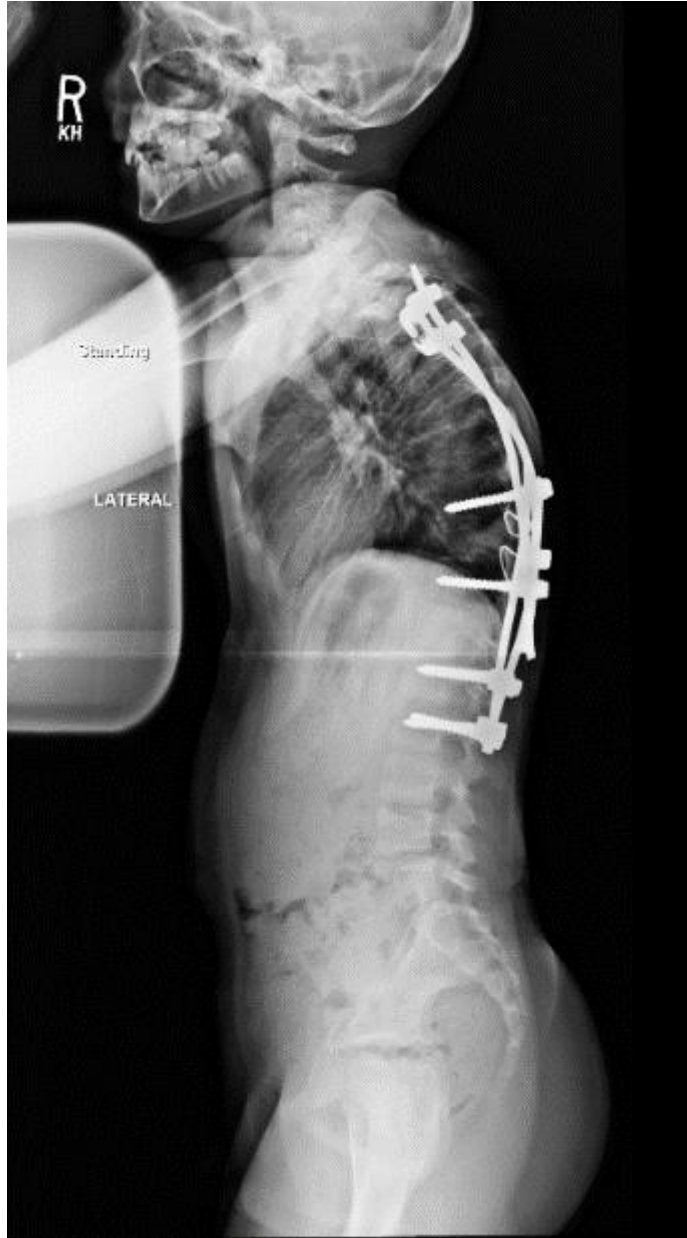Domino rotated



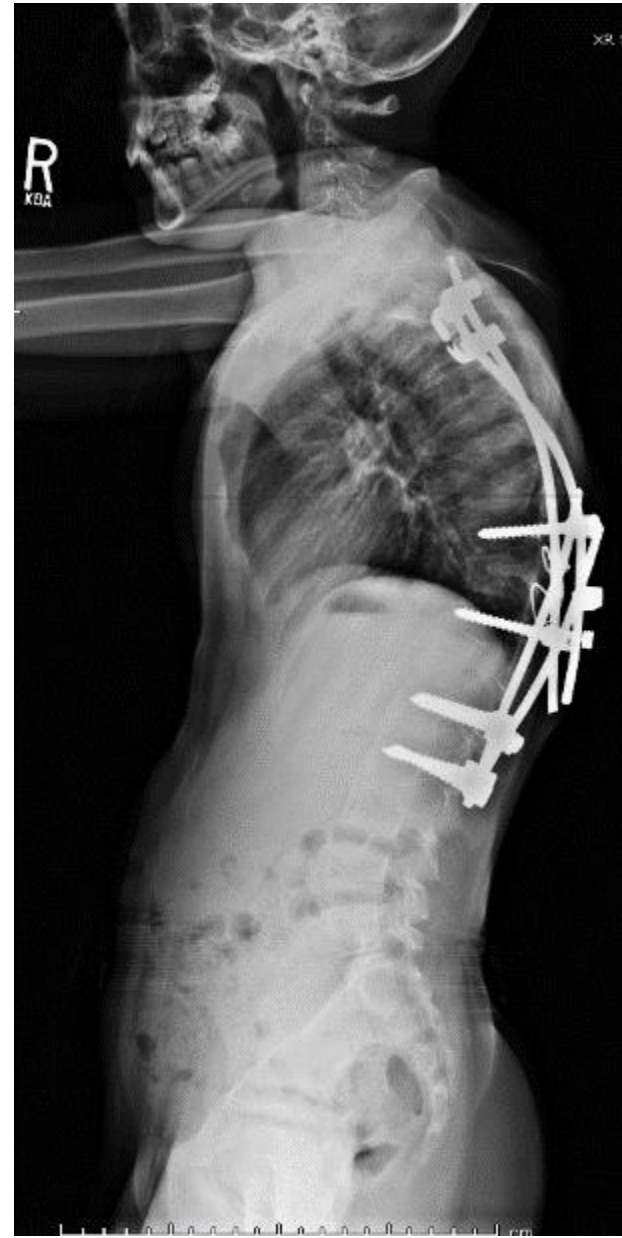
2 weeks



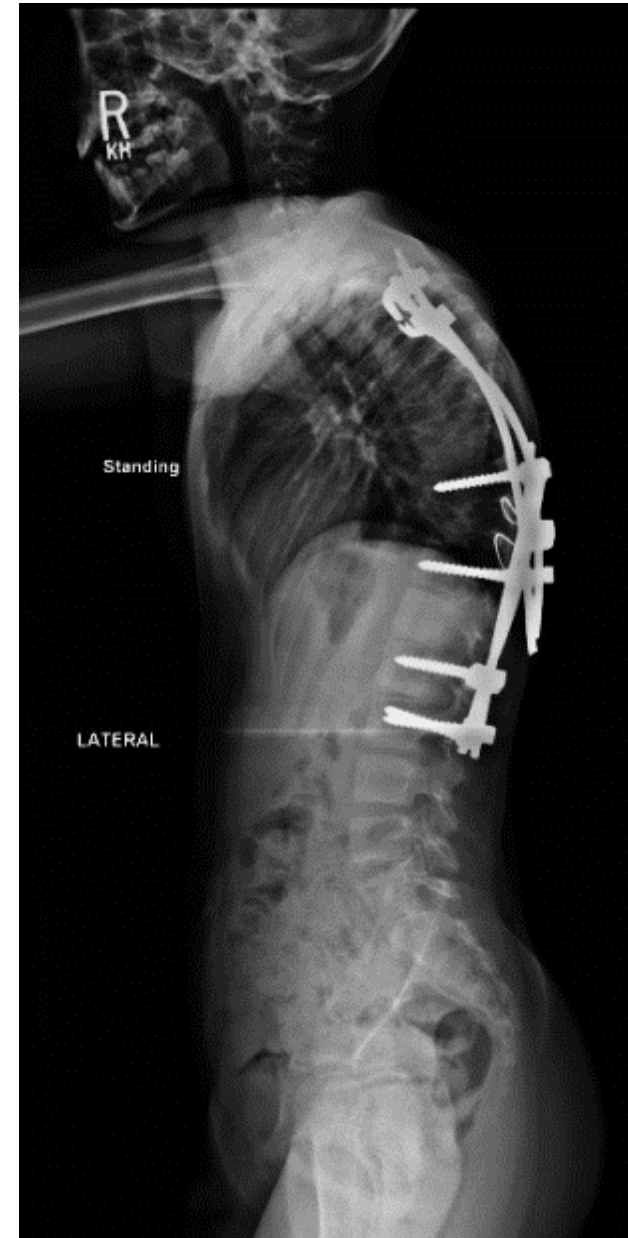
6 weeks



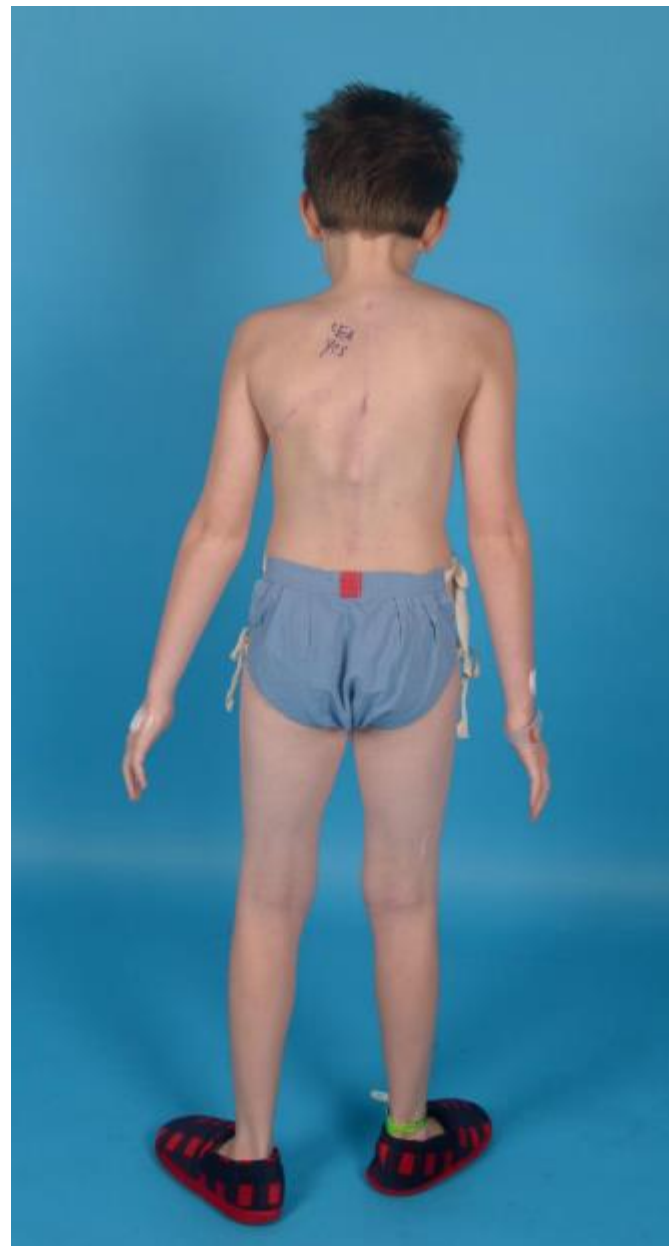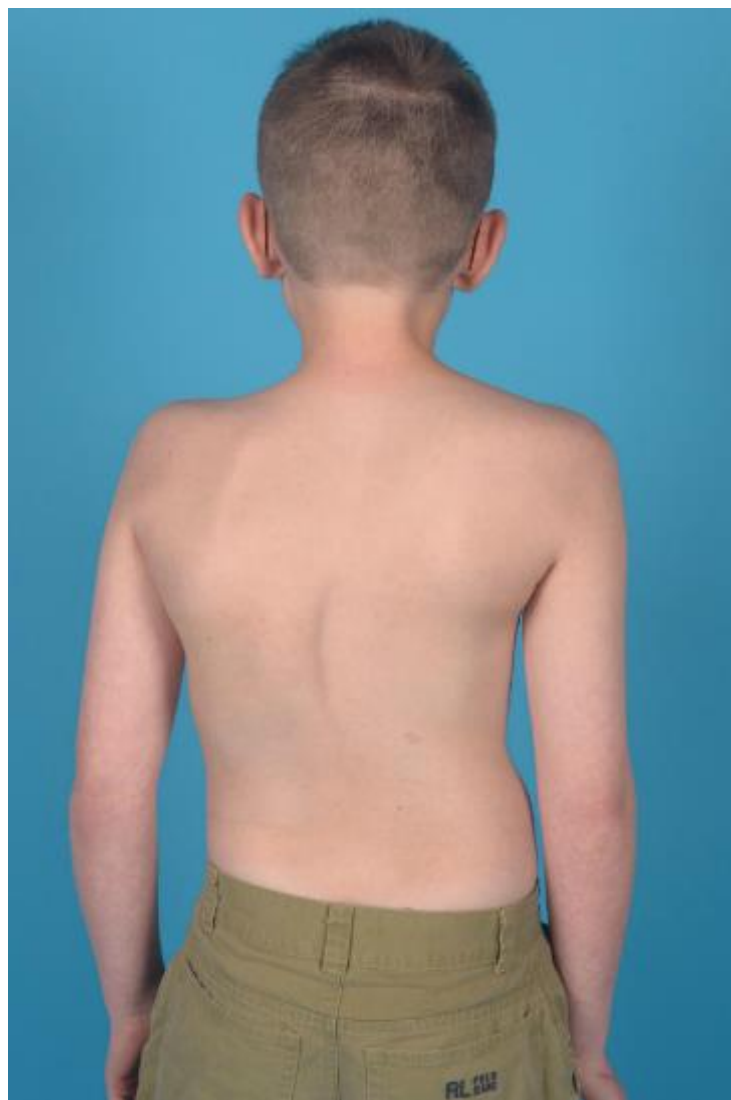4 months

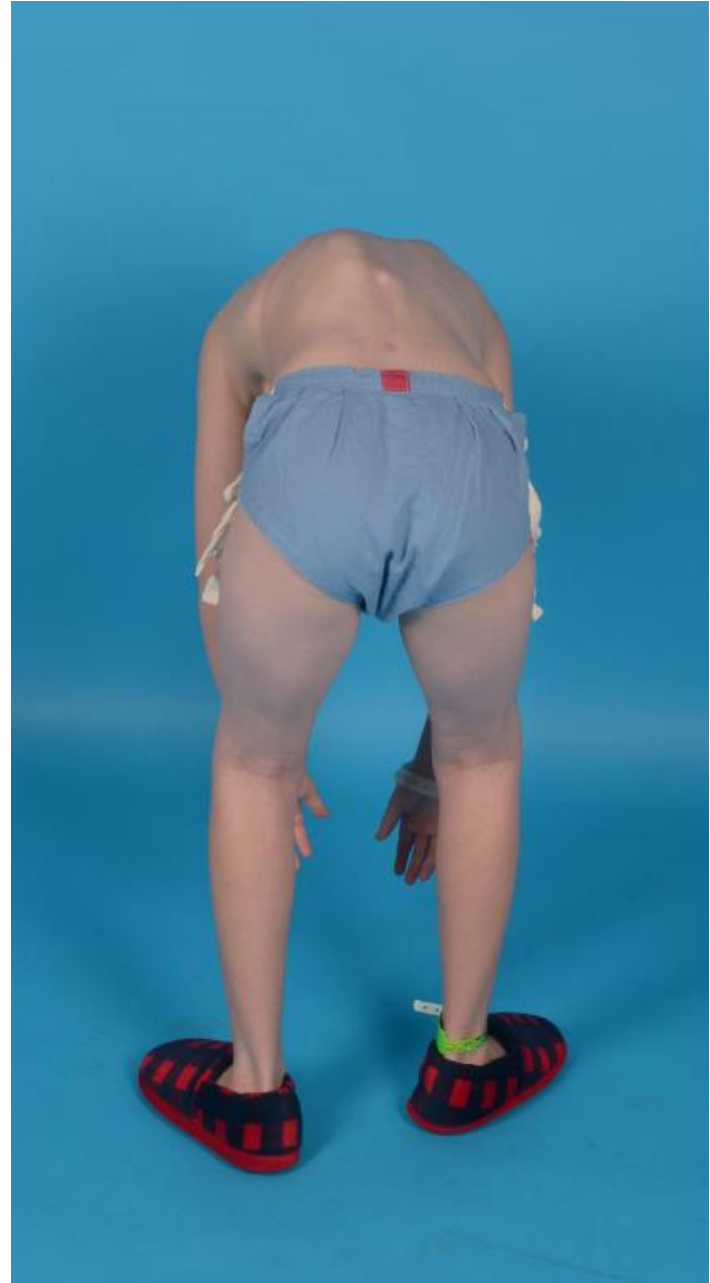
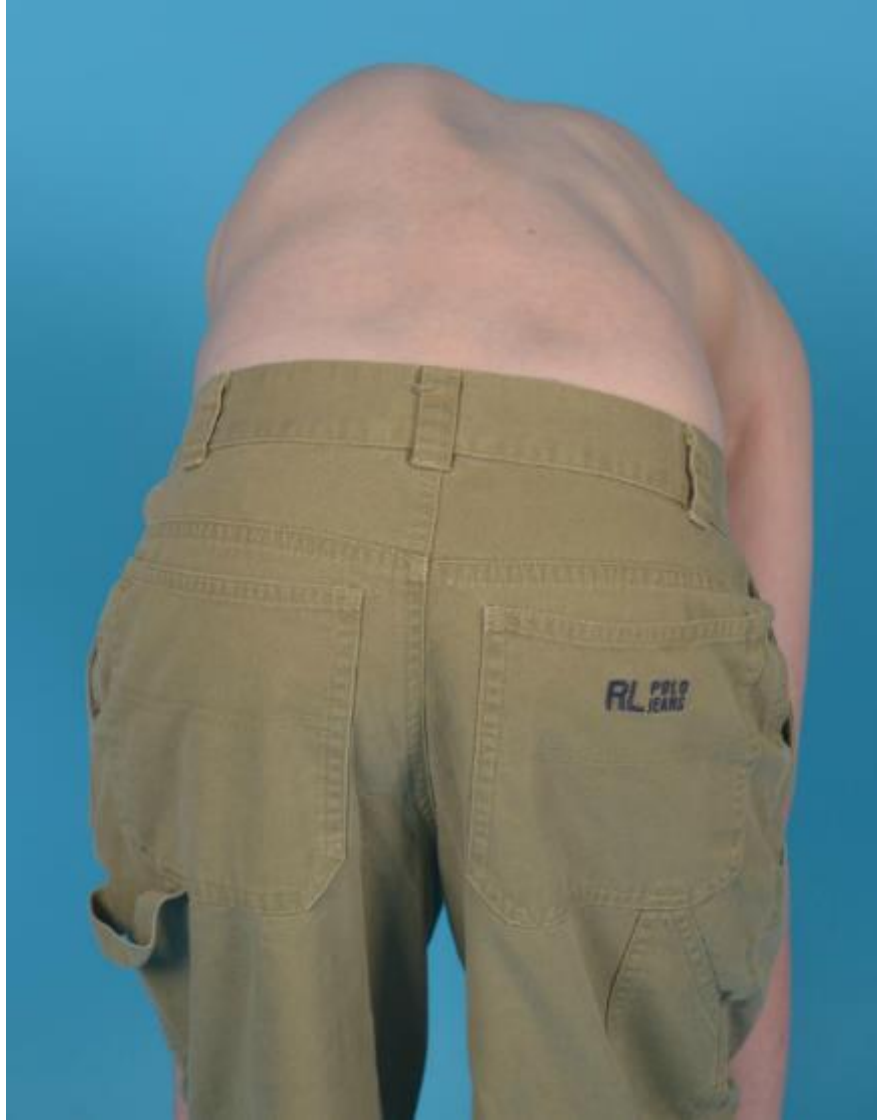
5 months

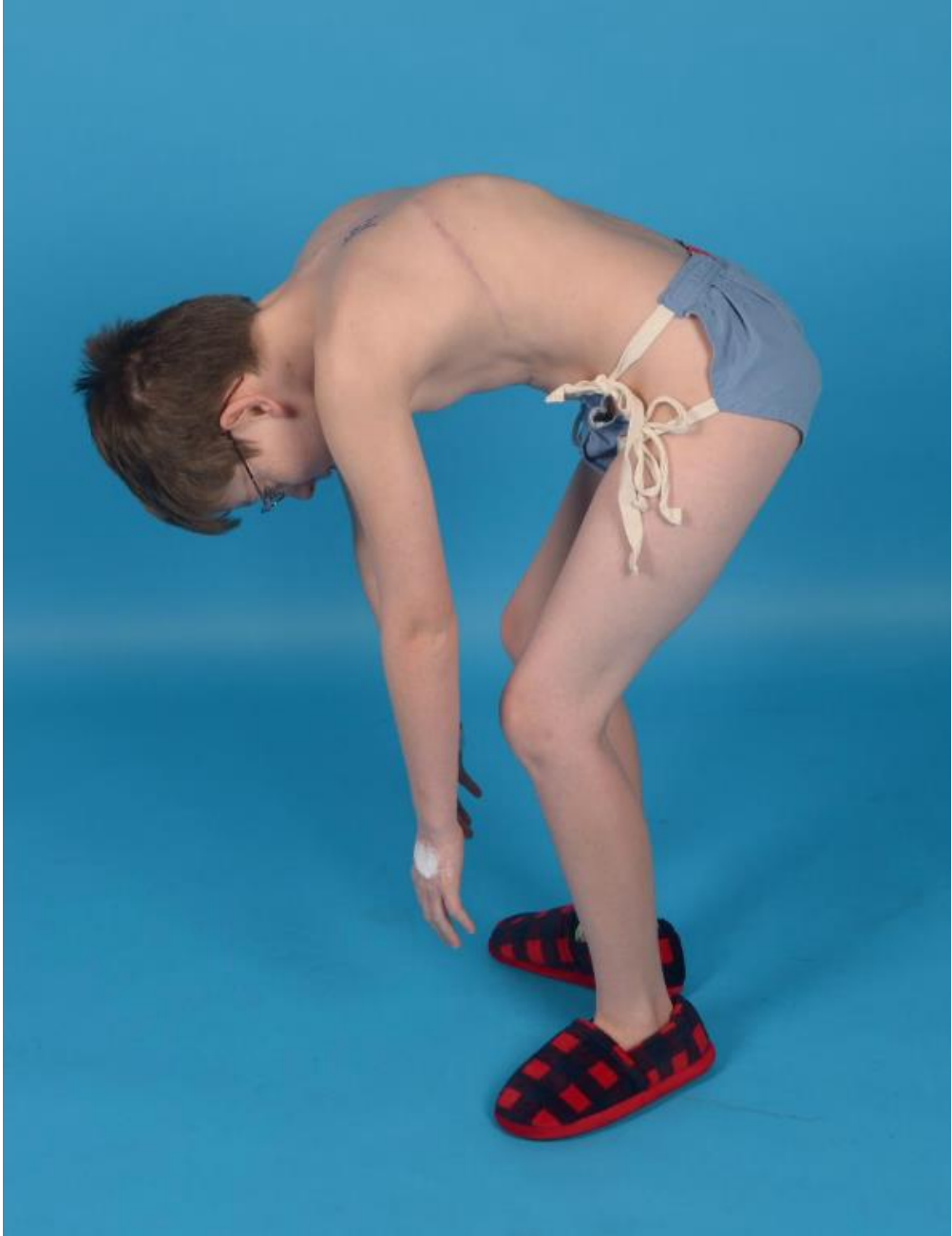
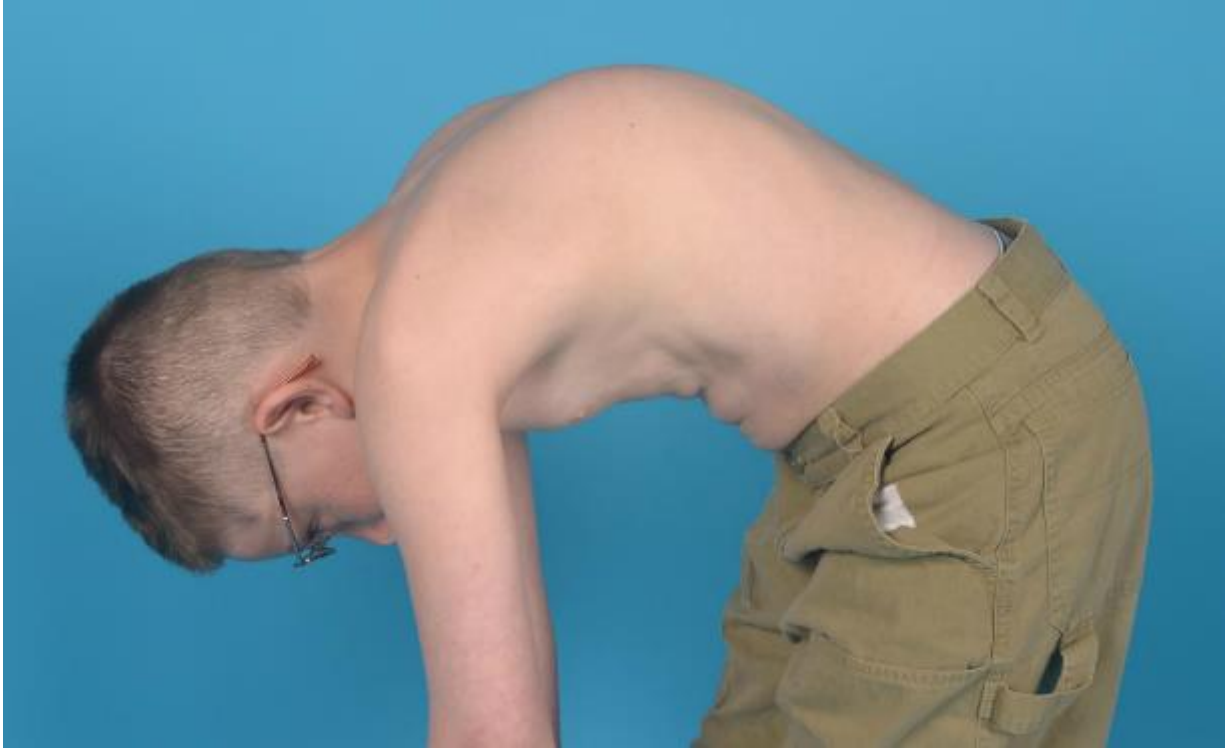


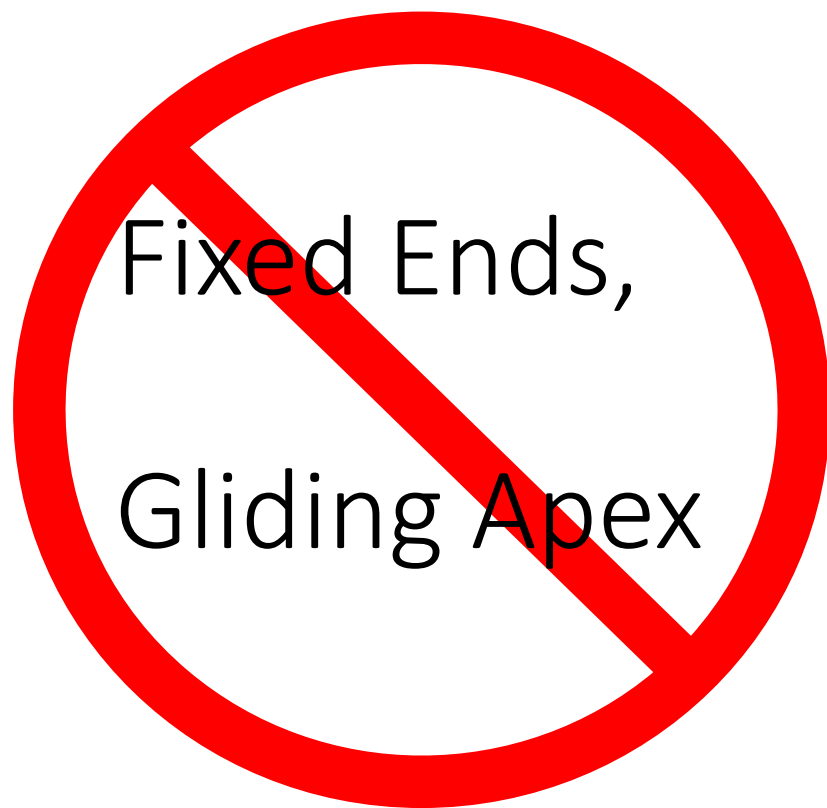

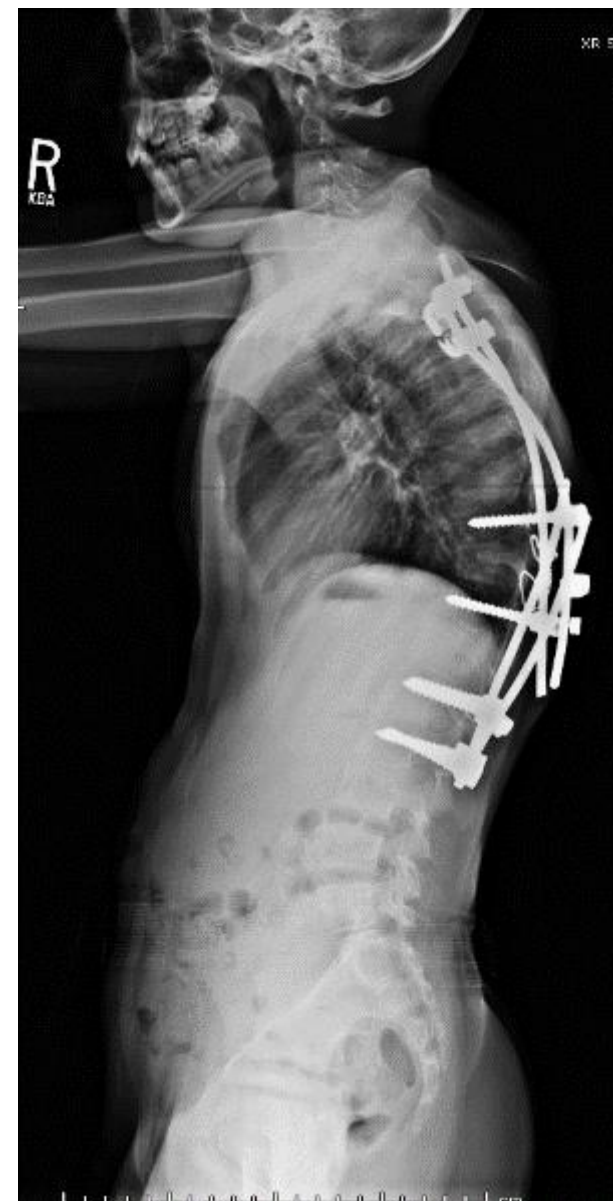
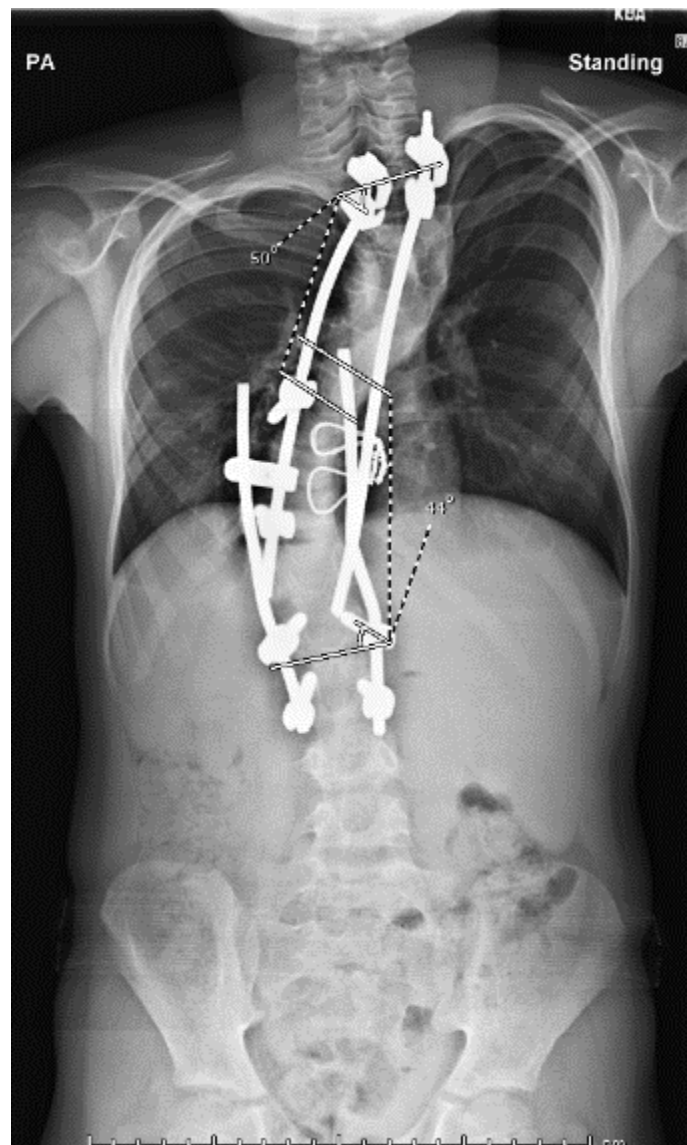





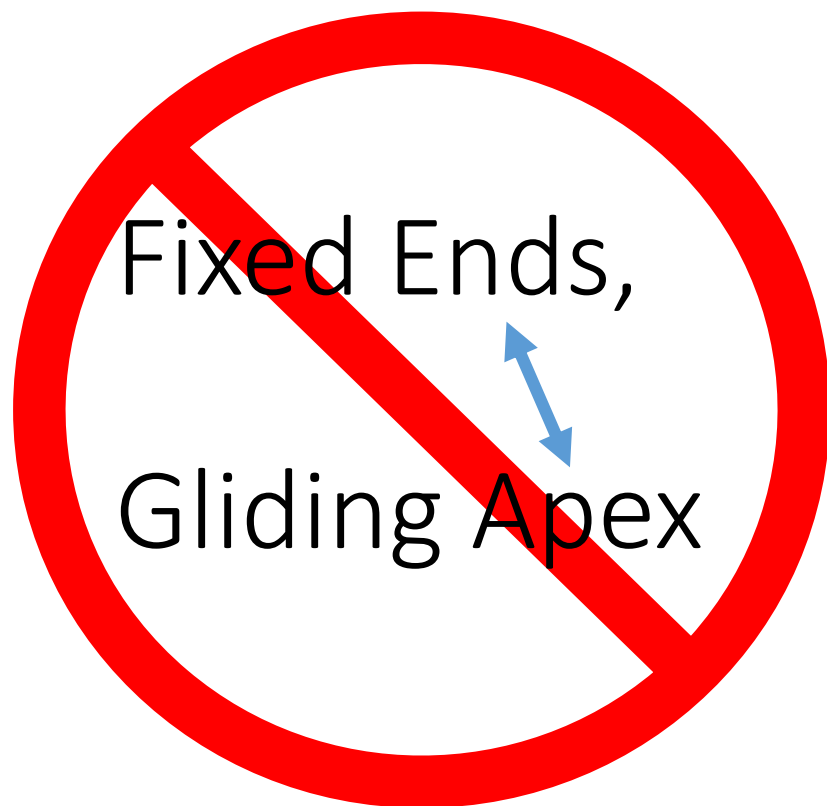
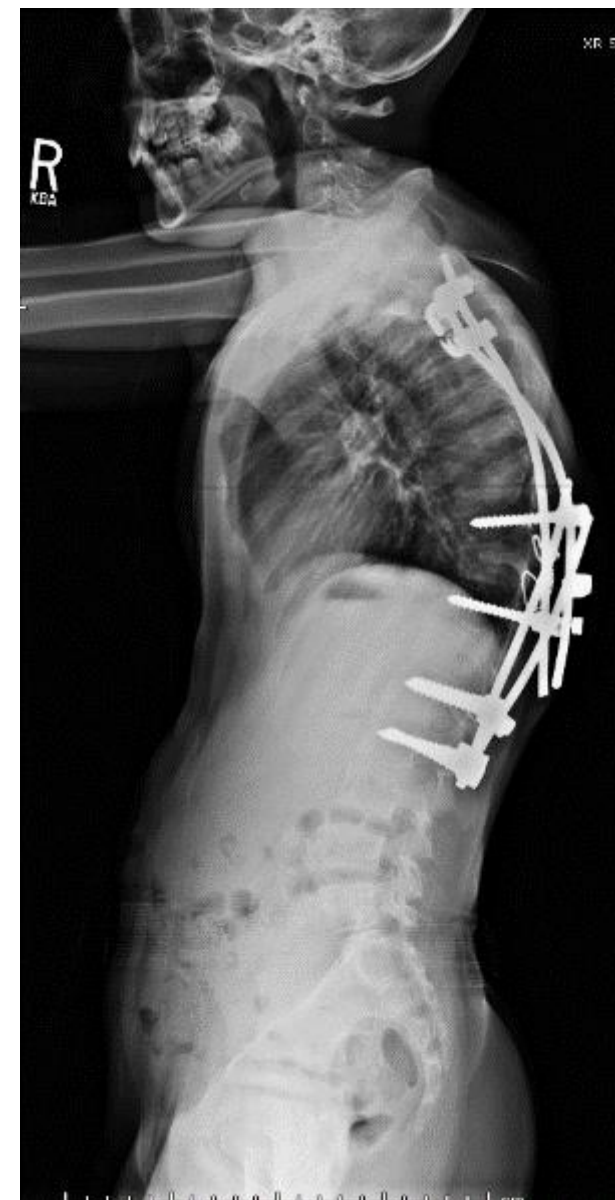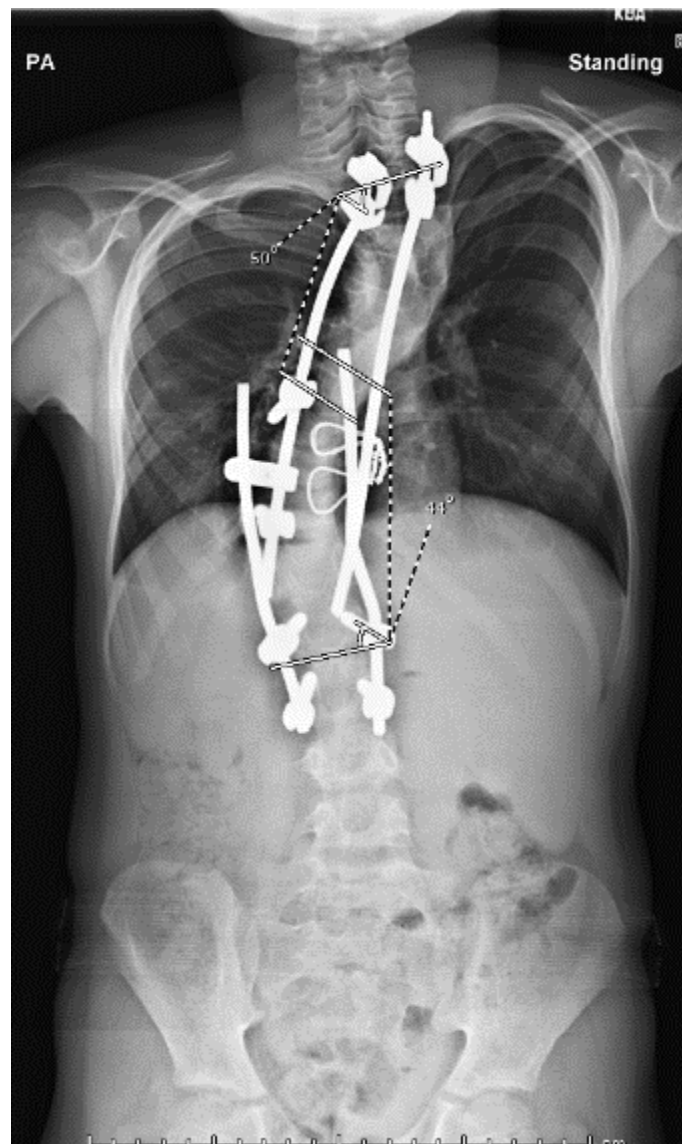


6 months postop –  
20.4cm





6 months postop –  
20.4cm

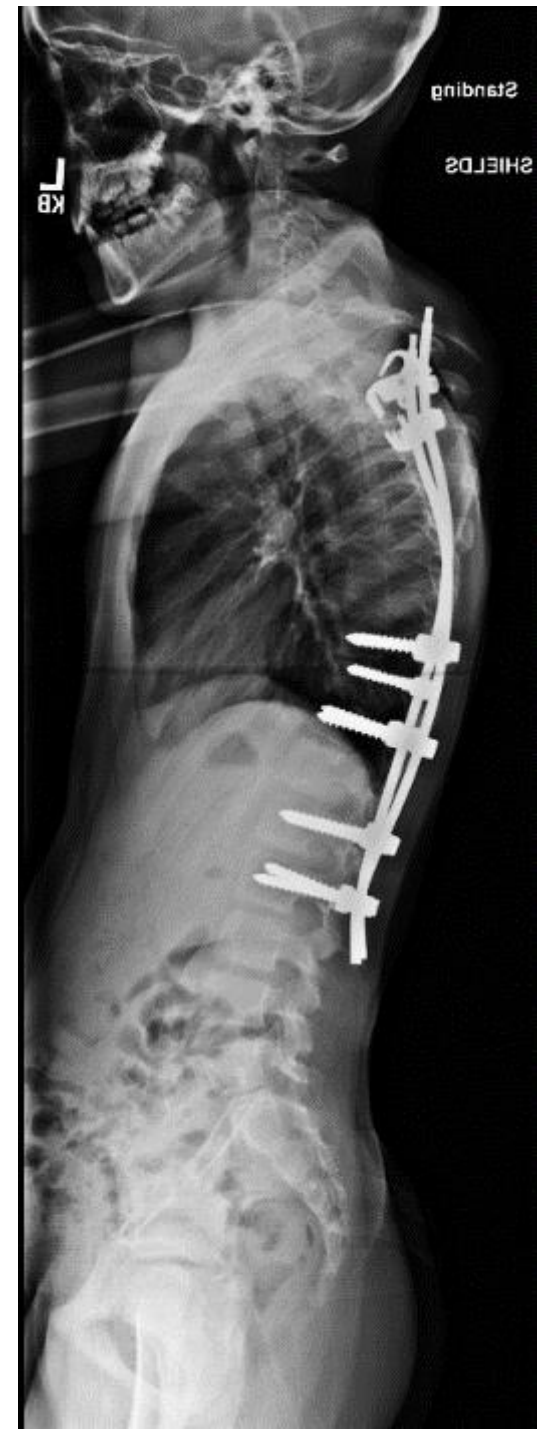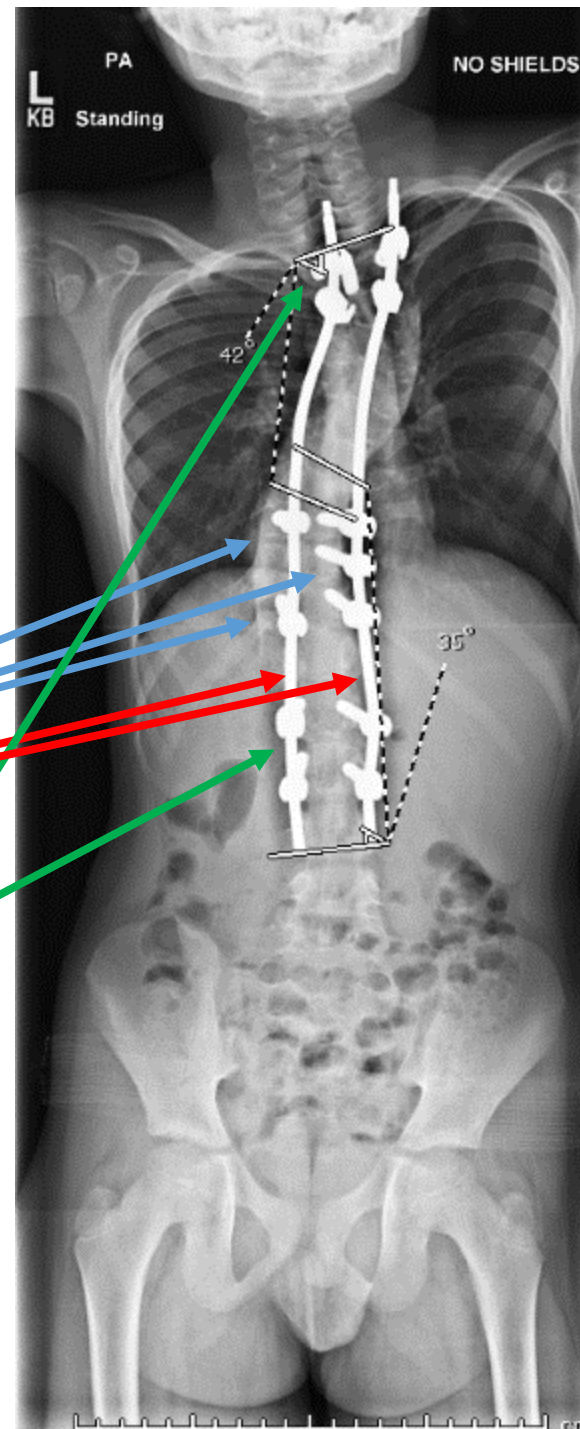


Fixed Apex,  
Gliding Ends

4.5 locked screws

4.5 rods

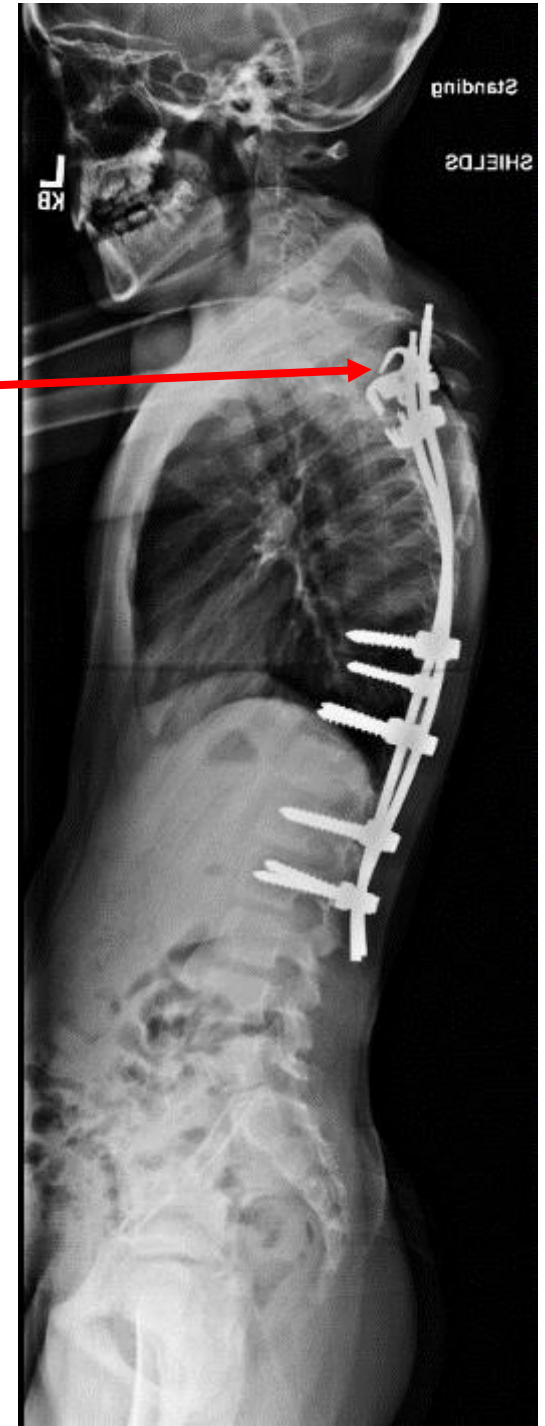
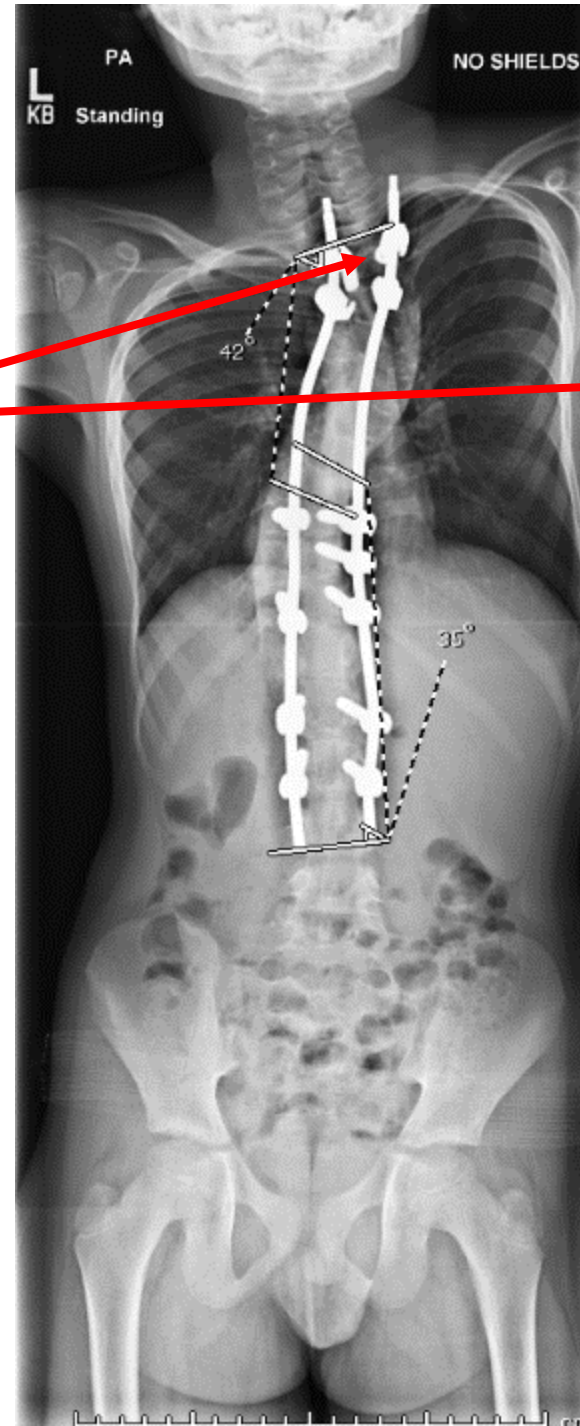
5.5 locked screws and hooks





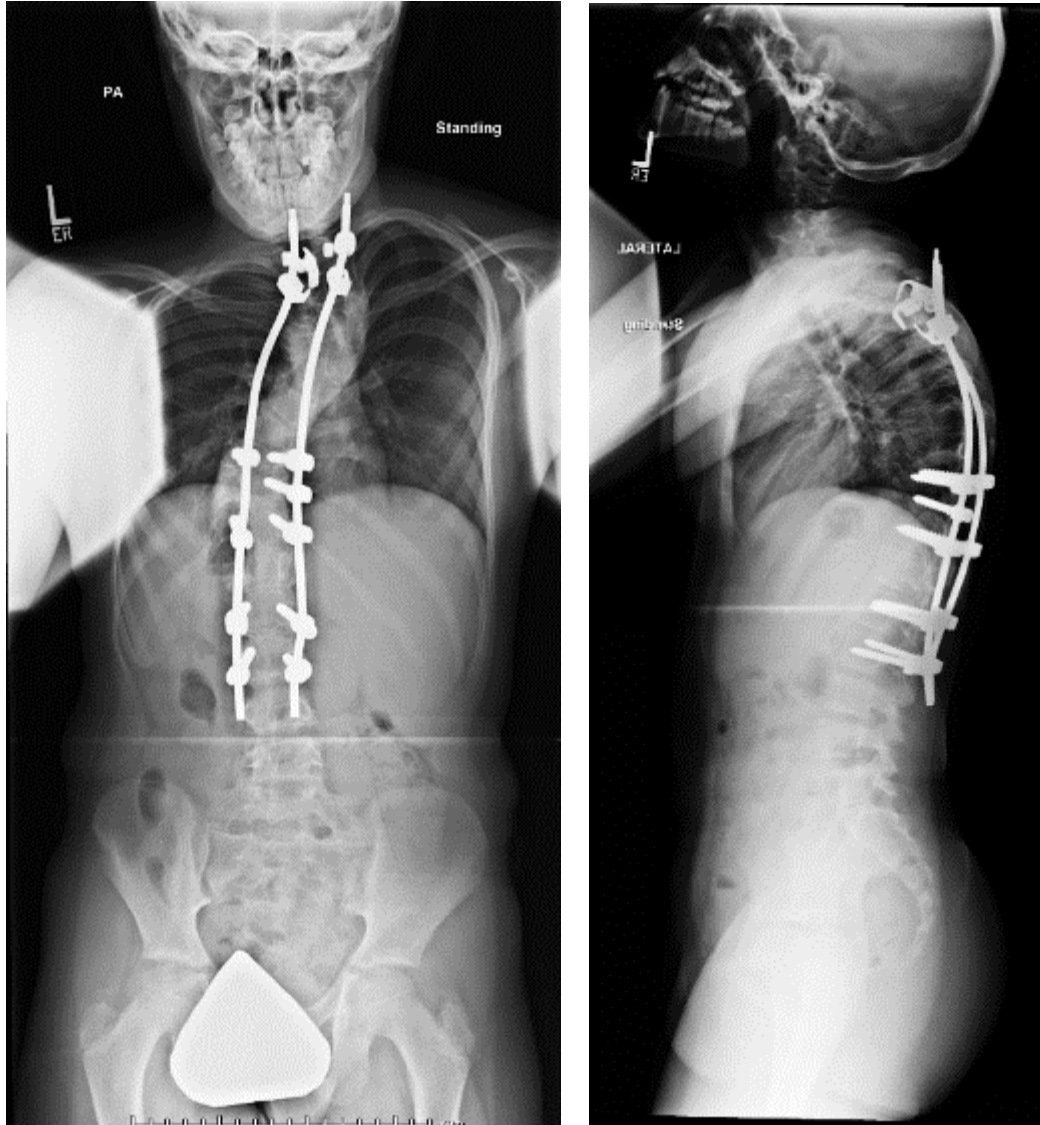
# Early Failure

- Noted within first 6 weeks



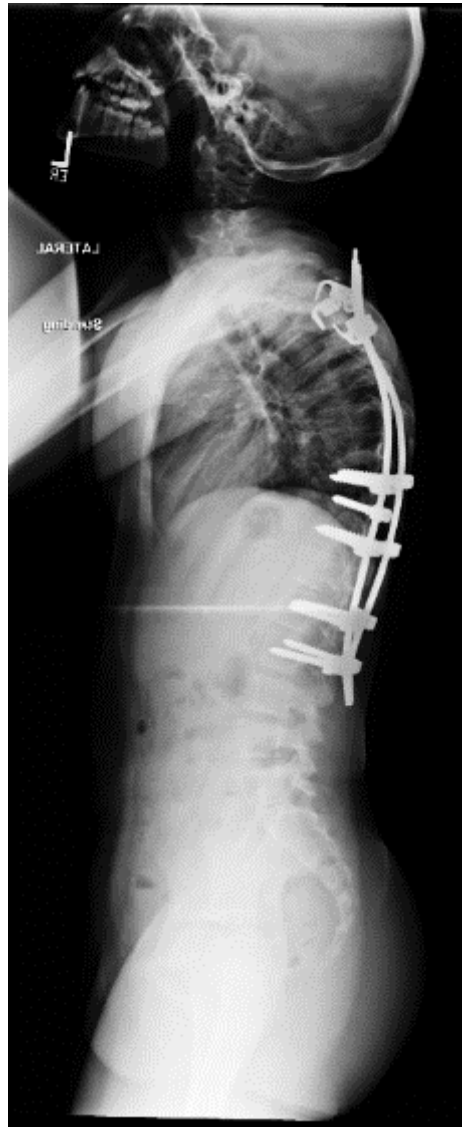
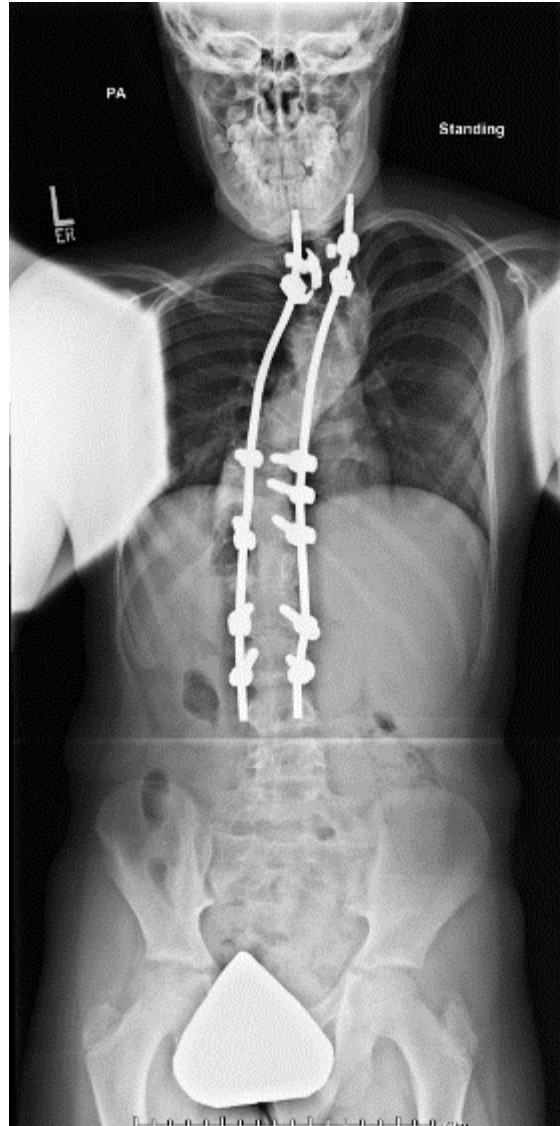


Stayed asymptomatic for some time....  
26 months post conversion

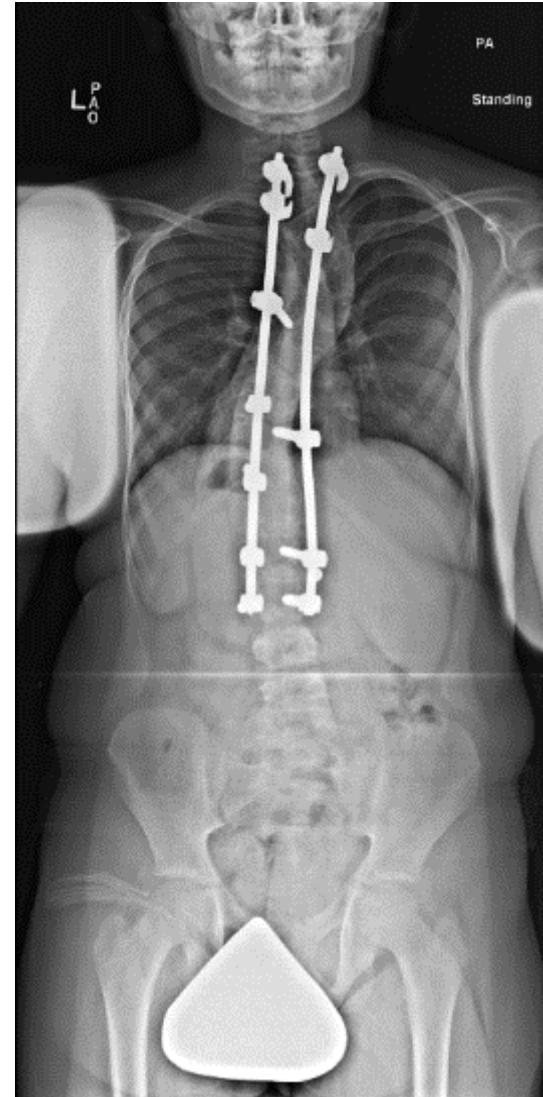


- Child dealing with other health problems limiting activity
- Diagnosed with Multiple Sclerosis in interim

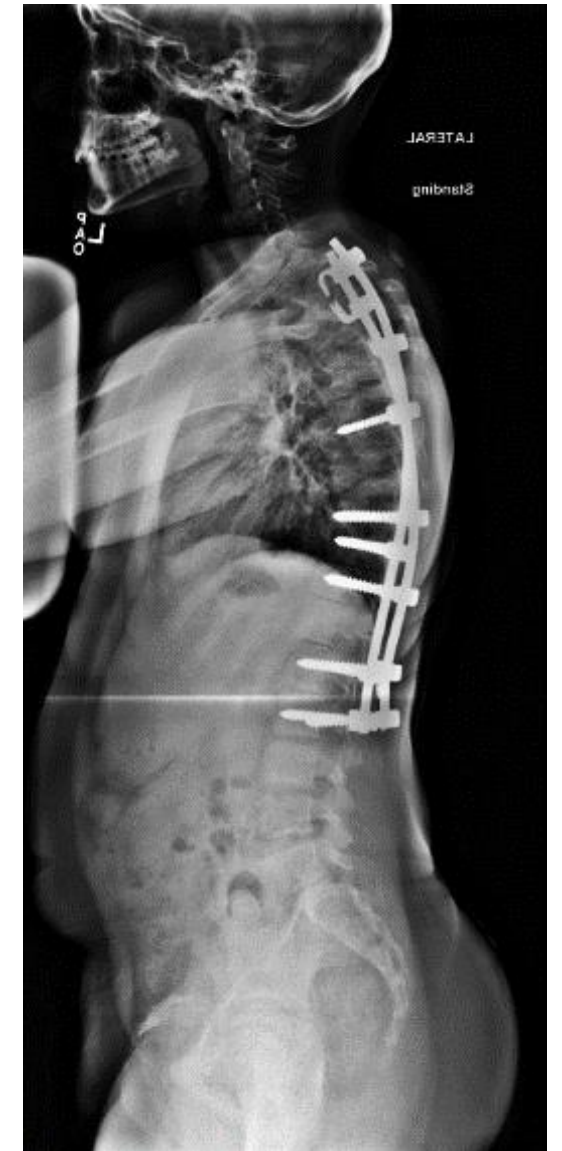Stayed asymptomatic for some time....  
26 months post



At conversion... noted to have  
“significant fibrosis and metallosis  
everywhere, not just at gliding screws”



3 years post  
original 20.4 cm



- Seen at 1 year postop
- Age 14+3
- Asymptomatic
- “well balanced clinically: balanced shoulders, waist and pelvis”
- “Excellent result”
- Triradiate open, and this

