

Osteotomies / VCR for EOS Cases

Michael Ruf

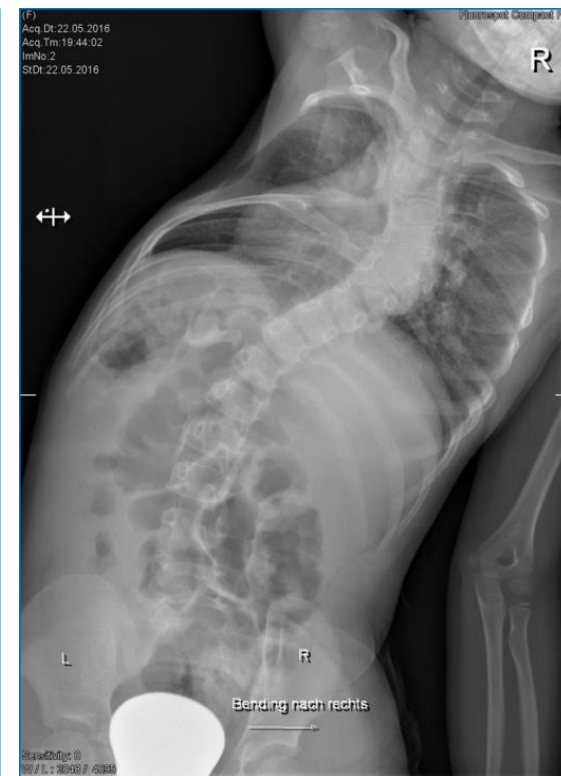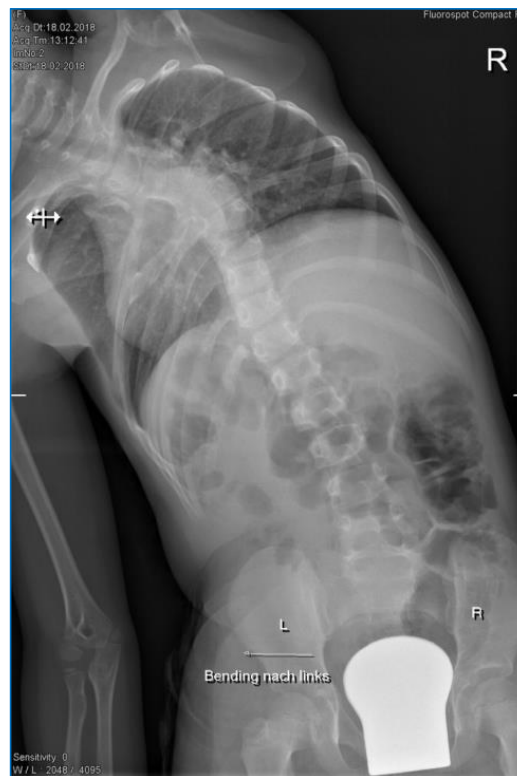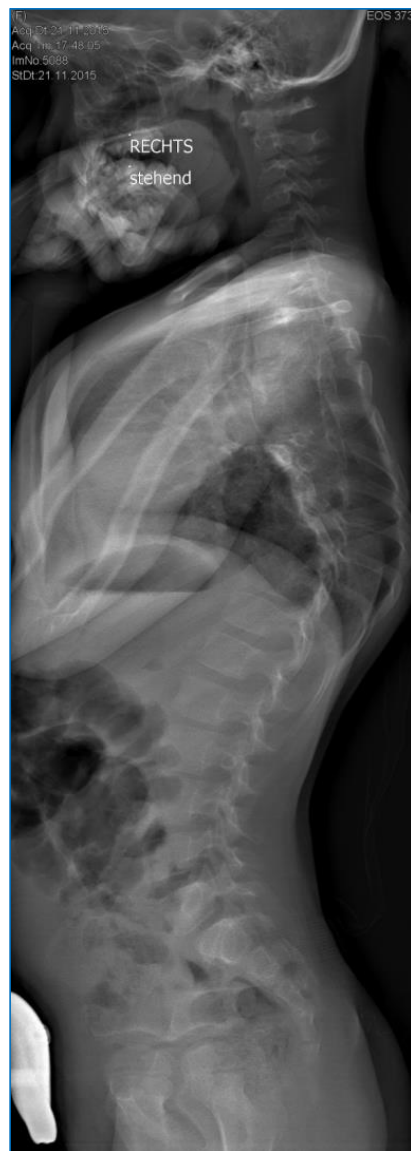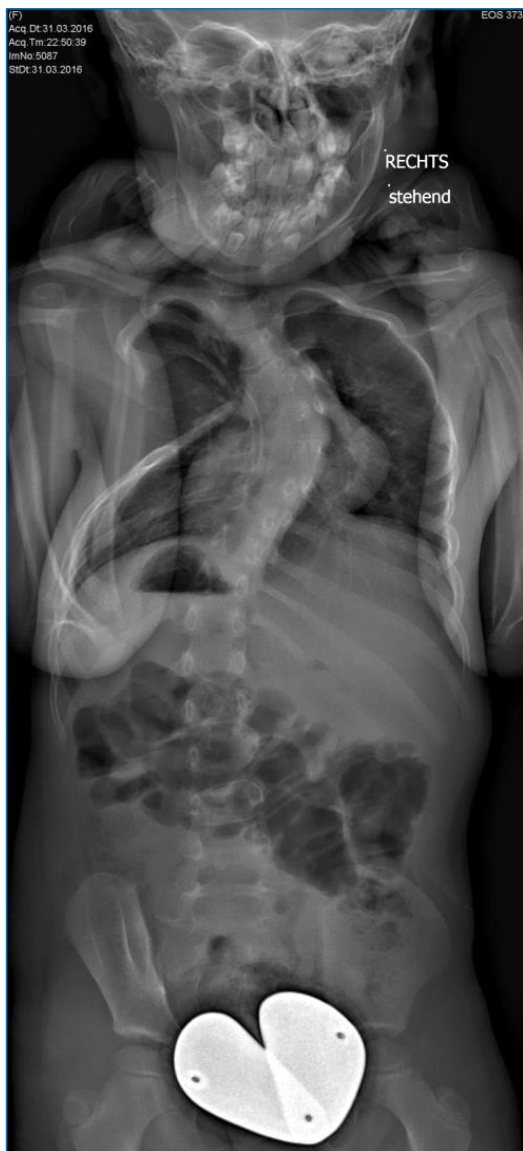Center for Spine Surgery, Orthopedics, and Traumatology,
SRH Klinikum Karlsbad-Langensteinbach
Karlsbad, Germany

Disclosures

Lectures (honorarium/ travel expenses)

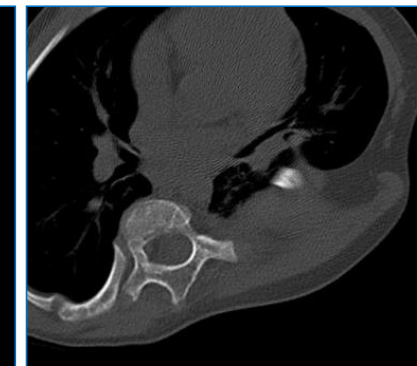
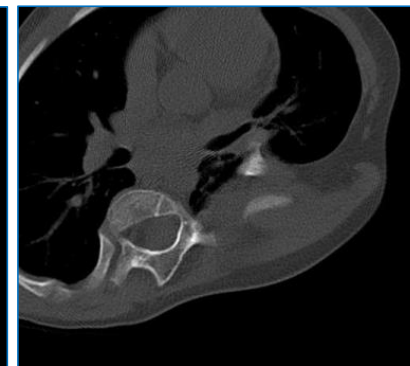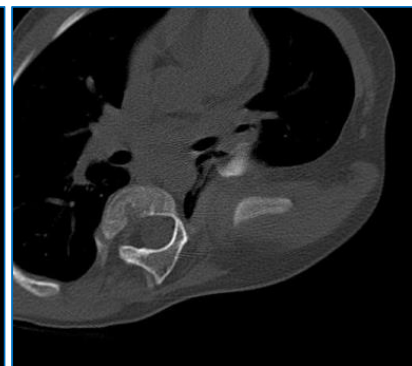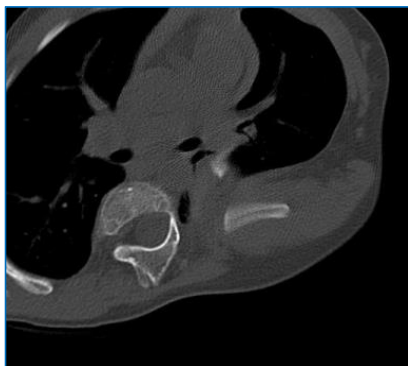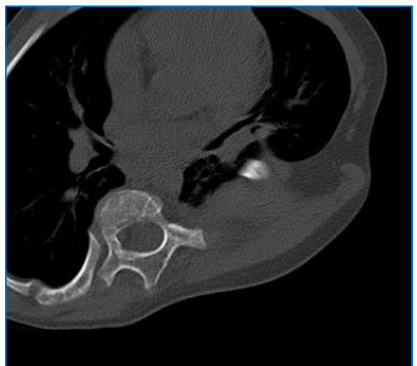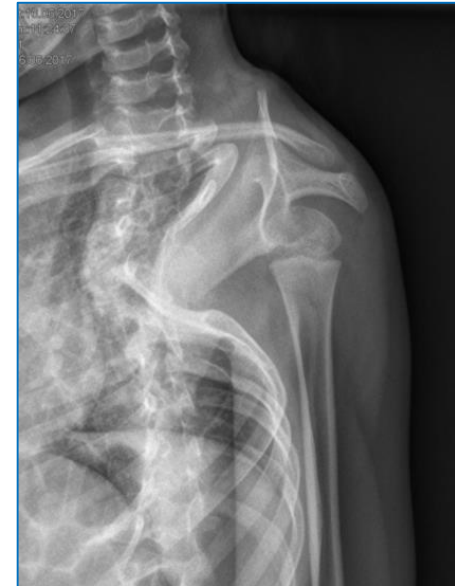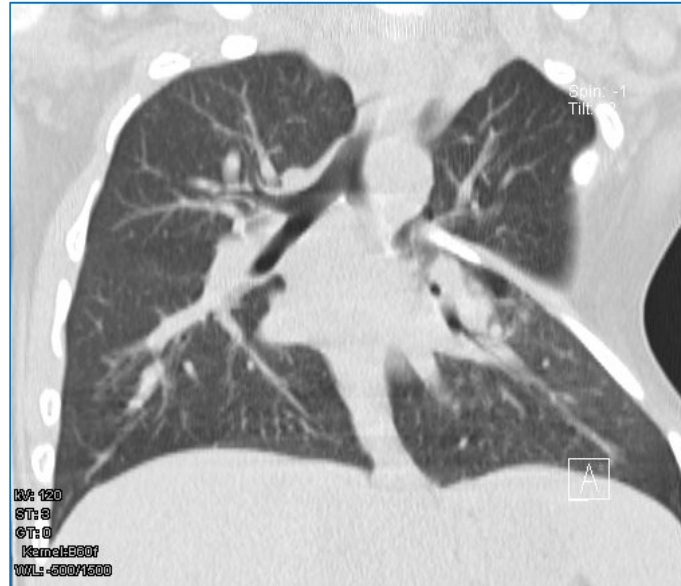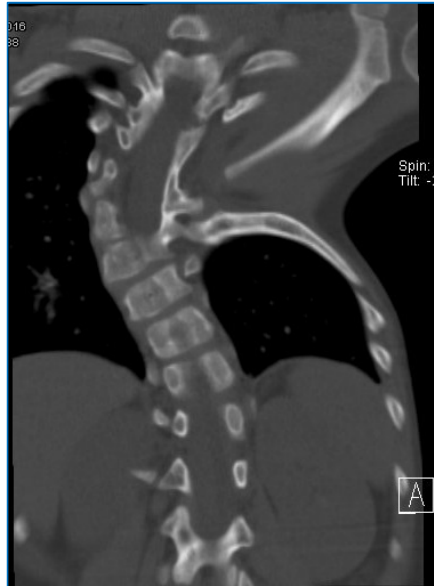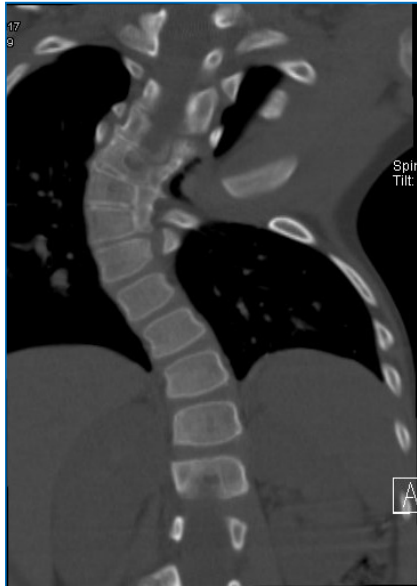DePuy, K2M, Medtronic



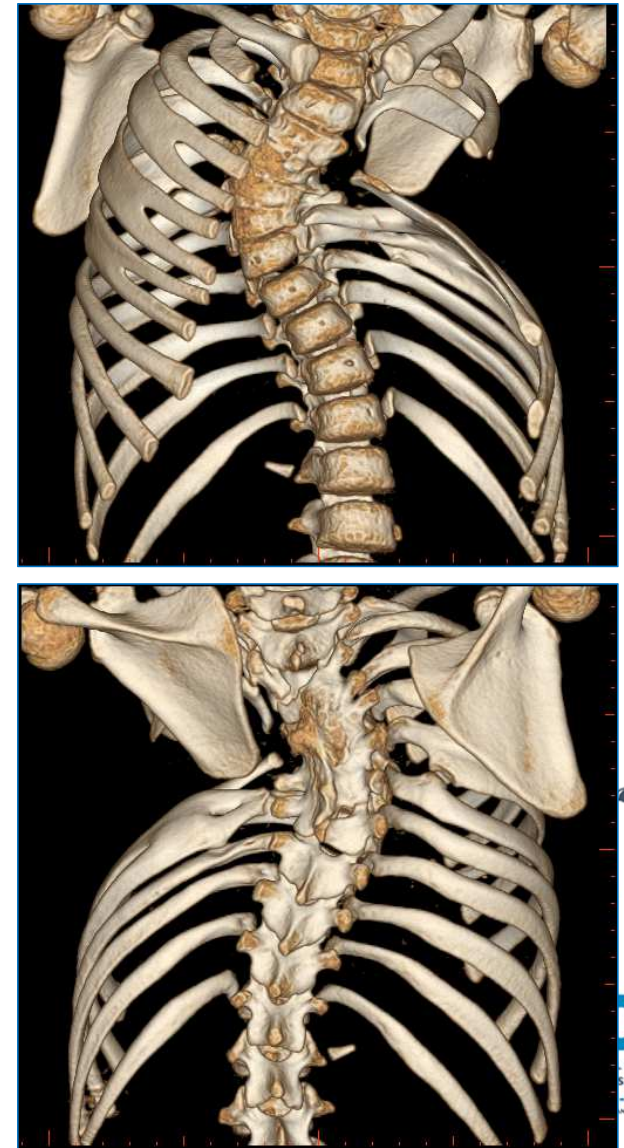
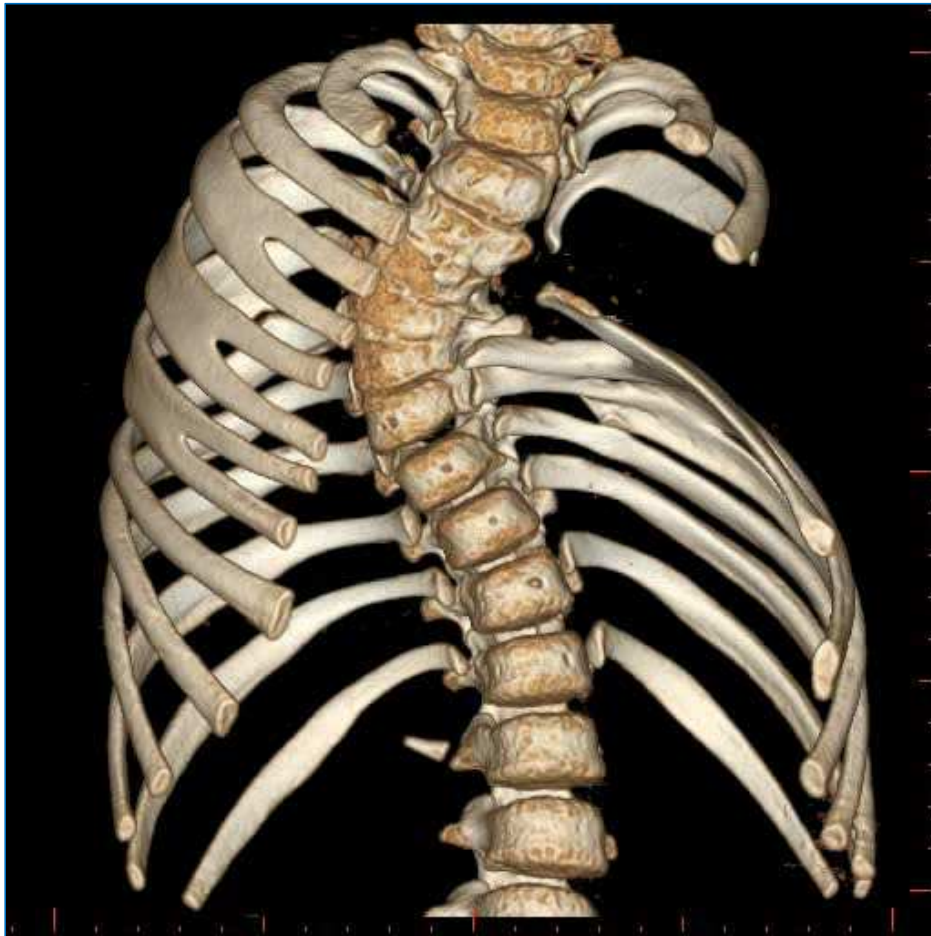

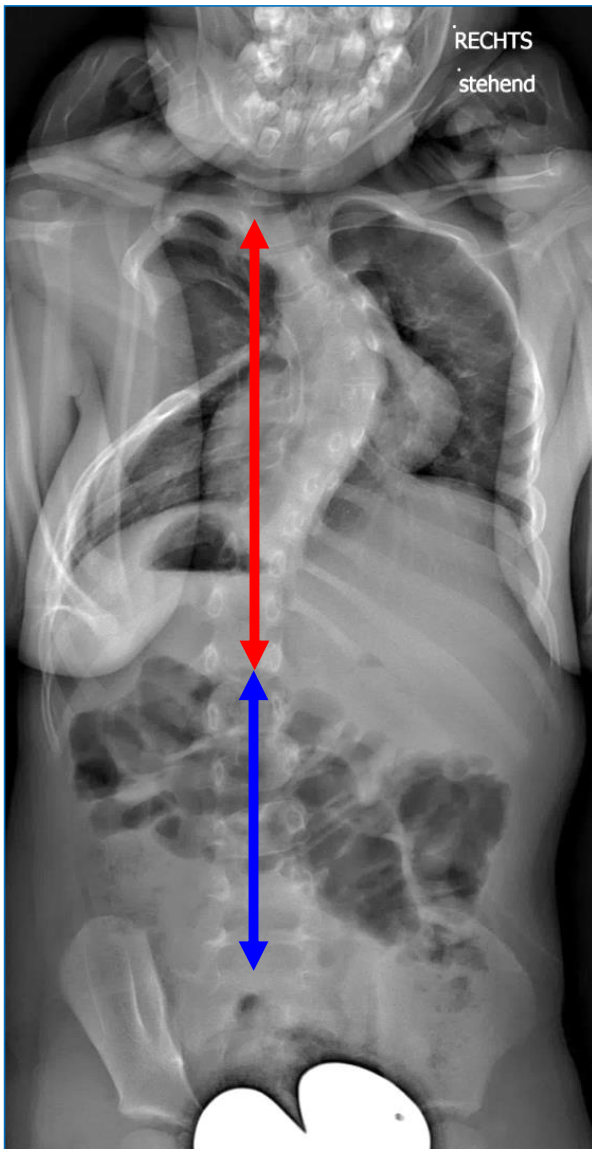
Q.Z., f., 6 y.
EOS
frequent pulmonary infections

Congenital scoliosis (wedge vertebrae T5+6, bar formation T3 -T7)
Multiple rib cage deformities (rib head 4 left compresses the left main bronchus!)
Scapula is fixed to the spinal column



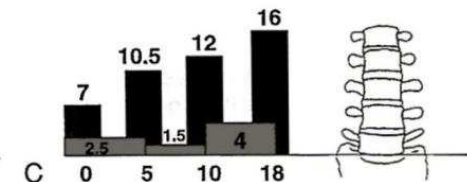
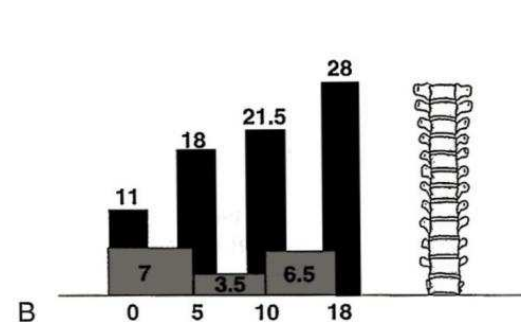
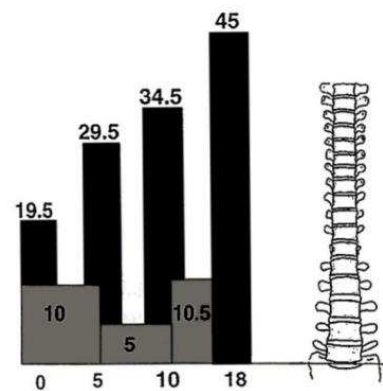
Congenital scoliosis (wedge vertebrae T5+6, bar formation T3 -T7)
Multiple rib cage deformities (rib head 4 left compresses the left main bronchus!), scapula is fixed to the spinal column





Problems

- Small chest cavity
- Compression of the left main bronchus
- Growth deficit of the thoracic spine
 - ratio length of thoracic spine to length of lumbar spine: 1.5 (physiological ratio 1.75)



DiMeglio A, Bonnel F. Growth of the spine.
In Raimondi AJ (ed). The pediatric spine, principles of
pediatric neurosurgery. Springer-Verlag 1989:39



